

Erythrosis Pigmentosa Mediofacialis (Brocq) and Erythromelanosus Follicularis Faciei et Colli in the Same Patient

LENNART JUHLIN^{1,2} and HANS ALKEMADE¹

Departments of Dermatology, ¹University Hospital Nijmegen, The Netherlands and ²University Hospital, Uppsala, Sweden

Erythrosis pigmentosa peribuccalis (Brocq) (or erythrosis pigmentosa mediofacialis) and erythromelanosus follicularis faciei et colli, have been regarded as different disorders, mainly because the first occurs on the mediofacial area and is common in women and the second mostly occurs pre-auricularly in men. Both conditions show histological signs of abnormal follicular keratinization with teleangiectasia and round cell infiltrate. An increase in the level of melanin has been seen in some patients. We describe here a woman in whom lesions started in the middle of the face and later became evident in the pre-auricular area. This suggests that the two conditions are in fact the same disease. As a neutral term for this not uncommon disorder we propose erythrosis pigmentosa faciei et colli.

(Accepted July 20, 1998.)

Acta Derm Venereol (Stockh) 1999; 79: 65–66.

Lennart Juhlin, Department of Dermatology, University Hospital, S-751 85 Uppsala, Sweden.

Brocq described patients in whom the skin on the chin and around the mouth and nose was dry and had a *café au lait* to yellow-brown pigmentation (1, 2). The intensity of the colour could vary quickly during the day and almost disappear under the diascop, suggesting it was influenced by vascular reactions. Similar findings, mostly in women, were reported by Juster as erythrose pigmentaire faciale (3).

Ormsby & Ebert (4) reported 3 middle-aged women with the disorder and pointed out that it could clearly be distinguished from chloasma by its decreased colour under the diascop. Sézary et al. preferred to call it *dermatose pigmentée médio-faciale* since it could extend up to the forehead (5). Cohen reviewed the literature on 11 female patients and discussed the differential diagnosis for one woman with the disorder (6). Tritsch & Greither reported a woman with lesions on the chin and forehead and a man with only forehead lesions. They called the condition *erythrosis pigmentata faciei* (7). Glaze described women in whom the middle as well as the sides of the face and neck were affected, whereas the nasolabial folds were free of lesions (8). Red-brown, dry pre-auricular lesions on the cheeks with teleangiectatic vessels and fine scaling of follicular papules were also seen in young Japanese men by Kitamura et al. (9). They coined the term *erythromelanosus follicularis faciei* and considered it to be different from erythrosis pigmentosa mediofacialis since it occurred in men, at different sites and the colour did not change over the weeks. Mischima & Rudner later studied Caucasian male patients with this disorder (10). They also observed melanin hyperpigmentation of keratinocytes and suggested an autonomic nerve dysfunction. Since then the disorder has been further documented in 4 male teenagers and 1 young woman (11–13).

We report here on a 34-year-old woman who presented with lesions typically localized as in erythrosis pigmentosa mediofacialis (Brocq). She later also developed follicular lesions and teleangiectatic vessels in the pre-auricular area of both cheeks and on the neck as seen in erythromelanosus follicularis faciei. This indicates that the two conditions can occur in the same patient and therefore probably are the same disease.

CASE REPORT

The patient was referred to the clinic with a red-brown discoloration in the middle of the face present for the last 3 years. It was slowly increasing in size and a year ago similar lesions had appeared on both cheeks. Treatment with oral minocycline, metronidazole, topical tretinoin, antibiotics, triamcinolone, ketoconazole and sulphur creams were without effect. The colour could change markedly during the day. She often had attacks of pain in the abdomen and at the same time the lesions flared up mainly in the middle of the face. She had been investigated for the symptoms and ulcerative colitis had been suspected 14 years previously. She had also had some temporary periods with erythrocytes in the urine. The patient was in good general health except from periodic pain over the gall bladder area. She was taking no medication except a contraceptive (ethynyl oestradiol-levonorgestrel).

Skin changes

The brownish regions were sharply demarcated on the forehead, the peri-nasal and the peri-oral region as well as on the chin (Fig. 1A). The skin here was dry and rough. There was a fine, mainly follicular, scaling and teleangiectatic vessels. The pre-auricular area of both cheeks had a brownish serpiginated erythema with sharp borders. Teleangiectatic vessels were most evident at the margins. Within the erythematous zone there were areas of normal looking skin (Fig. 1B). Wood's light did not accentuate the white skin between the lesions. Diascopy decreased the colour, leaving a slight yellowish pigmentation.

Histological examination

The epidermis showed slight hyperkeratosis, acanthosis and perinuclear vacuolization accentuated around the wide openings of the pilosebaceous follicles (Fig. 2). There was no parakeratosis. The granular layer was broad, with 2–4 cell layers. Melanin-containing keratinocytes were most marked in the basal layer. The follicular openings were enlarged and contained lamellar horny debris and often demodex. There was a round cell infiltrate around the follicles in the dermis and the teleangiectatic vessels. The follicular duct showed spongiosis. There were some melanin-containing macrophages.

DISCUSSION

The main cosmetic problem for the patient was the sharp difference between the pale and coloured areas on the cheeks. The white area looked like naevus anemicus, but friction and heat application induced erythema, and naevus anemicus has never been reported on both sides of the face. It is of interest in this context to note that one of Ormsby & Ebert's patients had been diagnosed as vitiligo by a competent dermatologist (4).

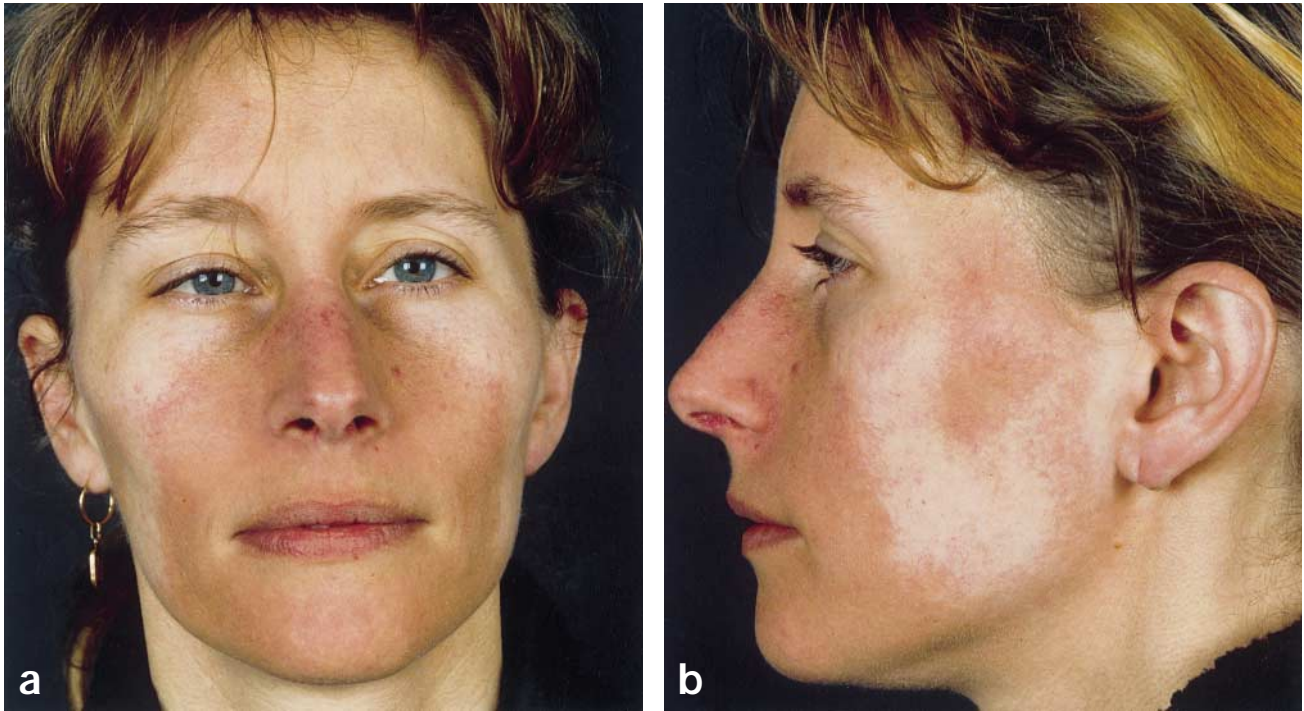

Fig. 1. Patient presenting with (A) initial medifacial lesions and (B) pre-auricular lesions on the cheek and lesions on the neck, with a pale and well-demarcated normal appearing skin behind the midline lesion.

Hyperkeratosis follicularis has been reported on the arms in some patients, suggesting a keratinization abnormality. Rubbing or use of cosmetics and medical creams have been implicated as well as a relationship to rosacea. Demodex folliculorum was suggested by Ayres Jr, who in discussing of Ormsby & Ebert's publication, mentioned that he had used an ointment similar to that used in scabies which led to the disappearance of both demodex and the eruption (4). Our patient had demodex folliculorum and was treated repeatedly with metronidazole but without effect, which gives no support for the demodex aetiology. Abdominal pain has been noted in many of the patients in the early reports. In our patient the midline lesions were more marked when she felt pain on the right side of the abdomen.

Since the medifacial and the pre-auricular types show the same clinical and histopathological picture, both can fluctuate in intensity and occur in both men and women, we believe it is one and the same condition. The level of melanin granules in

the keratinocytes has been reported to be increased whereas others found no significant increase (see 5 for ref). As a neutral term for the condition we suggest erythrosis pigmentosa faciei et colli.

REFERENCES

1. Brocq L. L'erythro pigmentée péri-buccale. Presse Med 1923; 13: 728–729.
2. Brocq L. Discussion. Bull Soc Franc Derm Syph 1927; 34: 339–340.
3. Juster ME. Recherches sur l'étiologie et le traitement de l'erythro pigmentaire faciale (erythro pigmentaire péri-buccale de Brocq). Bull Soc Franc Derm Syph 1927; 34: 337–339.
4. Ormsby OS, Ebert L. Erythro pigmentaire péri-buccale de Brocq. Arch Dermatol Syphil 1931; 23: 429–436.
5. Sézary A, Civatte A, Lefèvre P, Combe E. Dermatose pigmentée médio-faciale (forme extensive de la dermatose pigmentée péri-buccale de Brocq). Bull Soc Franc Derm Syph 1983; 38: 770–773.
6. Cohen EL. Erythrosis pigmentosa peribuccalis. Br J Dermatol 1948; 60: 203–210.
7. Tritsch H, Greither A. Erythrosis pigmentata faciei. Arch Derm Syph Berlin 1955; 199: 221–227.
8. Glaze AI. Observations on two clinically distinctive varieties of erythema of uncertain classification. South Med J 1936; 29: 909–910.
9. Kitamura K, Kato H, Mishima Y, Sonoda S. Erythromelanosis follicularis faciei. Hautarzt 1960; 9: 391–393.
10. Mishima Y, Rudner E. Erythromelanosis follicularis faciei et colli. Dermatologica 1966; 132: 269–287.
11. Andersen BL. Erythromelanosis follicularis faciei et colli. Br J Dermatol 1980; 102: 323–325.
12. Watt TL, Kaiser JS. Erythromelanosis follicularis faciei et colli. J Am Acad Dermatol 1981; 12: 33–35.
13. Whittaker SJ, Griffiths WAD. Erythromelanosis follicularis faciei et colli. Clin Exp Dermatol 1987; 12: 33–35.

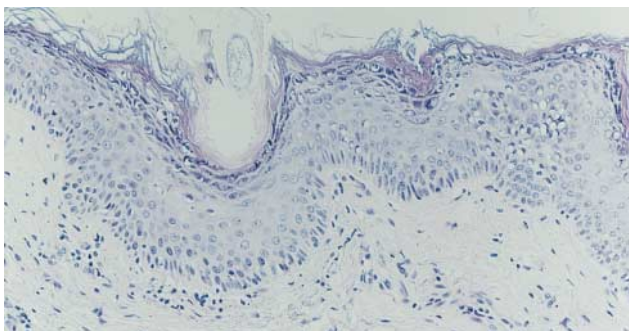


Fig. 2. Histology from the cheek shows dilated follicles, with a thick granular layer, acanthosis and dermal monocytic infiltrates.