

Somatostatin- and Factor XIIIa-immunoreactive Cells in Psoriasis during Clobetasol Propionate and Calcipotriol treatment

TOOMAS TALME¹, MARIANNE SCHULTZBERG², KARL-GÖSTA SUNDQVIST³ and JAN A. MARCUSSON¹

¹Department of Dermatology, Huddinge University Hospital, Huddinge, ²Department of Clinical Neuroscience, Geriatric Medicine, Karolinska Institute, Novum, Huddinge and ³Department of Immunology, Umeå University Hospital, Umeå, Sweden

This study describes the changes in number and distribution of somatostatin- and factor XIIIa-immunoreactive dendritic cells in the epidermis and dermis of psoriatic lesional skin during topical treatment with clobetasol propionate or calcipotriol. Immunohistochemical analysis showed that the number of each cell type was increased in lesional skin as compared to normal skin. Investigation of serial biopsies from psoriasis lesions revealed a significant reduction in the number of somatostatin- and factor XIIIa-positive dendritic cells during the treatments. The reduction rate of the somatostatin-positive cells differed between the two groups and closely paralleled the healing process induced by the two treatments. These findings and the fact that somatostatin has been used in several studies as treatment for psoriasis may indicate that the somatostatin-positive cells are specifically involved in the healing process of psoriasis. The reduction of the factor XIIIa-positive cells was associated with the healing process as a whole, but showed no relation to either treatment. Key words: dendritic cells; epidermal thickness; immunohistochemistry; psoriasis.

(Accepted June 29, 1998.)

Acta Derm Venereol (Stockh) 1999; 79: 44–48.

T. Talme, Department of Dermatology, Huddinge University Hospital, S-141 86 Huddinge, Sweden.

Somatostatin is a 14 amino acid peptide with inhibitory action on many neuropeptides and hormones (1). Its synthetic analogue, octreotide, is utilized as treatment for certain neuroendocrine tumours and after pancreatic surgery (2). In several studies (most of them open and one controlled), somatostatin has been used as treatment for psoriasis with a clearance rate between 30–80% (3–7). Somatostatin immunoreactive cells with dendritic morphology are found in elevated numbers in the epidermis and dermis of psoriatic plaques as compared to healthy human skin (8). These dendritic cells do not coexpress CD1a, CD35, CD45, CD68, factor XIIIa or S-100. However, a subgroup of the cells located in the psoriatic epidermis coexpresses HLA-DR (8). Consequently, these cells probably represent a specific population of dendritic cells in human skin, distinct from other dermal dendritic cells such as Langerhans' cells and factor XIIIa-positive cells (8). In earlier communications we have shown that treatment with peptide T (a synthetic octapeptide) induced changes in the number of the dermal somatostatin immunoreactive cells in psoriasis lesions, indicating that these cells play a role in the pathogenesis and/or healing process in psoriasis (9, 10).

Subunit A of the clotting factor XIII (FXIIIa) is expressed in a population of dendritic cells distributed mainly in the upper dermis and around superficial blood vessels. These cells occur in increased numbers in psoriatic skin (11) and seem to be of

bone marrow origin, sharing some features common to monocytes/macrophages (11).

The aim of this study was to investigate deviation over time in the number and distribution of somatostatin- and FXIIIa-positive cells in psoriatic lesional skin during healing accomplished with two commonly used topical therapies, clobetasol propionate and calcipotriol ointments.

MATERIAL AND METHODS

Twenty patients (9 women, 11 men, aged 24–64) with moderately severe chronic plaque psoriasis participated in the study. There was a 2-week washout period prior to enrolment. Ten of the patients were treated with a topical corticosteroid, 0.05% clobetasol propionate ointment (Glaxo Wellcome Operations, Greenford, UK), applied BID the first week, once daily the second, every second day the third and for two days the fourth week; 10 patients were treated with a topical vitamin D analogue, 50 µg/g calcipotriol ointment (Lövens Kemiske Fabrik, Ballerup, Denmark) BID for 4 weeks. One lesion was chosen as the site for evaluation and biopsies (in 18 cases the elbow, in 1 case the leg and in another the back). The clinical course was scored according to desquamation, erythema and infiltration as follows: 0no visible lesion, 1mild, 2moderate and 3severe.

Punch biopsies (4 mm in diameter) from lesional psoriatic skin were taken before and after 1, 2 and 4 weeks of treatment. Lidocain without epinephrine (Astra, Södertälje, Sweden) was used as local anaesthetic. Biopsies from uninvolved skin just below the elbow from 6 patients (1 woman, 5 men, aged 43–64) and from 10 healthy volunteers (3 women, 7 men, aged 22–50) served as controls.

The biopsies were immersed for 3 h in 4% paraformaldehyde containing 14% saturated picric acid in 0.1 M Sörensen phosphate buffer (pH 7.4) at 4°C, and then rinsed in the same buffer containing 10% sucrose for at least 24 h. Sections (12 µm) were cut on a cryostat (Microm HM 500 M) and stored at –20°C. The staining was performed by an indirect immunofluorescence technique according to Coons (12). As primary antisera, we used polyclonal rabbit antibodies raised against human somatostatin diluted 1:200 (Peninsula, St. Helens, UK), and against FXIIIa diluted 1:800 (Calbiochem, San Diego, CA, USA).

The skin sections were incubated with the primary antibodies in a humid atmosphere at 4°C overnight. After rinsing in phosphate buffered saline (PBS) pH 7.4, the sections were incubated for 60 min at room temperature (21°C) with fluorescein isothiocyanate (FITC)-labelled swine anti-rabbit IgG(fab) diluted 1:100 (Dako, Glostrup, Denmark). To prevent fading of the fluorescence, paraphenylenediamine was added to the mounting medium (13). The material was examined under a fluorescence microscope (Zeiss Axioplan) equipped with an MC 100 camera.

The somatostatin- and FXIIIa-labelled cells were counted per linear millimeter (mm) in the epidermis, papillary dermis and upper 0.25 mm of the reticular dermis in two different sections per biopsy. The healing process was also followed by measuring the thickness of the living epidermis from the granular layer to the tips of the rete ridges (epidermal thickness) using an ocular micrometer. Twenty rete ridges per section were measured in two different sections per biopsy. All readings and measurements in the microscope were performed on coded sections.

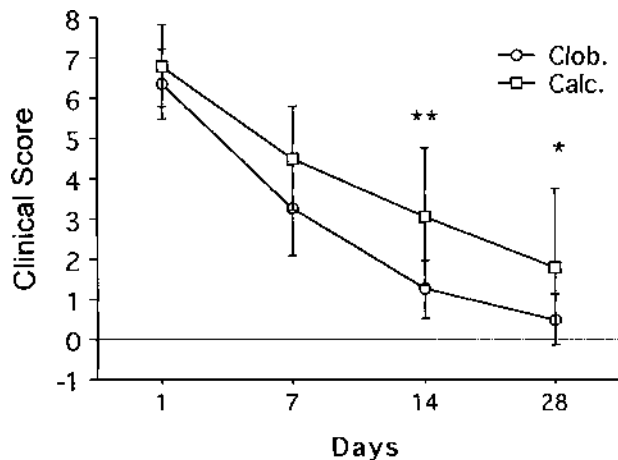


Fig. 1. Clinical score during treatment with clobetasol (clob) and calcipotriol (calc). The sum of the scores (mean \pm 1SD) for the three variables desquamation, erythema and infiltration. Difference between groups (* $p < 0.05$; ** $p < 0.01$).

The specificity of the somatostatin antibody was tested by preabsorption with somatostatin-14, giving a final peptide concentration of 30 nM. In addition, omission of the primary antisera served as control.

Statistical methods

Results were analysed using two-way analysis of variance (ANOVA) with repeated measures on one factor. In case of significant interaction between each treatment group and time, simple effects were examined, i.e. effects of one or more factors when other factors were fixed. The p -values were then corrected according to the Bonferroni procedure. The distribution for some of the variables was skewed and the data have therefore been log-transformed in order to meet requirements for an adequate ANOVA. When the compound symmetry assumptions were not valid in ANOVA, the F-test was adjusted according to the method of Kirk (14).

For the variables somatostatin- and FXIIIa-positive cells, the differences from day 0 in lesional skin and healthy skin were analysed by Wilcoxon signed rank test within group and with Mann-Whitney U test between groups.

RESULTS

Clinical course

The clinical scores improved significantly during treatment with clobetasol and calcipotriol ointment ($p < 0.0001$) (Fig. 1), but the improvement in the clobetasol group was faster and more pronounced ($p < 0.01$).

We also followed the healing process by measuring the epidermal thickness (Fig. 2). Initially, the epidermis was significantly thicker in the lesional psoriatic skin as compared with skin from healthy volunteers ($p < 0.0001$) and uninvolved skin of psoriasis patients ($p < 0.001$). Both treatments resulted in a significant reduction over time of the epidermal thickness ($p < 0.0001$), but the reduction was slower in the calcipotriol group as compared with the clobetasol group ($p < 0.001$) (Fig. 2).

Somatostatin-positive cells

In lesional psoriatic skin, dendritic somatostatin-positive cells were found mainly in the papillary and upper reticular dermis (Fig. 3A). Some cells, located just under the basement mem-

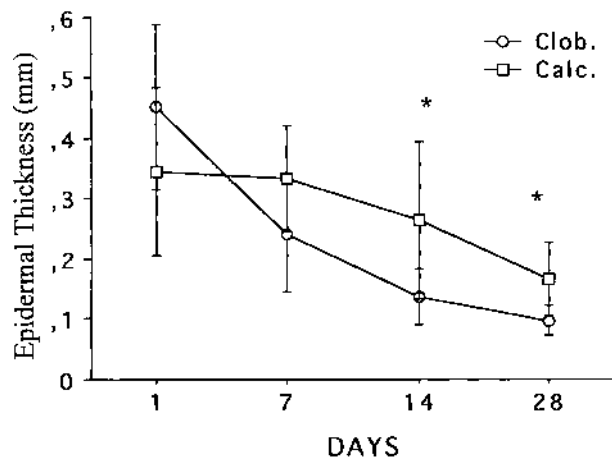


Fig. 2. Epidermal thickness during treatment with clobetasol (clob) and calcipotriol (calc). The epidermal thickness in mm (mean \pm 1SD). Difference between groups (* $p < 0.05$).

brane, extended their dendritic processes into the epidermis. A few cells were also present in the spinous and basal layers of the epidermis. Preabsorption of the somatostatin antiserum with somatostatin-14 or omission of the primary antiserum resulted in an absence of somatostatin-like immunoreactivity.

The number of somatostatin-positive dendritic cells in lesional psoriatic skin varied from 21–90 cells per mm (dermis) and 0–2 cells per mm (epidermis). In uninvolved skin of psoriasis patients and in healthy controls, the somatostatin-positive cells were only seen in the dermis. The number varied from 5–14 cells per mm (dermis) in uninvolved skin of psoriasis patients and from 2–12 cells per mm (dermis) in healthy controls. The number of somatostatin-positive cells in the psoriatic lesions was thus significantly increased in both the dermis and epidermis as compared to skin from healthy controls (dermis $p < 0.0001$, epidermis $p < 0.001$) as well as uninvolved skin from psoriasis patients (dermis $p < 0.01$, epidermis $p < 0.05$).

The number of somatostatin-positive cells was significantly reduced in the dermis ($p < 0.0001$) by the two treatments (Figs. 3A, B, 4A), but the reduction of the somatostatin-positive cells was faster in the clobetasol group ($p < 0.001$) (Fig. 4A). In the epidermis, the somatostatin-positive cells were significantly reduced only in the clobetasol group after 14 and 28 days of treatment ($p < 0.05$) (Fig. 4B).

FXIIIa-positive cells

The FXIIIa-positive dendritic cells were more numerous than the somatostatin-positive dendritic cells in psoriatic lesional skin both in the dermis and in the epidermis ($p < 0.0001$). The cells were observed mainly in the upper dermis and around superficial blood vessels (Fig. 5A). Their number varied from 2–26 cells per mm (epidermis), and 78–184 cells per mm (dermis). In uninvolved skin of psoriasis patients and in healthy controls, the FXIIIa-positive dendritic cells were only observed in the dermis, their number varying from 48–69 cells/mm in uninvolved skin of psoriasis patients and 26–63 cells/mm in healthy controls. The number of FXIIIa-positive cells in the psoriatic lesions was significantly increased in both the dermis and epidermis as compared to skin from healthy controls (dermis $p < 0.0001$, epidermis $p < 0.0001$) as well as uninvolved skin from psoriasis patients (dermis $p < 0.05$, epi-

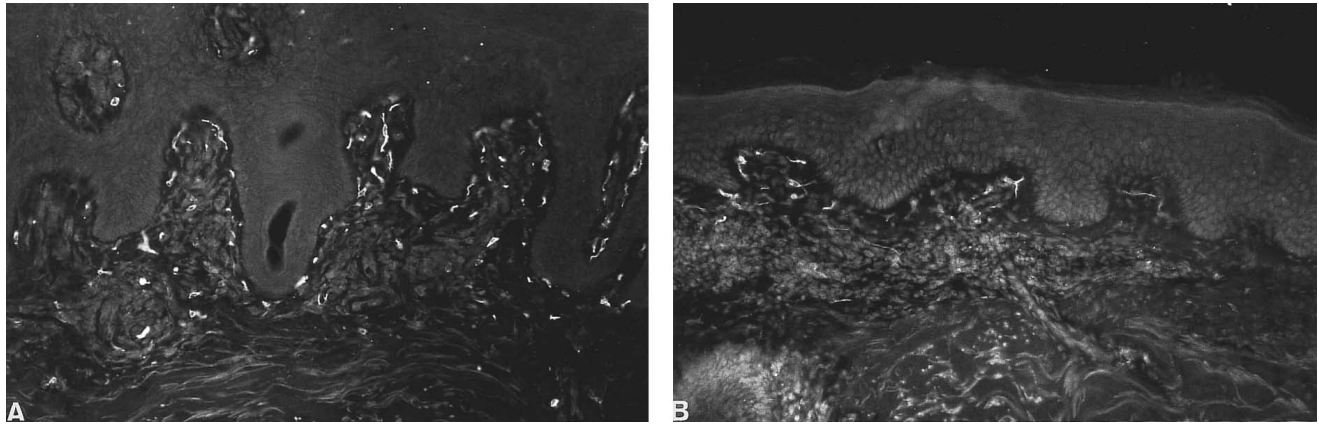


Fig. 3. Somatostatin immunoreactive dendritic cells in lesional psoriatic skin before (A) and after (B) 4 weeks of calcipotriol treatment ($\times 200$).

dermis $p < 0.05$). Omission of the primary antiserum resulted in an absence of FXIIIa-like immunoreactivity.

The number of FXIIIa-positive cells significantly decreased over time in the dermis ($p < 0.001$) during treatment with clobetasol and calcipotriol (Figs. 5A, B). The reduction of the FXIIIa-positive cells over time did not differ between the two

treatments. In the epidermis, the FXIIIa-positive cells were significantly reduced by both treatments after 14 and 28 days ($p < 0.05$).

DISCUSSION

Somatostatin- and FXIIIa-immunoreactive cells constitute two cell populations displaying a dendritic morphology, which are present in elevated numbers in lesional psoriatic skin (8, 11). Whether and how the somatostatin- and FXIIIa-positive dendritic cells affect adjacent cells such as T-lymphocytes, endothelial cells and keratinocytes in the psoriasis lesion is, at present, unknown. It is also an open question whether these cells are bystanders in the inflammatory reaction or whether they can contribute to the healing process.

In the present open-controlled study, we have investigated changes in the number and distribution of these two cell types in psoriatic skin during two well established topical treatment alternatives of psoriasis, clobetasol propionate and calcipotriol. The therapy and observation lasted 4 weeks, and biopsies were collected before and 3 times during the treatment. The healing process was followed in two ways: first with clinical scoring, which was performed openly, and secondly by microscopic measurement of the epidermal thickness, which was made on blind-coded specimens.

The number of somatostatin-positive cells in the dermis was significantly reduced during the healing of psoriasis induced by the topical therapies. This reduction occurred earlier in the clobetasol-treated group than in the calcipotriol-treated one. The different time course between the two drug treatments paralleled the rates of clinical improvement, especially when measured as the reduction in epidermal thickness. A significant reduction of the number of somatostatin-positive cells in the epidermis could be seen in the clobetasol-treated group, although these cells were much fewer in that skin compartment. Somatostatin affects a variety of immunocompetent cell functions, such as inhibition of T-lymphocyte proliferation (15), immunoglobulin production by B-lymphocytes (16) and neutrophil chemotaxis provoked by substance P (17). Somatostatin may participate in the anti-inflammatory actions of glucocorticoids, since somatostatin immunoreactivity in inflammatory sites is stimulated by dexamethasone, while in parallel, the local inflammatory exudates are suppressed (18).

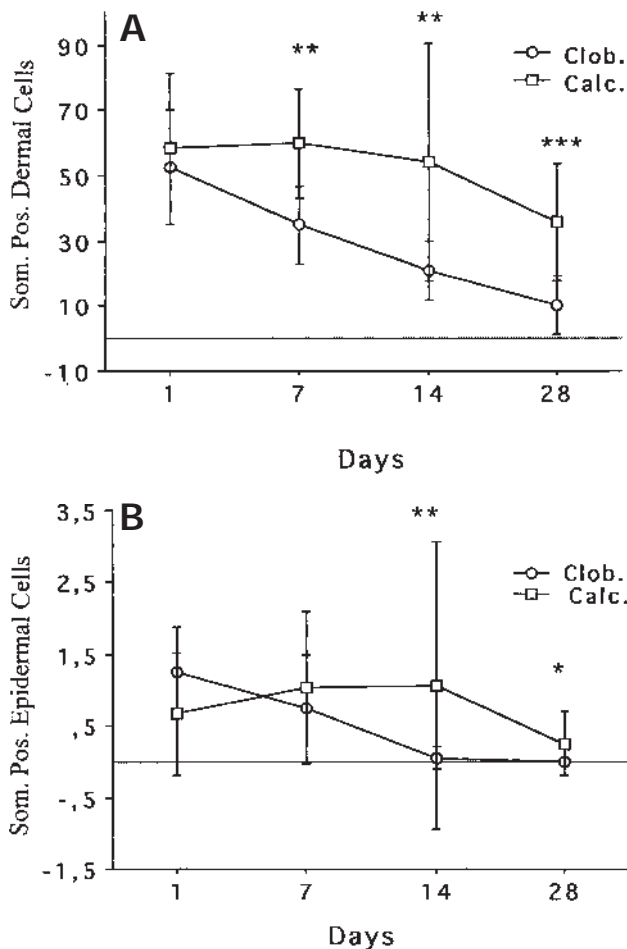


Fig. 4. Somatostatin immunoreactive cells in the dermis (A) and the epidermis (B) during treatment with clobetasol (clob) and calcipotriol (calc). The cell number per mm (mean ± 1 SD). Difference between groups (* $p < 0.05$; ** $p < 0.01$; *** $p < 0.001$).

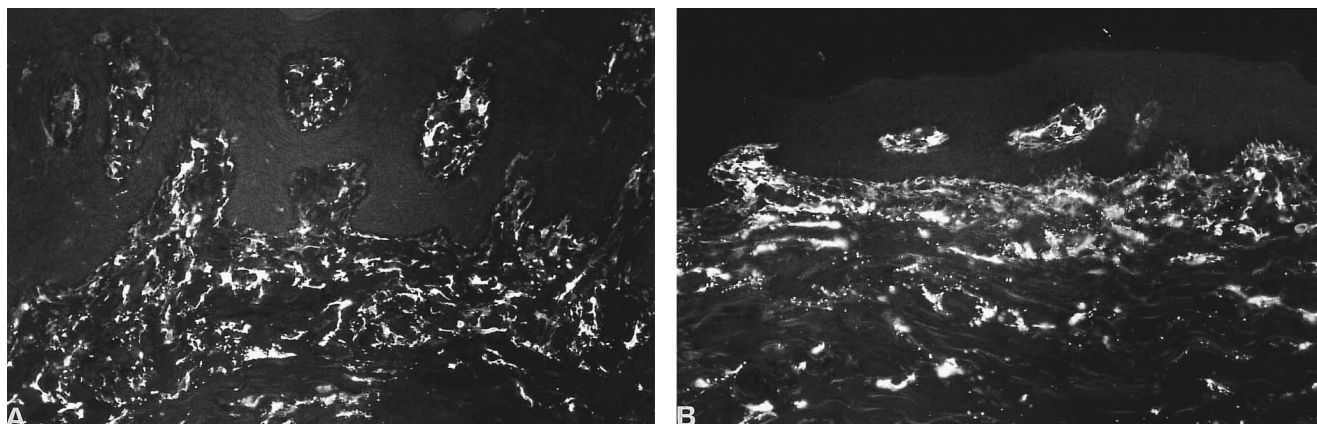


Fig. 5. Factor XIIIa immunoreactive dendritic cells in lesional psoriatic skin before (A) and after (B) 4 weeks of calcipotriol treatment ($\times 200$).

The increase in somatostatin-positive cells in psoriasis may thus be a local host defence mechanism.

Merkel cells are constituents of normal skin mainly located in the basal layer of the epidermis in close contact with nerve endings, but with unknown function. Several peptides have been identified in the granulae of Merkel cells. Merkel cells have been observed in increased amounts in the psoriatic epidermis, and, in contrast to normal skin, a subgroup of these cells (7%) expresses somatostatin (19). In fact, the somatostatin-positive cells localized in the epidermis described in this study may be Merkel cells.

The number of FXIIIa-positive dendritic cells in the epidermis and dermis was reduced equally by the two treatment modalities. This may reflect that changes in the FXIIIa-positive cells are not specifically linked to the topical medicaments used. Factor XIIIa is a fibrin stabilizing factor which covalently cross-links fibrin monomers to a protein that forms a stable clot. FXIIIa is found intra- and extracellularly. FXIIIa expressing dermal dendritic cells has been linked to various dermatological conditions, including psoriasis (20). FXIIIa-positive cells belong to one of the three most proliferative cell types in psoriatic lesional skin. The other two are T-cells and endothelial cells (21). Since this population of dendritic cells is concentrated around papillary blood vessels, it has been suggested that FXIIIa can be released locally, when necessary, to stabilize clots (22). FXIIIa can also mediate adhesion of various cells (23). FXIIIa-positive cells express MHC class II antigen, and may thus be capable of presenting antigen to T-cells (11).

In conclusion, somatostatin- and FXIIIa-positive cells represent two specific dendritic cell populations with multiple potential, but so far unknown functional properties. Topical treatment with clobetasol propionate and calcipotriol significantly reduces both cell populations during the healing of psoriasis. The reduction rate of the somatostatin-positive cells differs between the two treatments and closely parallels the healing process, while the reduction of the factor XIIIa-positive cells shows no relation to either treatment. Perhaps the somatostatin-positive cells are more sensitive to corticosteroid treatment than the FXIIIa-positive cells. The correlation between the clinical improvement and the reduction of the somatostatin-positive cells, in addition to the fact that somatostatin has been used in several studies as treatment for psor-

iasis, also indicates that the somatostatin-positive cells may participate specifically in the healing process of psoriasis.

ACKNOWLEDGEMENTS

This study was supported by grants from the Welanders-Finsen Foundation, the Swedish Psoriasis Association and the Swedish Society for Medical Research. We thank Elisabeth Berg, Division of Medical Statistics, Karolinska Institute, for helpful statistical advice during this study.

REFERENCES

1. Wilson J, Foster D. Textbook of endocrinology. 8th ed. Philadelphia: Saunders Company, 1992.
2. Editorial. Octreotide steaming ahead. *Lancet* 1992; 339: 837–839.
3. Weber G, Klughart G, Neidhardt N, Galle K, Frey H, Geiger A. Treatment of psoriasis with somatostatin. *Arch Dermatol Res* 1982; 272: 31–36.
4. Guilhou JJ, Boulanger A, Barneon G, Vic P, Meynadier J, Tardieu JC, et al. Somatostatin treatment of psoriasis. *Arch Dermatol Res* 1982; 274: 249–257.
5. Venier A, De Simone C, Forni L, Ghirlanda G, Uccioli L, Serri F, et al. Treatment of severe psoriasis with somatostatin: four years of experience. *Arch Dermatol Res* 1988; 280: S51–S54.
6. Matt LH, Kingston TP, Lowe NJ. Treatment of severe psoriasis with intravenous somatostatin. *J Dermatol Treat* 1989; 181: 81–82.
7. Camisa C. Somatostatin and a long-acting analogue, octreotide acetate. Relevance to dermatology. *Arch Dermatol* 1989; 1125: 407–412.
8. Talme T, Schultzberg M, Sundqvist K-G, Marcusson JA. Colocalization of somatostatin- and HLA-DR-like immunoreactivity in dendritic cells of psoriatic skin. *Acta Derm Venereol (Stockh)* 1997; 77: 338–342.
9. Pert C. The development of peptides and the promise of peptide T as treatment for AIDS. *Mod Med* 1989; 57: 44–53.
10. Johansson O, Hilliges M, Talme T, Marcusson JA. Somatostatin immunoreactive cells in psoriatic human skin during peptide T treatment. *Acta Derm Venereol (Stockh)* 1994; 74: 106–109.
11. Cerio R, Griffiths CEM, Cooper KD, Nickoloff BJ, Headington JT. Characterization of factor XIIIa-positive dermal dendritic cells in normal and inflamed skin. *Br J Dermatol* 1989; 212: 421–431.
12. Coons AH. Fluorescent antibody methods. In: Danielli JF, ed. *General cytochemical methods*. Vol 1. New York: Academic Press, 1958: 399–422.
13. Johnson GD, Nogueira Araujo GM. A simple method of reducing

- the fading of immunofluorescence during microscopy. *J Immunol Methods* 1981; 43: 349–350.
14. Kirk R. *Experimental design: procedures for the behavioral sciences*. Belmont, CA: Brooks/Cole, 1968.
 15. Payan DG, Hess CA, Goetzl EJ. Inhibition by somatostatin of the proliferation of T-lymphocytes and molt-4 lymphoblasts. *Cell Immunol* 1984; 84: 433–438.
 16. Stanisz AM, Scicchitano R, Payan DG, Bienenstock J. In vitro studies of immunoregulation by substance P and somatostatin. *Ann N Y Acad Sci* 1987; 496: 217–225.
 17. Kolasinski S, Haines K, Siegel E, Cronstein B, Abramson S. Neuropeptides and inflammation. A somatostatin analog as a selective antagonist of neutrophil activation by substance P. *Arthritis Rheum* 1992; 35: 369–375.
 18. Karalis K, Mastorakos G, Sano H, Wilder R, Chrousos G. Somatostatin may participate in the anti-inflammatory actions of glucocorticoids. *Endocrinology* 1995; 136: 4133–4138.
 19. Wolina U, Mahrle G. Epidermal Merkel cells in psoriatic lesions: immunohistochemical investigations on neuroendocrine antigen expression. *J Dermatol Sci* 1992; 3: 145–150.
 20. Nestle FO, Nickoloff BJ. A fresh morphological and functional look at dermal dendritic cells. *J Cutan Pathol* 1995; 22: 385–393.
 21. Morganroth G, Chan L, Weinstein G, Voorhees J, Cooper K. Proliferating cells in psoriatic dermis are comprised primarily of T cells, endothelial cells, and factor XIIIa+ perivascular dendritic cells. *J Invest Dermatol* 1991; 96: 333–340.
 22. Penneys N. Factor XIII expression in the skin: observation and a hypothesis. *J Am Acad Dermatol* 1990; 22: 484–488.
 23. Ueki S, Takagi J, Saito Y. Dual functions of transglutaminase in novel cell adhesion. *J Cell Science* 1996; 11: 2727–2735.