

Upregulation of RANTES in Psoriatic Keratinocytes: a Possible Pathogenic Mechanism for Psoriasis

SIBA P. RAYCHAUDHURI¹, WEN-YUE JIANG¹, EUGENE M. FARBER¹, THOMAS J. SCHALL², MICHAEL R. RUFF³ and CANDACE B. PERT³

¹Psoriasis Research Institute, Palo Alto, CA, USA, ²ChemoCentryx, San Carlos, CA, U.S.A. and ³Georgetown University Medical Center, Department of Physiology and Biophysics, School of Medicine, Washington, DC, U.S.A.

Intraepidermal collections of neutrophils and lymphocytes are unique features of the inflammatory reaction of psoriasis. Migration of leukocytes from dermis to the epidermis suggests a role for chemotactic agent(s). In recent years, increased levels of chemokines such as IL-8, GRO- α and MCP-1 have been reported in the keratinocytes of psoriatic tissue. IL-8 and GRO- α belong to a subfamily (C \times C) class and MCP-1 is a β chemokine. In this study, we investigated RANTES, which is a β chemokine (C-C class); RANTES has been found to be associated with various cell-mediated hypersensitive disorders. We obtained eight skin biopsies from chronic psoriatic plaques, and five biopsies each from non-lesional psoriatic skin, lichen planus, eczematous dermatitis and skin from healthy controls. Snap-frozen samples were cut into 7 μ m cryosections and stained with 6 mg/ml of monoclonal anti-RANTES mouse IgG (DNAX, Palo Alto, CA). Standard immunohistochemistry techniques were applied. RANTES was detected only in the keratinocytes. The number of keratinocytes in per mm² of epidermis stained for RANTES were 116.79 ± 98.42 in psoriatic tissues compared to 32.00 ± 46.05 ($p < 0.05$), 6.39 ± 3.59 ($p < 0.01$), 2.64 ± 1.15 ($p < 0.01$) and 3.53 ± 5.26 ($p < 0.01$), respectively, in the non-lesional, lichen planus, eczematous lesions and normal skin. This is the first study to report that the keratinocytes of psoriatic tissue express high levels of RANTES compared to the controls. IL-8 and related molecules (C \times C class) are predominantly chemotactic for neutrophils and MCP-1 is a strong chemotactic factor for monocytes. In contrast, RANTES is chemotactic for memory T cells and activated naive T cells. Increased amounts of RANTES as reported here provide an explanation for migration of the activated T cells to the epidermis of the psoriatic lesions. In addition, RANTES activates T cells. These results suggest that RANTES may have a significant role in the inflammatory process of psoriasis. Our findings further substantiate a regulatory role for keratinocytes in the inflammatory process of psoriasis. **Key words:** *β chemokine; chemotaxis; cutaneous inflammation.*

(Accepted May 22, 1998.)

Acta Derm Venereol (Stockh) 1999; 79: 9–11.

Eugene M. Farber MD, Psoriasis Research Institute 600, Town and Country Village, Palo Alto, CA 94301, U.S.A.

Psoriasis is a chronic inflammatory skin disease of unknown etiology. Histopathological features of psoriasis are epidermal hyperplasia accompanied by inflammatory infiltrates and vascular proliferation. Intraepidermal collections of neutrophils and lymphocytes are two of the unique features of the inflammatory process of psoriasis. Migration of leukocytes from the dermis to the epidermis suggests a role for chemotactic agents.

In recent years increased activity of chemokines such as IL-8, GRO- α and MCP-1 have been identified in the keratinocytes of psoriatic lesions (1–4). IL-8 and GRO- α belong to the α subfamily (C \times C class) and MCP-1 is a β chemokine (C-C class). The present study was undertaken to investigate the activity of another β chemokine, RANTES (C-C class). Increased activity of RANTES has been reported in various inflammatory conditions, such as rheumatoid arthritis (5), delayed-type hypersensitivity (6) and transplant rejection (7).

MATERIALS AND METHODS

Tissue preparation

Skin biopsies were obtained from chronic psoriatic plaque lesions ($n=8$), and five biopsies each from non-lesional psoriatic skin, lichen planus, eczematous dermatitis (three numular eczema, two contact dermatitis) and skin from healthy controls. Biopsies were taken from the edge of active psoriasis lesions that had not been receiving topical or systemic treatment for the prior 6 weeks. The samples were snap-frozen with liquid nitrogen and stored in refrigerator under -70°C .

The frozen samples were cut into 7 μ m cryosections. The sections were mounted on glass slides and fixed in 4% formalin for 10 min at room temperature. The sections were washed and then sequentially blocked for endogenous biotin binding using the Vector blocking kit (Vector Laboratories, Burlingame, CA), and for endogenous peroxidase activity and non-specific antibody binding sites with 3% hydrogen peroxide and 10% normal rabbit serum (Phoenix Pharmaceutical Inc., Mountain View, CA).

Immunohistochemistry staining

The sections were first incubated for 20 h with 6 mg/ml monoclonal anti-RANTES mouse IgG 2b (DNAX Research Institute, Palo Alto, CA) at room temperature. Mouse IgG 2b myeloma protein 6 mg/ml 2b (DNAX Research Institute, Palo Alto, CA) was used as an isotype control. Standard immunoperoxidase techniques were followed, secondary antibody along with color developing kits were bought from Phoenix Pharmaceutical Inc., Mountain View, CA. For negative controls except for using the primary anti-RANTES antibody the rest of the protocol was the same. In addition, we performed a preabsorption test of the RANTES-antibody to rule out non-specific positivity.

RESULTS

Positive staining was observed in the tissues stained only with the monoclonal anti-RANTES antibody (Figs. 1–3). Sections stained with the mouse IgG 2b (isotype control) and the sections which were stained with the RANTES antibody preabsorbed with RANTES did not show any positive staining for RANTES (Fig. 4). All sections were examined by one investigator (WYJ) and independent confirmation of the numerical counting was performed by another investigator (SPRC). Cells in which staining could be appreciated without doubt were only considered to be positively stained. Cells

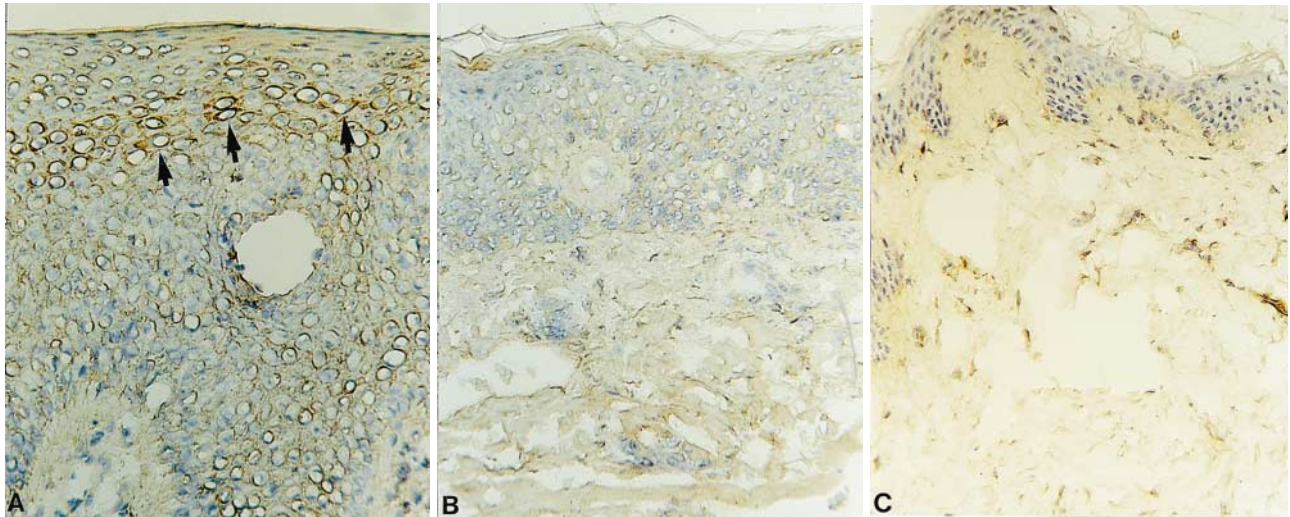


Fig. 1. High expression of RANTES within the keratinocytes in psoriatic plaque (A) is evident compared to very few positive cells in lichen planus skin (B) and normal control skin (C) ($\times 160$).

which were slightly colored or where the positivity was doubtful were ignored. Tissues were examined for the presence of positively stained cells. RANTES was detected only in the keratinocytes. In psoriatic tissues keratinocytes expressed high levels of RANTES throughout all levels of epidermis except in stratum corneum (Fig. 1). The number

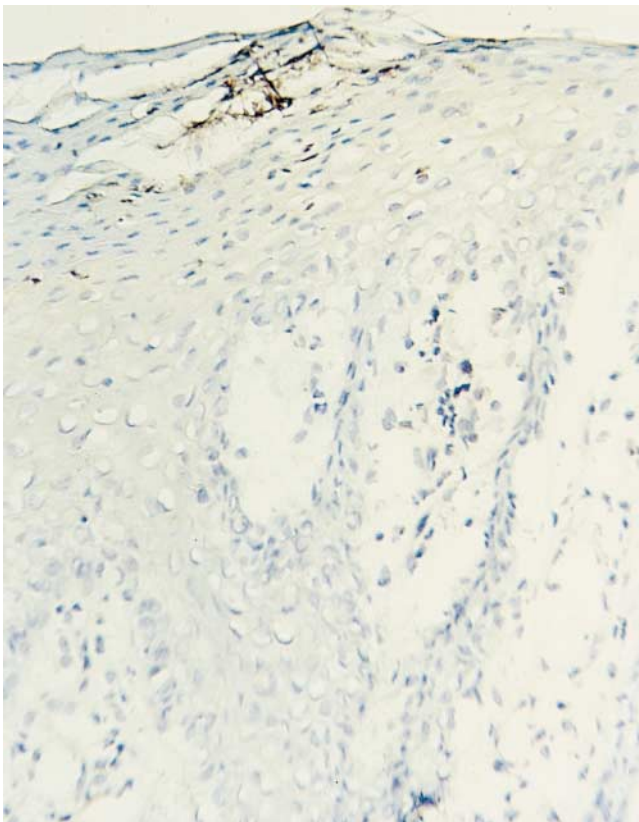


Fig. 2. Psoriatic tissue stained with preabsorbed RANTES antibody. Compared to Fig. 1, positive staining for RANTES is totally abolished ($\times 160$).

of cells positive for RANTES in per square mm of epidermis was calculated by dividing the total number of RANTES positive cells by the surface area. Surface area of the epidermis was determined with the help of a reticle/grid (10×10 mm with 1 mm^2 boxes; Microscoptics, Inc., Milford, MI) placed in the eye piece. The data are described in Table I. The number of keratinocytes in per mm^2 of epidermis stained for RANTES was 116.79 ± 98.42 in psoriatic tissues compared with 32.00 ± 46.05 ($p < 0.05$), 6.39 ± 3.59 ($p < 0.01$), 2.64 ± 1.15 ($p < 0.01$) and 3.53 ± 5.26 ($p < 0.01$) in non-lesional skin, lichen planus, eczematous lesions and normal skin, respectively. RANTES expression in the non-lesional psoriatic keratinocytes was relatively higher compared to the normal control skin, eczematous lesions and lichen planus lesions but did not reach statistical significance ($p 0.121$, $p 0.446$ and $p 0.141$, respectively). Statistical analysis: Data in respect to cell counts are presented as mean \pm SD (Table I); for statistical analysis, the *t*-test was applied.

DISCUSSION

This is the first study to report that keratinocytes of psoriatic lesions express high levels of RANTES compared to the controls (Figs. 1–3). Chemokines are produced by a variety of cells and their production is regulated by various proinflammatory cytokines. RANTES is secreted by activated T lymphocytes,

Table I. Expression of RANTES in the keratinocytes of psoriasis lesional, non-lesional, lichen planus and normal skin

Biopsies	No.	RANTES+ KC/mm (mean \pm SD)	RANTES+ KC/ mm^2 (mean \pm SD)
Psoriasis	8	17.05 ± 14.37	116.79 ± 98.42
Psoriasis-non-lesional	5	1.25 ± 1.80	32.00 ± 46.05
Lichen planus	5	0.56 ± 0.31	6.39 ± 3.59
Eczema	5	2.64 ± 1.15	35.17 ± 15.34
Normal	5	0.12 ± 0.18	3.53 ± 5.26

keratinocytes, fibroblasts and epithelial cells subsequent to stimulation with TNF- α and IFN- α (8–11). Additional studies are required to determine whether the increased levels of RANTES in psoriatic keratinocytes is a secondary or a primary event.

IL-8 and related molecules (C \times C class) are predominantly chemotactic for neutrophils (7, 12, 13) and MCP-1/MCAF (monocyte chemotactic and activating factor) is predominantly a chemotactic protein for monocytes. Intradermal injection of IL-8 does not cause an accumulation of lymphocytes (14). RANTES is chemotactic for resting CD4⁺ memory T cells, and activated naive and memory T cells (13). Increased activity of RANTES as reported in this study provides an explanation for the epidermotropism of activated T cells (15–17) in psoriatic tissue. In addition, RANTES activates T lymphocytes (7). Thus RANTES may have a significant role in the pathogenesis of psoriasis.

REFERENCES

- Schroder J, Christophers E. Identification of C5a des arg and an anionic neutrophil activating peptide (ANAP) in psoriatic scales. *J Invest Dermatol* 1986; 87: 53–58.
- Schroder J, Gregory H, Young J, et al. Neutrophil-activating proteins in psoriasis. *J Invest Dermatol* 1992; 98: 241–247.
- Kulke R, Todt-Pingel I, Rademacher D, Rowert J, Schroder J, Christophers E. Co-localized overexpression of GRO- α and IL-8 mRNA is restricted to the suprapapillary layers of psoriatic lesions. *J Invest Dermatol* 1996; 106: 526–530.
- Deleuran M, Buhl L, Ellingsen T, et al. Localization of monocyte chemotactic and activating factor (MCAF/MCP-1) in psoriasis. *J Dermatol Sci* 1996; 13: 228–236.
- Smowden N, Hajeer A, Thomson W, et al. RANTES role in rheumatoid arthritis. *Lancet* 1994; 343: 547–548.
- Deveregne O, Marfaing-Koka A, Schall TJ, et al. Production of the RANTES chemokine in delayed-type hypersensitivity reactions: involvement of macrophages and endothelial cells. *J Exp Med* 1994; 179: 1689–1694.
- Pattison JM, Nelson PJ, Huie P, et al. RANTES chemokine expression in cell mediated transplant rejection of the kidney. *Lancet* 1994; 343: 209–211.
- Schall TJ. Biology of the RANTES/SIS cytokine family. *Cytokine* 1991; 3: 165–183.
- Pattison JM, Nelson PJ, Krensky AM. The RANTES chemokine: a new target for immunomodulatory therapy? *Clin Immunother* 1995; 4: 1–8.
- Li J, Ireland GW, Farthing PM, Thornhill MH. Epidermal and oral keratinocytes are induced to produce RANTES and IL-8 by cytokine stimulation. *J Invest Dermatol* 1996; 106: 661–666.
- Rathanaswami P, Hachicha M, Sadick M, et al. Expression of the cytokine RANTES in human rheumatoid synovial fibroblasts. *J Biol Chem* 1993; 268: 5834–5839.
- Baggiolini M, Dewald B, Moser B. Interleukin-8 and related chemotactic cytokines – C \times C and C-C chemokines. *Adv Immunol* 1994; 55: 97–179.
- Schall TJ, Bacon K, Toy KJ, Goeddel DV. Selective attraction of monocytes and T lymphocytes of the memory phenotype by cytokine RANTES. *Nature* 1990; 347: 669–671.
- Leonard EJ, Yoshimura T, Tanka S, Raffeld M. Neutrophil recruitment by intradermally neutrophil attractant/activation protein-1. *J Invest Dermatol* 1991; 96: 690–694.
- Braun-Falco O. The initial psoriatic skin. In: Farber EM, Cox AJ, eds. *Psoriasis. Proceedings of the 2nd International Symposium*. Stanford: Stanford University Press.
- Heng MCY, Kloss SG. Cell interaction in psoriasis. *Arch Dermatol* 1985; 121: 881–887.
- Nikaein A, Morris L, Phillips C, et al. Characterization of T-cell clones generated from skin of patients with psoriasis. *J Am Acad Dermatol* 1993; 128: 493–499.