

Interleukin-8 Plays its Role at Local Level in Psoriasis Vulgaris

MICHAEL STICHERLING, WOLFRAM SAUTIER, JENS -M. SCHRÖDER and ENNO CHRISTOPHERS

Department of Dermatology, Clinical Research Group, University of Kiel, Kiel, Germany

The pro-inflammatory properties of interleukin-8 (IL-8) suggest a major role of this peptide in inflammatory processes of skin and other organs. Both biochemical and immunohistochemical studies from our group have demonstrated IL-8 peptide within psoriatic scales and epidermis. So far, however, the relevance of circulating IL-8 and its relation to locally produced IL-8 in this disease remain unclear. Serum IL-8 levels of psoriatic patients were determined in sandwich-ELISA prior to therapy as well as during therapy. Using either the assay from our laboratory or three commercial ELISAs, no correlation was found between serum IL-8 levels and disease severity at any stage of the disease. Similarly, epidermal IL-8-immunoreactivity was monitored immunohistochemically in sequential biopsies from individual psoriatic lesions as they resolved during the course of therapy. Initially, decreased epidermal IL-8 immunoreactivity shifted to a homogeneous staining comparable to normal or non-diseased skin as lesions resolved under treatment. These results indicate a role of IL-8 at local level in psoriatic skin. In contrast to hyperinflammatory diseases like sepsis, where increased serum IL-8 levels are found, in psoriasis either circulating IL-8 is absent or potent mechanisms are operative effectively binding and/or inactivating IL-8 as it enters circulation. Key words: chemokine; ELISA; immunohistochemistry; psoriatic skin; serum.

(Accepted June 2, 1998.)

Acta Derm Venereol (Stockh) 1999; 79: 4–8.

Michael Sticherling, Department of Dermatology, University of Kiel, Schittenhelmstr. 7, D-24105 Kiel, Germany.

Interleukin-8 (IL-8) is probably the best-known member of the family of chemokines (1, 2). Experimental data document its role within a cascade of inflammatory events. These are focused and amplified by the action of IL-8 by local attraction and activation of different leukocyte subsets – prominently neutrophilic granulocytes and lymphocytes (3). Under clinical conditions, IL-8 has been demonstrated at tissue level (2–4) as well as systemically (2). In respect of dermatological diseases, the limited number of studies available (3) tend to focus on psoriasis. Using biochemical analysis, considerable amounts of IL-8 have been purified from scale material collected from patients with psoriasis vulgaris (5, 6). Furthermore, both mRNA and IL-8 peptide have been detected *in situ* in psoriatic skin (7–11). Increased IL-8 blood levels have been demonstrated in a number of systemic inflammatory disorders (2); the role of circulating IL-8 in psoriasis, however, has not been adequately addressed in the past.

To study both local and systemic IL-8 levels in comparison to disease activity, a large group of patients with psoriasis were examined. Serum IL-8 levels were determined prior to therapy and during the course of treatment using a number of different immunoassays. At the same time, sequential biopsies taken from single psoriatic lesions during therapy were examined immunohistochemically.

MATERIAL AND METHODS

The study has been approved by the local ethics committee. Patients agreed to participate by written consent after appropriate consulting.

Serum samples from psoriatic patients

Prior to therapy, as well as once every week under therapy, serum samples were obtained from 63 psoriatic patients. Simultaneously, disease severity was monitored by assessing the psoriasis area and severity index (PASI) (12). Major laboratory parameters, including blood sedimentation rate, liver enzymes and blood cell counts, were evaluated at the same time points.

Immunoassays for serum IL-8 concentrations

Serum samples from all patients were tested in a sandwich ELISA using monoclonal anti-IL-8-antibodies (moAb) as described previously (13). moAb 52E8 served as coating and moAb 14E5 coupled to biotin as detecting antibody. Colour reaction was induced using the avidin-biotin-peroxidase-complex method with o-phenylenediamine as colour reagent. Serial dilutions of recombinant IL-8 (Pepro- tech, London) were always included and relevant IL-8 levels read from the standard curve. The ELISA was shown to be specific for IL-8 with a detection limit of 50 pg/ml. Similarly, serum samples taken before initiation of therapy were tested in three different commercial IL-8-ELISAs according to manufacturers' instructions (R&D, Minneapolis, USA; Bender, Vienna; Amersham, Germany).

Skin biopsies from patients with psoriasis vulgaris

Among 10 patients participating in this part of the study, five presented with the clinical aspect of guttate psoriasis; the other five showed plaque type psoriasis. Biopsies were obtained on the day of admission to hospital prior to treatment and thereafter sequentially at 10-day intervals. Altogether, 3–6 biopsies were taken from each patient during the time of hospital treatment. Therapy consisted of topical steroids under occlusion or dithranol in conjunction with PUVA or UVB treatment. Four-mm punch biopsies were taken from the border of the same psoriatic lesions for each patient in a standard manner after local anaesthesia (Scandicain 1%), snap-frozen and stored in liquid nitrogen until further processing.

Immunohistochemical examination of IL-8 expression

Between 4 and 6 µm cryostat sections of the sequential biopsies were processed as described earlier (10, 14). Briefly, after fixation with acetone for 10 min, moAb 52E8 was added as primary antibody. Colour reaction was achieved using the avidin-biotin-peroxidase method with a goat-anti-mouse IgG antibody coupled to biotin, avidin-biotin-peroxidase complex (ABC-kit, Vector Labs., Burlingame, England) and diaminobenzidine as colour reagent. moAb 52E8 has been produced and extensively characterized as described earlier (10, 15, 16). For immunohistochemical studies, culture supernatants from the respective clone were used at appropriate dilutions tested in advance. Negative controls consisted of isotype-matched irrelevant antibodies or substitution of primary antibody by buffer. Immunohistochemical results were evaluated by two independent investigators in respect to IL-8-immunoreactivity related to parakeratosis, acanthosis and dermal as well as epidermal inflammatory infiltrate. Grading was from 0 (negative) to +++ (intense).

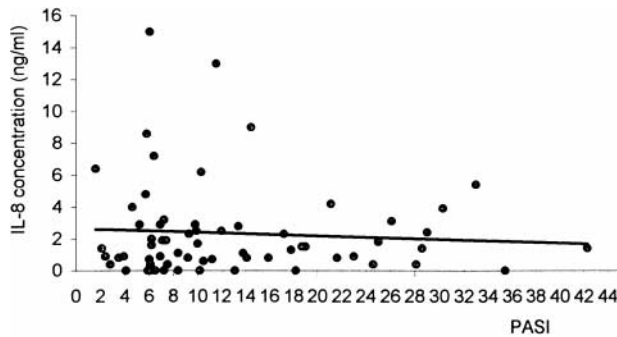


Fig. 1. Serum IL-8 levels do not correlate to PASI score prior to treatment.

RESULTS

Serum IL-8 levels

Serum IL-8 levels as detected in the ELISA established in our laboratory (13) ranged from 2 to 16 ng/ml. They did not correlate to the PASI prior to treatment, which varied from a score between 2 and 42 (Fig. 1). Furthermore, no correlation could be found to serum parameters like blood sedimentation rate, blood cell count or hepatic enzymes (results not shown). During the course of therapy with clinical resolution of psoriatic lesions, individual IL-8 levels did not correlate to clinical improvement. Instead, they were found static within most patients, with both a slight decrease and increase in a few others (results not shown). Similarly, differences among therapeutic regimens used in this study could not be detected (results not shown).

In addition to our own assay, serum samples were tested in three commercially available IL-8 ELISAs. Representative results on a set of 18 different serum samples are shown in Fig. 2 for all four assays used in this study. Widely diverging IL-8 levels could be found within the same serum samples. However, in not one of the ELISAs used could a correlation with PASI be found.

Immunohistochemical studies

In immunohistology using moAb 52E8, one patient each with either plaque type and guttate psoriasis demonstrated homogeneous staining of suprabasal keratinocytes in all sequential biopsies. All other patients showed reduced epidermal staining in the first biopsy taken at the time of admission to the hospital without prior treatment. Decrease of staining prior to treatment consisted in a loss of immunoreactivity in the lower keratinocyte layers, the extent of which varied from patient to patient (Fig. 3A).

Upon resolution of skin lesions during the course of therapy, a homogeneous staining of all suprabasal keratinocytes was gradually regained parallel to a decrease of acanthosis and inflammatory infiltration (Fig. 3A–D). At the time of dismissal from hospital, skin lesions had vanished for all but residual erythema in some cases. At that time, immunohistochemical staining for IL-8 was comparable to that of normal or non-diseased psoriatic skin. In respect of the different therapy regimens used, no differences in immunohistochemical staining pattern nor time-course could be seen.

At all clinical stages, epidermal IL-8 immunoreactivity was

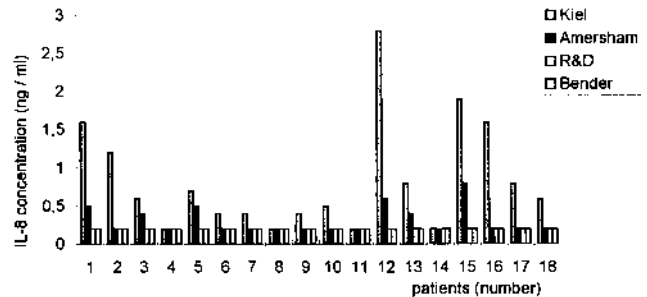


Fig. 2. Comparison of IL-8 levels detected in 18 representative psoriatic serum samples using four different IL-8 ELISAs. Grossly diverging results were found, none of which correlated to PASI.

prominent. In the dermis, staining was occasionally seen within endothelial cells, dendritic and mononuclear cells and could be related neither to the degree of inflammatory infiltration nor clinical state. It in fact varied between different patients as well as within several biopsies taken from single patients. Cells of the acrosyringium and hair follicle always remained positive in sharp contrast to surrounding keratinocytes.

DISCUSSION

IL-8 has been detected in a number of inflammatory disorders (2) like rheumatoid arthritis (17), sepsis (18), inflammatory lung diseases (19) as well as various dermatological disorders (2, 4). Our group has presented biochemical data on the involvement of the peptide in psoriasis vulgaris by demonstrating biologically active IL-8 in psoriatic scales (3–5). Furthermore, in immunohistochemical studies, psoriatic skin (10) as well as contact eczema and atopic dermatitis (14) were examined. The pattern of epidermal immunoreactivity correlated to the inflammatory state of the tissue with homogeneous epidermal staining in mildly inflamed tissue, whereas focal decrease or even total absence of epidermal staining was present in highly inflamed tissue. In those studies, single biopsies from different patients were taken at the time of admission to the hospital prior to any treatment and probably represented different stages of the disease (10).

In the present study, sequential biopsies from individual psoriatic lesions were examined following various treatment modalities. A gradual shift of IL-8 epidermal immunoreactivity was found which can be related to the duration of treatment and clinical improvement. There was no obvious influence of the type of antipsoriatic therapy. In addition to external steroids, dithranol and UV treatment as used in this study, similar results were found using topical calcitriol (20). In another study, the amount of IL-8 peptide in psoriatic lesions was found to decrease during calcipotriene treatment (21). These findings demonstrate that epidermal IL-8 immunoreactivity is in a dynamic state and further substantiate our previous data. Whereas decreased or even absent IL-8 immunoreactivity was found in skin specimens at the beginning of treatment, homogeneous epidermal staining was found upon clinical resolution of skin lesions. At that stage, immunoreactivity was comparable to normal or non-diseased skin (10).

Partly controversial results have been raised in studies of psoriatic tissue using immunohistochemical as well as probe-based methods. Whereas in one study IL-8 was undetectable

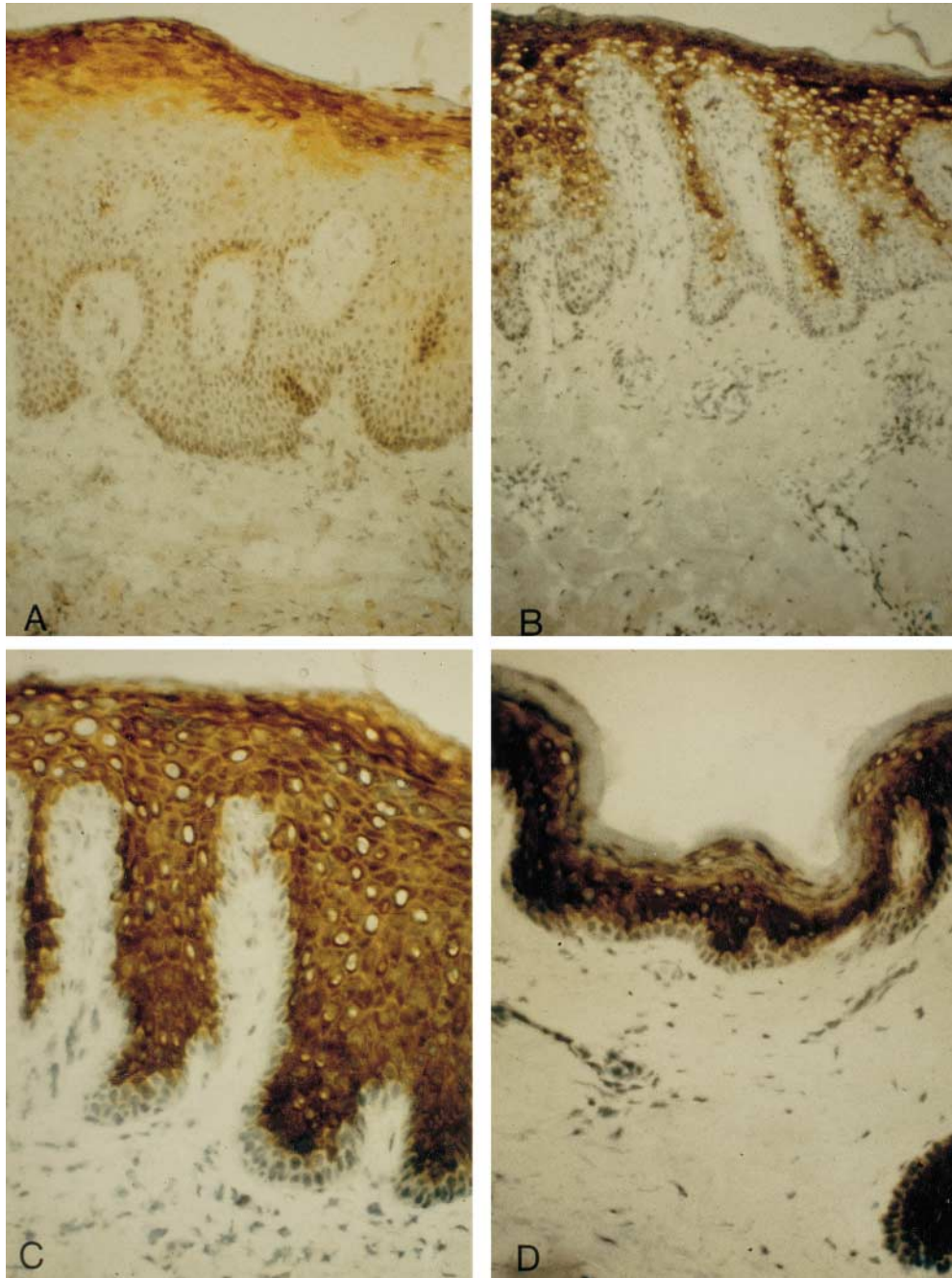


Fig. 3. Interleukin-8 immunoreactivity after staining with anti-IL-8 moab 52E8. Sequential biopsies from a patient with guttate psoriasis taken on the day of admission to hospital (A, 100 \times), and upon treatment with topical steroids and UVB-irradiation after 10 days (B, 100 \times), 25 days (C, 400 \times), 35 days (D, 200 \times) on discharge from hospital.

within normal epidermis (7), others were able to demonstrate a shift of IL-8 immunoreactivity from all epidermal layers as seen in normal skin towards upper layers in inflamed tissue (10, 11). Using probe-based methods, IL-8 mRNA has been found in suprabasal (9) or focally in upper cell layers between squirting papillae (8).

Similar to our results on IL-8, two other chemokines of the CXC family, MGSA/gro α (22) and IP-10 (23) could be demonstrated immunohistochemically in normal skin with a characteristic shift of immunoreactivity in psoriasis. Such results, as well as *in vitro* data of mitogenic activity on keratinocytes (24),

indicate that these chemokines as well as IL-8 play a role in normal epidermal growth and differentiation (4) and in inflammation.

In contrast to immunohistochemical results on local IL-8 expression, serum IL-8 levels did not correlate with severity of psoriasis and state of the disease as reflected by PASI. No correlation was found in any of four different IL-8 ELISA formats. In studies by various authors on IL-8 serum or plasma levels, a wide range of immunoassays with different mono- and polyclonal antibodies were used (2, 25). Differential reactivity of these antibodies (26) with IL-8 in dimerized form or

complexed with so-called natural anti-IL-8 antibody as described by Sylvester et al. (27) could explain diverging results. Accordingly, standardization was found to be a major problem in cytokine immunoassays, including those for IL-8, and different results were raised when studying the same samples in different assays (26–29).

Apart from these technical problems in cytokine detection, a number of mechanisms have recently been described which can bind and inactivate both circulating IL-8 and locally produced peptide. A promiscuous chemokine receptor has been found on the glycoprotein carrying the Duffy blood group antigen (30). It is expressed most abundantly on erythrocytes, but can be demonstrated on postcapillary venules as well (31). Most chemokines are bound with similar affinity, in contrast to other chemokine receptors which are much more discriminative (1, 2, 30). Furthermore, IL-8 is known to preferentially bind to heparin (2, 32). Consequently, glycosaminoglycans which are abundantly present in dermal connective tissue including skin vasculature are able to bind locally produced IL-8 (32, 33) and may thus prevent it from entering the circulation.

Furthermore, as mentioned above, so-called natural anti-IL-8 antibodies have been demonstrated in serum of healthy individuals (27). Similar to antibodies against IL-1, IL-6 and TNF α (34), these are assumed to both inactivate and store cytokines for ample response under inflammatory conditions. All these mechanisms represent potentially important control mechanisms of IL-8 which are produced either locally or systemically.

Recently, IL-8 levels were found to correlate to disease severity and prognosis in diseases like sepsis (2, 18). Massive production of IL-8 by circulating cells in these hyperinflammatory diseases is thought to overcome the inhibitory mechanisms described above (18). Regarding the size of the skin organ with abundant dermal tissue and vasculature, local binding mechanisms may be especially important in inflammatory diseases afflicting this organ. In fact, we could find similar results of low IL-8 levels and lacking correlation to disease severity in atopic eczema (own unpublished results).

Altogether, our study enforces earlier data that IL-8 is produced at local level to focus and amplify inflammatory responses. Evidently, however, these local processes are not reflected by the systemic IL-8 level even in cases of severely involved psoriatic skin. Consequently, serum IL-8 levels do not provide diagnostic or prognostic criteria in psoriasis.

ACKNOWLEDGMENT

This study was supported in part by Deutsche Forschungsgemeinschaft grants Sti 95/2-3 and Chr 38/7-2 (Clinical Research Group). We greatly appreciate the excellent technical work of Anke Rose and Nicole Plate.

REFERENCES

- Kunkel SL, Strieter RM, Lindley IJD, Westwick J. Chemokines: new ligands, receptors and activities. *Immunol Today* 1995; 16: 559–561.
- Baggiolini M, Dewald B, Moser B. Human chemokines: an update. *Annu Rev Immunol* 1997; 15: 675–705.
- Schröder J-M. Identification and structural characterization of chemokines in lesional material of patients with inflammatory skin diseases. *Methods Enzymol* 1997; 288: 266–297.
- Schröder J-M. Cytokine networks in the skin. *J Invest Dermatol* 1995; 105: 20S–24S.
- Schröder J-M, Christophers E. Identification of C5a_{desarg} and an anionic neutrophil-activating peptide (ANAP) in psoriatic scales. *J Invest Dermatol* 1986; 87: 53–58.
- Takematsu H, Tagami H. Quantification of chemotactic peptides (C5a anaphylatoxin and IL-8) in psoriatic lesional skin. *Arch Dermatol* 1993; 129: 74–80.
- Nickoloff BJ, Karabin GD, Barker JNWN, Griffiths CEM, Sarma V, Mitra RS, et al. Cellular localization of interleukin 8 and its inducer tumor necrosis factor alpha in psoriasis. *Am J Pathol* 1991; 138: 129–140.
- Gillitzer R, Berger R, Mielke V, Wolff K, Stingl G. Upper keratinocytes of psoriatic skin lesions express high levels of NAP-1/IL-8 mRNA in situ. *J Invest Dermatol* 1991; 97: 73–79.
- Schmid P, Cox D, McMaster GK, Itin P. In situ hybridization analysis of cytokine, proto-oncogene and tumor suppressor gene expression in psoriasis. *Arch Dermatol Res* 1993; 285: 334–340.
- Sticherling M, Bornscheuer E, Schröder J-M, Christophers E. Localization of NAP-1/IL-8 immunoreactivity in normal and psoriatic skin. *J Invest Dermatol* 1991; 96: 26–30.
- Antilla HSI, Reitamo S, Erkkö P, Ceska M, Moser B, Baggiolini M. Interleukin-8 immunoreactivity in the skin of healthy subjects and patients with palmoplantar pustulosis and psoriasis. *J Invest Dermatol* 1992; 98: 96–99.
- Fredriksson T, Pettersson U. Severe psoriasis – oral therapy with a new retinoid. *Dermatologica* 1978; 157: 238–244.
- Sticherling M, Hetzel F, Schröder J-M, Christophers E. Time- and stimulus-dependent secretion of NAP-1/IL-8 by human fibroblasts and endothelial cells. *J Invest Dermatol* 1993; 101: 573–576.
- Sticherling M, Bornscheuer E, Schröder J-M, Christophers E. Immunohistochemical studies on NAP-1/IL-8 in contact eczema and atopic dermatitis. *Arch Dermatol Res* 1992; 284: 82–85.
- Sticherling M, Schröder J-M, Christophers E. Production and characterization of monoclonal antibodies against the novel neutrophil activating peptide NAP-1/IL-8. *J Immunol* 1989; 143: 1628–1634.
- Sticherling M, Schröder J-M, Christophers E. Detection of NAP-1/IL-8 and related peptides from different sources by monoclonal antibodies. In: Oppenheim JJ, Powanda MC, Kluger MJ, Dinarello CA, eds. *Molecular and cellular biology of cytokines*. New York: Alan R. Liss, 1990: 339–344.
- Seitz M, Dewald B, Gerber N, Baggiolini M. Enhanced production of neutrophil-activating peptide-1/interleukin-8 in rheumatoid arthritis. *J Clin Invest* 1991; 87: 463–469.
- Biffl WL, Moore EE, Moore FA, Carl VS, Franciose RJ, Banerjee A. Interleukin-8 increases endothelial permeability independent of neutrophils. *J Trauma* 1995; 39: 98–102.
- Miller EJ, Cohen AB, Nagao S, Griffith D, Maunder RJ, Martin TR, et al. Elevated levels of NAP-1/IL-8 are present in the air-spaces of patients with the adult respiratory distress syndrome and are associated with increased mortality. *Am Rev Respir Dis* 1992; 146: 427–432.
- Reichrath J, Perez A, Müller SM, Chen TC, Kerber A, Bahmer FA, Holick MF. Topical calcitriol (1, 25-dihydroxyvitamin D₃) treatment of psoriasis: an immunohistochemical evaluation. *Acta Derm Venereol (Stockh)* 1997; 77: 268–272.
- Kang S, Yi S, Griffiths CEM, Fancher L, Hamilton TA, Choi JH. Calcipotriene-induced improvement in psoriasis is associated with reduced interleukin-8 and increased interleukin-10 levels within lesions. *Br J Dermatol* 1998; 138: 77–83.
- Nanney LB, Mueller SG, Bueno R, Peiper SC, Richmond A. Distribution of melanoma growth stimulatory activity of growth-related gene and the interleukin-8 receptor B in human wound repair. *Am J Pathol* 1995; 147: 1248–1260.
- Gottlieb AB, Luster AD, Posnett DN, Carter DM. Detection of a γ -interferon-induced protein IP-10 in psoriatic plaques. *J Exp Med* 1988; 168: 941–948.
- Tuschil A, Lam C, Haslberger A, Lindley I. Interleukin-8 stimu-

- lates calcium transients and promotes epidermal cell proliferation. *J Invest Dermatol* 1992; 99: 294–298.
25. Lemster BH, Carroll PB, Rilo HR, Johnson N, Nikaein A, Thomson AW. IL-8/IL-8 receptor expression in psoriasis and the response to systemic tacrolimus. *Clin Exp Immunol* 1995; 99: 148–154.
 26. Mire-Sluis AR, Gaines-Das R, Thorpe R, participants of the study. Implications for the assay and biological activity of interleukin-8: results of a WHO international collaborative study. *J Immunol Meth* 1997; 200: 1–16.
 27. Sylvester I, Yoshimura T, Sticherling M, Schröder J-M, Ceska M, Peichel P, Leonard EJ. Neutrophil attractant protein-1-immunoglobulin G immune complexes and free anti-NAP-1 antibody in normal human serum. *J Clin Invest* 1992; 90: 471–481.
 28. Mire-Sluis AR, Gaines-Das R, Thorpe R. Immunoassays for detecting cytokines: what are they really measuring? *J Immunol Meth* 1995; 186: 157–160.
 29. Ledur A, Fitting C, David B, Hamberger C, Cavaillon JM. Variable estimates of cytokine levels produced by commercial ELISA kits: results using international cytokine standards. *J Immunol Meth* 1995; 186: 171–179.
 30. Horuk R. The interleukin-8-receptor family: from chemokines to malaria. *Immunol Today* 1994; 15: 169–174.
 31. Hadley TJ, Lu ZH, Wasniowska K, Martin AW, Peiper SC, Hesselgesser J, Horuk R. Postcapillary venule endothelial cells in kidney express a multispecific chemokine receptor that is structurally and functionally identical to the erythroid isoform, which is the Duffy blood group antigen. *J Clin Invest* 1994; 94: 985–991.
 32. Rot A. Neutrophil attractant/activation protein-1 (interleukin 8) induces in vitro neutrophil migration by haptotactic mechanism. *Eur J Immunol* 1993; 23: 303–306.
 33. Hub E, Rot A. Binding of RANTES, MCP-1, MCP-3, and MIP-1 alpha to cells in human skin. *Am J Pathol* 1998; 152: 749–757.
 34. Bendtzen K, Svenson M, Jonsson V, Hippe E. Autoantibodies to cytokines – friends or foes? *Immunol Today* 1990; 11: 167–169.