

Immunohistochemical Detection of erbB-4 Expression in Extramammary Paget's Disease

Sir,

Extramammary Paget's disease occurs in the anogenital region, the axilla or, most commonly, the vulva (1). It occurs more frequently in women than in men and usually starts in the fifth decade or after. In a proportion of cases, an underlying sweat gland adenocarcinoma or a primary carcinoma of another organ, such as the rectum, urethra or cervix uteri, is found. However, in other cases it occurs primarily in the epidermis as carcinoma *in situ*. A number of studies have shown that amplification of the c-erbB-2 gene occurs frequently in various human tumours, such as breast cancer (2) and salivary gland adenocarcinoma (3), and is usually associated with a poor prognosis. Expression of c-erbB-2 was also examined and an intense membrane staining was observed in the intra-epidermal Paget cells of mammary and extramammary Paget's diseases (4–6). The erbB-4 gene encodes a 180 kDa transmembrane tyrosine kinase, the cytoplasmic kinase domain of which exhibits 79% and 77% identity with epidermal growth factor receptor and c-erbB-2, respectively (7). Expression of erbB-4 is observed at the highest levels in breast carcinoma cell lines, normal skeletal muscle, heart and brain (7). To examine whether erbB-4 is expressed in tumour cells of extramammary Paget's disease, we performed immunohistochemical staining of erbB-4 protein using the anti-erbB-4 polyclonal antibody.

MATERIALS AND METHODS

A total of 9 cases of extramammary Paget's disease were collected from the pathology files of the Department of Dermatology at Tsukuba University Hospital. The clinical characteristics of these cases are described in Table I. Formalin-fixed, paraffin-embedded tissue specimens from these patients were cut into 5 µm thick sections and deparaffinized. The sections were incubated in hydrogen peroxide to block any endogenous peroxidase activity. After blocking with normal goat serum, the sections were incubated with rabbit polyclonal antibody to human erbB-4 (C-18, Santa Cruz, CA, USA) at a concentration of 1 µg/ml. The sections were subsequently treated with secondary antibody using the VECTASTAIN ABC-Peroxidase kit (Vector, CA, USA) followed by staining with the Vector VIP peroxidase substrate (Vector, CA, USA), and were then counter-stained with methyl green.

RESULTS AND DISCUSSION

The results are shown in Table I. All cases except one (case 3) were negative for erbB-4 staining. The positive staining

Table I. Clinical characteristics of extramammary Paget's disease patients

Number	Age (years)/sex	Type of carcinoma	Lymph node swelling	erbB-4 staining
1	92/M	<i>in situ</i>	negative	negative
2	74/M	<i>in situ</i>	negative	negative
3	78/F	<i>in situ</i>	negative	positive
4	37/F	<i>in situ</i>	negative	negative
5	67/M	<i>in situ</i>	negative	negative
6	52/M	<i>in situ</i>	negative	negative
7	79/F	invasive	negative	negative
8	75/F	invasive	positive	negative
9	59/M	invasive	positive	negative

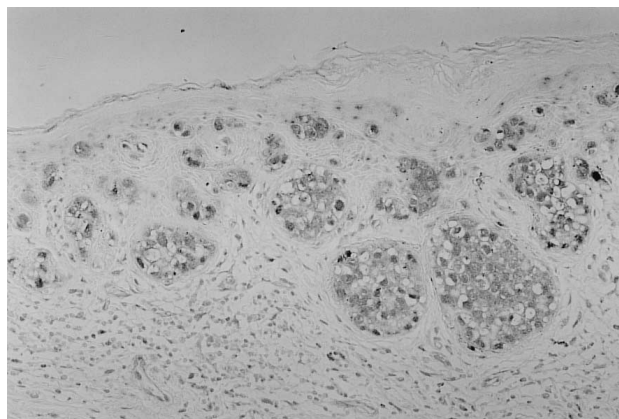


Fig. 1. Immunohistochemical staining of erbB-4 in extramammary Paget's disease. Tumour cells of case 3 stained positive for erbB-4. Magnification $\times 50$.

observed in tumour cells of case 3 is shown in Fig. 1. Because case 3 stayed in the non-invasive stage of extramammary Paget's disease, it seems unlikely that erbB-4 positivity in tumour cells of extramammary Paget's disease correlates with a poor prognosis. Although overexpression of c-erbB-2 is relatively common in extramammary Paget's disease (6) and amplification of the c-erbB-2 gene in breast cancer (2) is usually associated with a poor prognosis, it does not appear that erbB-4 expression is common in extramammary Paget's disease, or that its expression is associated with any prognosis.

REFERENCES

- MacKie RM. Extramammary Paget's disease. In: Champion RH, Burton JL, Ebling FJG, eds. Textbook of dermatology. 5th edn, Vol. 2. Oxford: Blackwell Scientific Publication, 1992: 1487–1488.
- Slamon DJ, Clark GM, Wong SG, et al. Human breast cancer: correlation of relapse and survival with amplification of the HER-2/neu oncogene. *Science* 1987; 235: 177–182.
- Semba K, Kamata K, Toyoshima K, et al. A v-erbB-related proto-oncogene, c-erbB-2, is distinct from the c-erbB-1/epidermal growth factor-receptor gene and is amplified in a human salivary gland adenocarcinoma. *Proc Natl Acad Sci USA* 1985; 82: 6497–6501.
- Wolber RA, Dupuis BA, Wick MR. Expression of C-erbB-2 oncoprotein in mammary and extramammary Paget's disease. *Am J Clin Pathol* 1991; 96: 243–247.
- Tokuhashi I, Hashizume S, Takakuwa T. An immunohistochemical study of the expression of p53 and C-erbB-2 in mammary Paget's disease. *Nishinohon J Dermatol* 1995; 57: 281–285.
- Takata M, Hatta N, Takehara K. Tumor cells of extramammary Paget's disease do not show either p53 mutation or allelic loss at several selected loci implicated in other cancers. *Br J Cancer* 1997; 76: 904–908.
- Plowman GD, Couloucou J, Whitney GS, et al. Ligand-specific activation of HER4/p180^{erbB4}, a fourth member of the epidermal growth factor receptor family. *Proc Natl Acad Sci USA* 1993; 90: 1746–1750.

Accepted September 7, 1998.

Sumihisa Imakado, Hisae Satomi and Fujio Otsuka
Department of Dermatology, Institute of Clinical Medicine, University of Tsukuba 1-1 Ten-nodai, Tsukuba, Ibaraki 305-8575, Japan,
E-mail: simakado@md.tsukuba.ac.jp.