

# Proliferation is the Main Epidermal Target in the Treatment of Psoriatic Plaques with Once Daily Application of Tacalcitol Ointment

FRANSJE A. C. M. CASTELIJNS, MARIE-JEANNE P. GERRITSEN, IVONNE M. J. J. VAN VLIJMEN-WILLEMS, PIET J. VAN ERP and PETER C. M. VAN DE KERKHOF

*Department of Dermatology, University Hospital Nijmegen, Nijmegen, The Netherlands*

**We studied the effect of tacalcitol (1 $\alpha$ ,24 dihydroxy vitamin D3) ointment on clinical and immunohistochemical efficacy in psoriatic patients during 2 months of treatment. The psoriasis area and severity index decreased significantly after only 1 month and the total body surface index decreased 55% after 2 months. To characterize the epidermal compartment keratin 14, keratin 16, epidermal growth factor receptor, apoptotic and Ki-67 positive cells were examined. After 1 week of treatment no significant changes were found in any of these parameters. After 2 months, keratin 16 reached the levels observed in normal skin and Ki-67 and keratin 14 expression also reduced significantly. Epidermal growth factor receptor staining and the number of apoptotic cells did not alter during treatment. We conclude that tacalcitol is effective in the treatment of plaque psoriasis. Because the main epidermal effect observed immunohistochemically is a reduction in proliferation, a combination therapy using either corticosteroids, vitamin A derivatives or dithranol seems rational. *Key words: psoriasis; epidermis; vitamin D3; immunohistochemistry.***

(Accepted September 23, 1998.)

Acta Derm Venereol (Stockh) 1999; 79: 111–114.

F. A. C. M. Castelijns, Department of Dermatology, University Hospital of Nijmegen, PO Box 9101, NL-6500 HB Nijmegen, The Netherlands. Email: F.Castelijns@derma.azn.nl.

Tacalcitol, 1 $\alpha$ ,24-dihydroxyvitamin D3 has a well-established efficacy in the treatment of psoriasis (1, 2). The recruitment of cycling epidermal cells is profoundly inhibited by tacalcitol and hyperproliferation-associated keratin 16 is markedly reduced during tacalcitol treatment (3). The inhibitory effect of tacalcitol on epidermal proliferation has also been substantiated by measurement of DNA content using flow cytometry (4, 5). Involucrin, filaggrin and transglutaminase are also modulated during tacalcitol treatment, indicating that tacalcitol has an effect on various phases of epidermal differentiation (3, 6). An *in vitro* study indicated that active vitamin D3 enhances apoptosis (7).

The aim of the present study was to evaluate the effect of tacalcitol on various characteristics of the epidermis during treatment of the psoriatic plaque. In particular we addressed the following questions: to what extent are markers for early phenomena of psoriasis (epidermal growth factor receptor (EGFR), keratin 16), for intermediate phenomena (Ki-67 antigen) and for late phenomena of psoriasis (keratin 14) affected by tacalcitol treatment? And, does tacalcitol treatment result in enhanced apoptosis?

## MATERIALS AND METHODS

Eleven patients (between 25 and 63 years of age, mean age 41.3 years) with moderately extensive plaque psoriasis (the area of affected skin being 7–20% of total body area) participated in a long-term safety and efficacy study after they had signed informed consent. Before inclusion, they had received no topical treatment for at least 2 weeks, no oral retinoid treatment for at least 1 year and no PUVA or other systemic therapy for at least 6 weeks. At baseline, after 1 week and after 2 months of treatment 4 mm punch biopsies were taken from 9 out of 11 patients. Clinical improvement was assessed by Psoriasis Area and Severity Index (PASI), including scores for erythema, induration, scaling on a 5-point scale (8) and total body surface involvement (TBSI). Blood (routine biochemistry, haematological investigations, parameters for calcium/phosphorus metabolism and parathyroid hormone) and 24 h urine samples were taken at screening and at monthly intervals. A maximum of 56 g of ointment per week was allowed.

### *Monoclonal antibodies*

To characterize the epidermal phenotype the following monoclonal antibodies were used: LL002 (1:50, Novocastra Lab. Ltd, Newcastle-upon-Tyne, UK) (9, 10) recognizing keratin 14, which is synthesized exclusively in the basal layer of normal epidermis (11, 12); LL025 (1:10, Novocastra Lab. Ltd) recognizing keratin 16. This intermediate filament is absent in normal differentiated skin, but is regarded as a stress marker and is expressed in the suprabasal layers of hyperproliferative disorders (10, 13); EGFR-Abl (1:40, Oncogene Research Products, Cambridge, UK) to visualize the epidermal growth factor receptor. This receptor is able to bind epidermal growth factor and transforming growth factor  $\alpha$ . Both ligands affect proliferation and differentiation of the epidermis (14, 15); and MIB-1 (1:50, Immunotech, SA, Marseilles, France) recognizing the Ki-67 antigen which is expressed in cells in late G<sub>1</sub>, S or G<sub>2</sub>M phase (16).

### *Sample procedures*

Biopsies were fixed in formalin for 4 h, and embedded in paraffin. Sections (6  $\mu$ m thick) were cut on slides coated with 3-aminopropyltriethoxysilane (Sigma Chemicals, St Louis, MO, USA). Sections were dewaxed in histosafe, rehydrated by dipping in a series of graded ethanol from 100% to 50%, ending in demineralized water.

### *Immunohistochemical staining method*

To demask the epitopes that the antibodies are able to recognize, the following set of pre-treatments was necessary: LL002 staining only required incubation in 10 mM citrate buffer (pH=6.0) for 45 min; LL025 and MIB-1 staining needed a high temperature microwave antigen retrieval technique (according to Cattoretti et al. (16)). In brief: 10 mM citrate buffer (pH=6.0) was heated to boiling point in a microwave oven (760 W). Subsequently sections were heated twice in this buffer at 480 W for 5 min (boiling was prevented) and slowly (at least 45 min) cooled down to room temperature; and EGFR-Abl needed trypsin pre-treatment for 15 min followed by the addition of heat inactivated normal calf serum at room temperature for 3 min as a blocker.

### *Staining procedure*

An indirect immunoperoxidase technique was used for all antibodies: slides were incubated with 20% normal horse serum (Vector

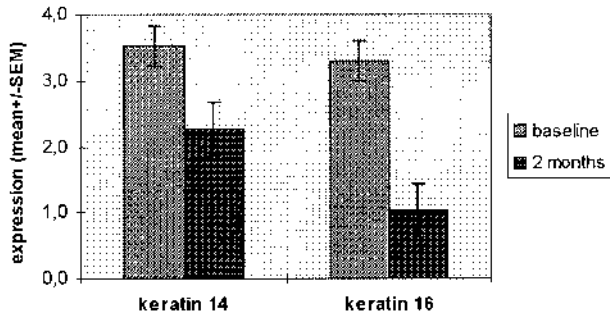


Fig. 1. Keratin 14 and keratin 16 expression at baseline and after 2 months of tacalcitol treatment (mean  $\pm$  SEM).

laboratories Inc., Burlingame, USA) (15 min), followed by incubation with the primary antibody (diluted in 1% bovine serum albumin (Organon Technika BV, Boxtel, The Netherlands)/PBS) for 1 h. Sections were washed in PBS for 10 min. Secondary horse anti-mouse biotinylated IgG antibody (ABC kit-mouse, Vector Laboratories Inc., Burlingame, USA) (dilution 1:200 in 1% BSA/PBS) was added for 30 min, and again a 10 min wash in PBS was regarded. Sections were treated with avidin-biotin complex (ABC kit-mouse, Vector Laboratories

Inc., Burlingame, USA) (avidin/biotin diluted 1:50 in 1% BSA/PBS) for 30 min. Slides were rinsed in PBS (10 min). To visualize staining of LL002, LL025 and EGFR-Ab1 diaminobenzidine (Pierce Inc., Rockford, USA), and for MIB-1 staining 3-amino-9-ethylcarbazole (AEC, Calbiochem-Novabiochem Corporation, San Diego, CA, USA) was used. Counterstaining was performed with Mayer's Haematoxylin (Sigma Chemicals, St. Louis, MO, USA). MIB-1 sections were mounted in glycerol gelatine (Sigma Diagnostics, St. Louis, MO, USA), LL002 - LL025 and EGFR-Ab1 in permount (Fisher Chemical, Fair Lawn, NJ, USA).

*Tdt-mediated unscheduled nick end labelling (TUNEL)*

This technique, first described by Gavrieli et al. (17), can be performed to visualize apoptotic cells on paraffin sections. As positive control we assessed a biopsy taken from normal skin 48 h after irradiation with 2 MED UVB phototherapy.

*Immunohistochemical scoring*

Semiquantitative scores (0-4) were used for the antibodies LL002 - LL025 and EGFR-Ab1. Ki-67-antigen and TUNEL positive cells were counted per millimetre length of section. Of every section 3 fields of 1 mm were scored or counted, and we calculated mean  $\pm$  SEM.

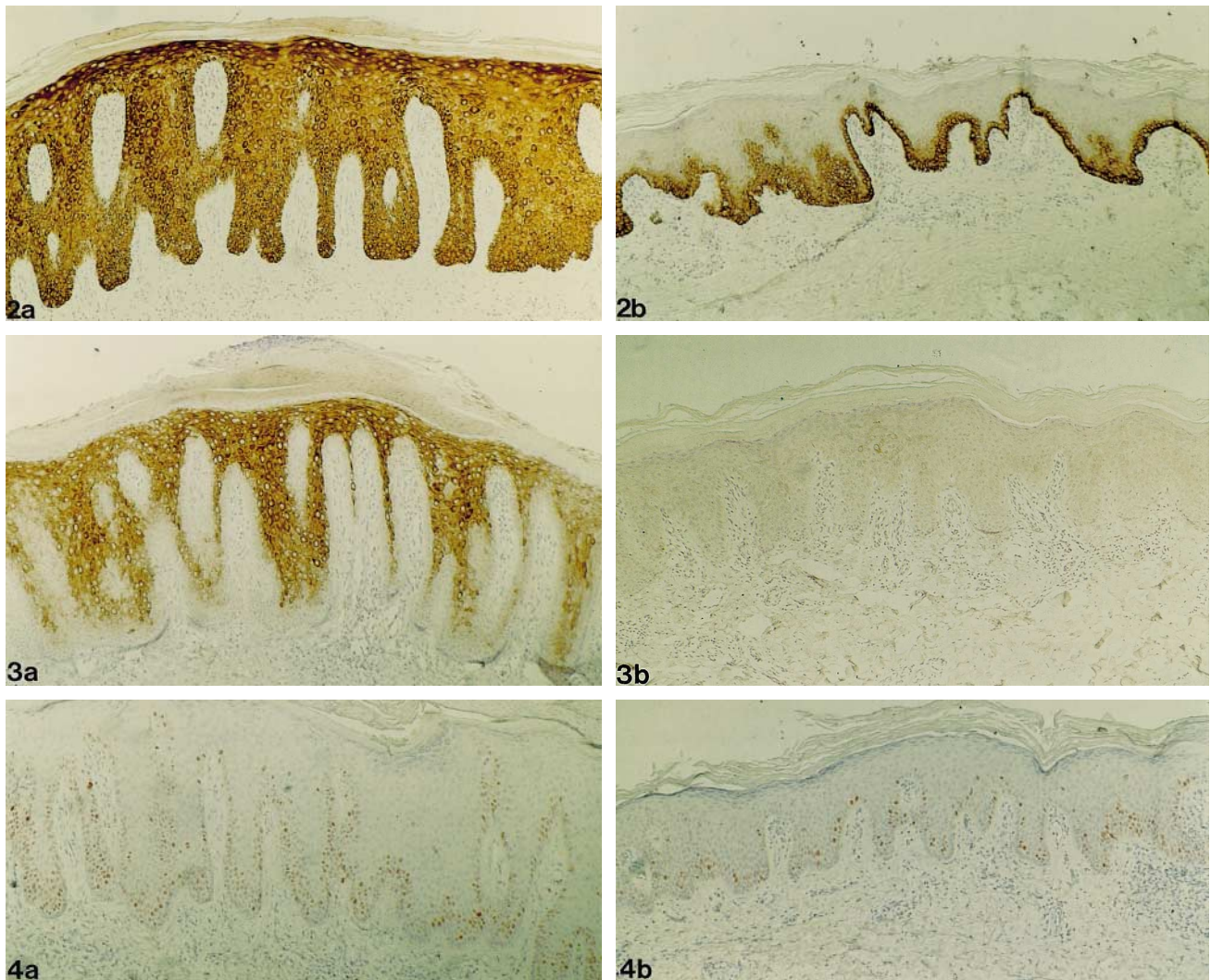


Fig. 2a and b: Keratin 14; 3a and b: keratin 16; and 4a and b: Ki-67 expression. (a) At baseline and (b) after 2 months of treatment. Magnification  $\times$  200.

### Statistical analysis

PASI and percentage of TBSI were compared at screening, baseline, 1 and 2 months after treatment. Immunohistochemical scores were compared at baseline and after 1 week and 2 months of treatment. The one-way ANOVA test and the Duncan test were used to interpret the data.

## RESULTS

### Clinical response

Out of 11 patients, 1 dropped out after the screening visit due to liver function abnormalities. At the screening and baseline visits the mean PASI (13.6 and 14.5) and the percentage of area involved (10.4 and 10.6) were similar. Compared with baseline, after 1 and 2 months PASI decreased significantly to 7.5 ( $p < 0.0003$ ) and 4.8 ( $p < 0.0001$ ), respectively. TBSI showed a significant decrease as late as after 2 months (5.8,  $p < 0.001$ ). A marked effect of tacalcitol was observed in the patient having the most extensive and severe psoriasis (TBSI of 20% and PASI 24.4); he reached clearance after 2 months. Blood investigations did not reveal any abnormality. Irritation was not encountered in any patient during treatment.

### Immunohistochemical results of 9 patients

**Keratin 14 (Fig. 1).** Normal skin shows no suprabasal staining but a continuous expression of keratin 14 in the basal compartment. This intermediate filament was seen throughout the whole epidermis in all samples of psoriatic skin (Fig. 2a), after one week some slides showed some spots with less keratin 14 expression. After 2 months' treatment in all patients less than 50% of the suprabasal layers were keratin 14-positive (Fig. 2b) ( $p < 0.001$ ).

**Keratin 16 (Fig. 1).** This filament, which is absent in normal skin, was seen abundantly throughout the suprabasal layers of the psoriatic skin (Fig. 3a) before and after 1 week of therapy. After 2 months' treatment no keratin 16 could be seen in most patients (Fig. 3b), only a few showed a spotty sporadic to minimal staining pattern ( $p < 0.0001$ ).

**Ki-67 antigen.** The counts of cycling cells in psoriatic skin ( $178 \pm 33$  positive cells per mm) had decreased significantly after 2 months of treatment ( $99 \pm 25$ ,  $p < 0.02$ ) (Fig. 4a–b). At baseline and after 1 week the amount of Ki-67 positive cells was equal. Cycling cells were mostly located in the first layers of the suprabasal compartment.

**EGFR.** Normal skin shows a more pronounced staining of the basal compartment, while staining weakens in the more suprabasal layers. In the psoriatic skin the expression of this receptor was seen throughout the entire epidermis (in the upper suprabasal areas, expression was somewhat weaker). The same pattern was seen at baseline, and after 1 week and 2 months of treatment.

**Apoptosis.** In psoriatic skin only 1–4 positive TUNEL cells were detectable in the epidermis of a section. In some patients, the infiltrate (presumably T-cells) in the dermis showed some more TUNEL positive cells. No significant changes were noted during the treatment.

## DISCUSSION

The suprabasal compartment has been reported to be involved relatively early in the development of the psoriatic lesion (18,

21). In an initial stage of the lesion, epidermal markers showed individual dynamics: expression of epidermal growth factor receptor (EGFR) and keratin 16 occurs relatively early, followed by Ki-67 expression, whereas keratin 14 expression is a relatively late marker (personal observations).

As we show in this study, in the healing of psoriatic plaques during tacalcitol treatment remarkable observations are the consistent patterns of decreasing Ki-67 antigen, keratin 14 and keratin 16 expression, whereas EGFR density did not show any change.

The decrease in Ki-67 positive nuclei by 44% during 2 months' treatment is in line with the reduction in the proliferative fraction documented in earlier flow cytometric reports (4, 5). The improvement is not seen after 1 week of treatment, which is consistent with an earlier study on calcipotriol treatment (22).

Keratin 14 expression showed a similar response pattern to the number of Ki-67 nuclei, namely a decrease in the number of positive cells. A possible mechanism to explain this phenomenon is the high turnover of cells in the psoriatic epidermis. Keratin 14 mRNA is still limited to the basal layer in psoriatic epidermis; however keratin 14 protein must be down-regulated, and in a hyperproliferative status such as psoriasis this can not be done fast enough to prevent expression suprabasally. As turnover time falls in the healing of psoriatic skin (with a decrease in Ki-67 antigen positive cells), keratin 14 protein also has time to be degraded.

Keratin 16 reached levels seen in normal skin in our study. Gerritsen et al. (3) also showed a reduction, but no normalization of keratin 16 expression in an identical study design. Potent topical corticosteroids can markedly reduce the number of keratin 16 and Ki-67 positive cells (23).

The expression of EGFR positive cells was not affected by tacalcitol treatment. During PUVA treatment persistence in EGFR density has been reported (24). Immunohistochemically it is not possible to show whether the receptor is or has become inactivated due to treatment or whether its affinity has changed (radioactive binding studies would be needed).  $1\alpha,25(\text{OH})_2$  vitD3 can lower the high affinity EGFRs but the total number of EGFRs remains the same, suggesting modulation of EGF binding (25). In the healing of a psoriatic plaque after dithranol (26), retinoid (27) and a potent corticosteroid under hydrocolloid occlusion therapy (personal observations), EGFR expression is comparable to that seen in normal skin. So, persistence of EGFR binding implies incomplete healing of the psoriatic plaque and combination treatment of tacalcitol with dithranol, topical retinoids or topical corticosteroids might enhance the efficacy of tacalcitol.

In contrast to the reported *in vitro* effect of vitamin D3 on apoptosis (7), (calcipotriol being a weak inducer of apoptosis), the present *in vivo* study failed to demonstrate apoptosis during tacalcitol treatment. Lately doubt has risen as to the value of the TUNEL staining: Wrona Smith et al. (28) have shown that the TUNEL positive-stained cells of psoriatic skin are in high amounts also positive for Ki-67 and proliferating cell nuclear antigen (as mentioned earlier, markers for cell proliferation) and concluded that psoriatic plaques are resistant to apoptosis compared with normal skin. Further experiments are needed to explore these findings. The *in vivo* bio-availability of the ointment might have been insufficient to cause apoptosis and perhaps adjustment of the time of biopsy is also required. Other methods, such as flow cytometric double staining techniques,

might be required to confirm whether apoptosis is not an *in vivo* effect of tacalcitol.

#### ACKNOWLEDGEMENTS

The authors thank Hermal for support during this study, M. Kooymans-Otero for assistance at the out-clinic department and G. de Jongh for statistical analysis.

#### REFERENCES

- van de Kerkhof PCM, Werfel T, Hausteil UF, Luger T, Czarnetzki BM, Niemann R, et al. Tacalcitol ointment in the treatment of psoriasis vulgaris: a multicentre, placebo-controlled, double-blind study on efficacy and safety. *Br J Dermatol* 1996; 135: 758–765.
- Veien NK, Bjerke JR, Rossmann Ringdahl I, Jakobsen HB. Once daily treatment of psoriasis with tacalcitol compared with twice daily treatment with calcipotriol. A double-blind trial. *Br J Dermatol* 1997; 137: 581–586.
- Gerritsen MJP, Boezeman JBM, van Vlijmen-Willems IMJJ, van de Kerkhof PCM. The effect of tacalcitol (1, 24(OH)2D3) on cutaneous inflammation, epidermal proliferation and keratinization in psoriasis: a placebo-controlled, double-blind study. *Br J Dermatol* 1994; 131: 57–63.
- Glade CP, van Erp PEJ, van Hooijdonk CAEM, Elbers ME, van de Kerkhof PCM. Topical treatment of psoriatic plaques with 1 alpha,24 dihydroxyvitamin D3: a multiparameter flow cytometrical analysis of epidermal growth, differentiation and inflammation. *Acta Derm Venereol (Stockh)* 1995; 75: 381–385.
- Mommers JM, Castelijns FACM, Seegers BAMP, van Rossum MM, van Hooijdonk CAEM, van Erp PEJ, et al. The effect of long-term treatment with tacalcitol on the psoriatic epidermis. A flow cytometric analysis. *Br J Dermatol* 1998; 139: 468–471.
- Gerritsen MJP, van Erp PEJ, van de Kerkhof PCM. Transglutaminase-positive cells in psoriatic epidermis during treatment with calcitriol (1alpha,25 dihydroxy vitamin D3) and tacalcitol (1alpha,24 dihydroxy vitamin D3). *Br J Dermatol* 1995; 133: 656–659.
- Baudet C, Chevalier G, Naveilhan P, Binderup L, Brachet P, Wion D. Cytotoxic effects of 1alpha,25-dihydroxyvitamin D3 and synthetic vitamin D3 analogues on a glioma cell line. *Cancer Letters* 1996; 100: 3–10.
- Fredriksson T, Petterson U. Severe psoriasis – oral therapy with a new retinoid. *Dermatologica* 1978; 157: 238–244.
- Purkis PE, Steel JB, Mackenzie IC, Nathrath WB, Leigh IM, Lane EB. Antibody markers of basal cells in complex epithelia. *J Cell Sci* 1990; 97: 39–50.
- Perkins W, Campbell I, Leigh IM, MacKie RM. Keratin expression in normal skin and epidermal neoplasms demonstrated by a panel of monoclonal antibodies. *J Cutan Pathol* 1992; 19: 476–482.
- Markey AC, Lane EB, Macdonald DM, Leigh IM. Keratin expression in basal cell carcinomas. *Br J Dermatol* 1992; 126: 154–160.
- Stoler A, Kopan R, Duvic M, Fuchs E. Use of monospecific antisera and cRNA probes to localize the major changes in keratin expression during normal and abnormal epidermal differentiation. *J Cell Biol* 1988; 107: 427–446.
- Leigh IM, Navsaria H, Purkis PE, McKay IA, Bowden PE, Riddle PN. Keratins (K16 and K17) as markers of keratinocyte hyperproliferation in psoriasis *in vivo* and *in vitro*. *Br J Dermatol* 1995; 133: 501–511.
- King LE Jr, Gates RE, Stoscheck CM, Nanney LB. Epidermal growth factor/transforming growth factor alpha receptors and psoriasis. *J Invest Dermatol* 1990; 95: 10S–12S.
- King LE Jr, Gates RE, Stoscheck CM, Nanney LB. The EGF/TGF alpha receptor in skin. *J Invest Dermatol* 1990; 94: 164S–170S.
- Cattoretti G, Becker MHG, Key G, Duchrow M, Schluter C, Galle J, et al. Monoclonal antibodies against recombinant parts of the Ki-67 antigen (MIB1 and MIB3) detect proliferating cells in microwave-processed formalin-fixed paraffin sections. *J Pathol* 1992; 168: 357–363.
- Gavrieli Y, Sherman Y, Ben-Sasson SA. Identification of programmed cell death *in situ* via specific labeling of nuclear DNA fragmentation. *J Cell Biol* 1992; 119: 493–501.
- de Mare S, de Jong EMG, van Erp PEJ, van de Kerkhof PCM. Markers for proliferation and keratinization in the margin of the active psoriatic lesion. *Br J Dermatol* 1990; 122: 469–475.
- de Jong EMG, Schalkwijk J, van de Kerkhof PCM. Epidermal proliferation and differentiation, composition of the inflammatory infiltrate and the extracellular matrix in the margin of the spreading psoriatic lesion. *Eur J Dermatol* 1991; 1: 221–227.
- Braun Falco O, Christophers E. Structural aspects of initial psoriatic lesions. *Arch Dermatol Forsch* 1974; 251: 95–110.
- Soltani K, Van Scott EJ. Patterns and sequence of tissue changes in incipient and evolving lesions of psoriasis. *Arch Dermatol* 1972; 106: 484–490.
- de Jong EMG, van de Kerkhof PCM. Simultaneous assessment of inflammation and epidermal proliferation in psoriatic plaques during long-term treatment with the vitamin D3 analogue MC903: modulations and interrelations. *Br J Dermatol* 1991; 124: 221–229.
- de Jong EMG, Ferrier CM, de Zwart A, Wauben Penris PJ, Korstanje C, van de Kerkhof PCM. Effects of topical treatment with budesonide on parameters for epidermal proliferation, keratinization and inflammation in psoriasis. *J Dermatol Sci* 1995; 9: 185–194.
- Vallat VP, Gilleaudeau P, Battat L, Wolfe J, Nabeya R, Heftler N, et al. PUVA bath therapy strongly suppresses immunological and epidermal activation in psoriasis: a possible cellular basis for remittive therapy. *J Exp Med* 1994; 180: 283–296.
- Hashimoto K, Matsumoto K, Higashiyama M, Iwasa M, Hashiro M, Ueda K, et al. 1alpha,25-dihydroxyvitamin D3 inhibits cell growth and decreases high-affinity receptors for EGF in human keratinocytes derived from psoriatic lesions. *J Invest Dermatol* 1989; 92: 440.
- Kemeny L, Michel G, Arenberger P, Ruzicka T. Down-regulation of epidermal growth factor receptors by dithranol. *Acta Derm Venereol (Stockh)* 1993; 73: 37–40.
- Esgleyes Ribot T, Chandraratna RA, Lew Kaya DA, Sefton J, Duvic M. Response of psoriasis to a new topical retinoid, AGN 190168. *J Am Acad Dermatol* 1994; 30: 581–590.
- Wrone Smith T, Mitra RS, Thompson CB, Jasty R, Castle VP, Nickoloff BJ. Keratinocytes derived from psoriatic plaques are resistant to apoptosis compared with normal skin. *Am J Pathol* 1997; 151: 1321–1329.