

Angiosarcoma of the Lower Leg in Chronic Lymphoedema

Sir

Angiosarcomas (AS) are rare malignant neoplasms of mesenchymal origin that exhibit vascular differentiation. They mainly affect adult men. They account for approximately 1% of all sarcomas and 35% primarily affect the skin, usually on the head and neck (1). Ten percent of angiosarcomas develop in chronic lymphoedema (2). Some are associated with lymphoedema due to conditions such as trauma, congenital factors, post-surgical lymphatic obstructions, filariasis and idiopathic causes (3).

CASE REPORT

A 76-year-old man was referred to us with multiple lesions on the right lower limb. Physical examination revealed several purple-bluish, firm angiomatoid nodules, 1–3 cm in diameter, centrally confluent in a vast polypous plaque of 8 × 5 cm, localized on the mid-part of the antero-medial area of the thigh (Fig. 1). At the periphery of the mass, scattered on the thigh, were several smaller purplish coloured, hard papules and nodules. Past medical history revealed that 10 years previously the patient had undergone a surgical operation for radical cystectomy and bilateral inguinal lymphadenectomy for a carcinoma of the bladder, after which moderate chronic lymphoedema of the lower limb had developed. Histopathology of a biopsy performed on the central plaque showed hyperplasia of the rete ridges and proliferation of neoplastic cells in the superficial and deep dermis; several dilated, irregularly shaped vascular channels were visible, resembling angiomatoid proliferation. The vascular spaces were lined by atypical endothelial cells forming papillary tufts in the lumina. Cellular atypia and several mitoses were observed. Immunohistochemistry revealed expression on the neoplastic cells of endothelial markers, such as factor VIII related antigen, UEA-1 lectin, CD31, CD34 (Fig. 2). Magnetic resonance imaging of the right thigh showed diffuse and marked thickening of the subcutis, where many thin and serpiginous structures resembling vasoformative growth were evident. The mass was close to the muscle fascia, but did not infiltrate it. Even though the lesions were rapidly growing, the patient refused radical surgery, so palliative removal of the central plaque was performed, followed by chemotherapy with Epirubicin (60 mg/m² body surface) and Dacarbazine (400 mg/day). In a few weeks the lesions extended to the whole limb and

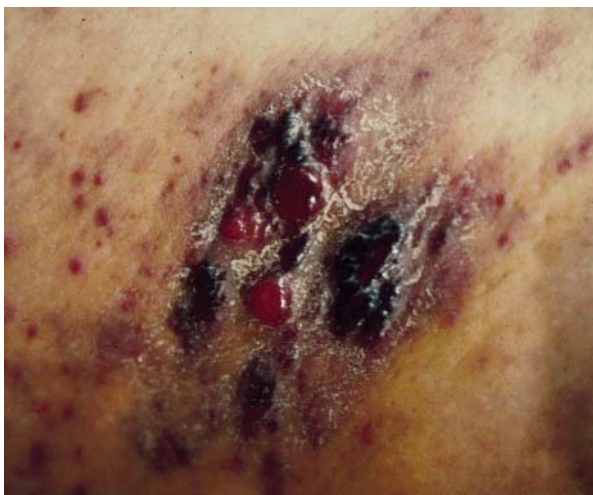

Fig. 1. Several nodules purple-bluish and firm angiomatoid, centrally confluent in a vast polypous plaque.

the patient died with peritoneal carcinosis and neoplastic wasting 6 months after diagnosis.

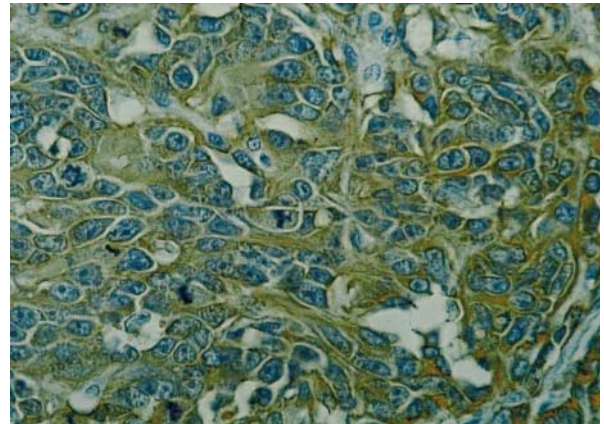


Fig. 2. Neoplastic cells stained with the endothelial markers (CD31 × 400).

DISCUSSION

The neoplasm is usually poorly circumscribed, multifocal and diffusely infiltrating; progression is rapid with loco-regional and distant metastases through blood and lymphatic spread. Prognosis is poor with an average survival of approximately 20 months. However, there are some favourable prognostic factors, such as small size of the tumour at the time of diagnosis and the presence of a marked lymphocytic infiltrate at the periphery of the tumour mass (4).

Histopathology is similar in the different subclasses and it is variable, ranging from well-differentiated forms with a benign aspect to highly undifferentiated forms as the epithelioid or metastatic-like type that require immunohistochemistry and electron microscopy for identification. Surgical excision with wide safety margins is complicated in cases of multiple neoplasm and in sites such as the face and the scalp (4). In Stewart-Treves syndrome the amputation of the affected limb is the therapy of choice for early lesions. Many different therapeutic approaches, such as chemotherapy and radiotherapy have been tried for the late stages, with disappointing results. However, immunotherapy with IFN γ , IL2 and TIL have shown encouraging results (5–6).

REFERENCES

1. Mark RJ, Tran LM, Sercarz J, Fu YS, Calcaterra TC, Juillard GF. Angiosarcoma of the head and neck. The UCLA experience 1955 through 1990. *Arch Otolaryngol Head Neck Surg* 1993; 119: 973–978.
2. Stewart FW, Treves N. Lymphangiosarcoma in postmastectomy lymphedema: a report of six cases in elephantiasis chirurgica. *Cancer* 1948; 1: 64–81.
3. Hultberg BM. Angiosarcoma in chronically lymphedematous extremities. Two cases of Stewart-Treves syndrome. *Am J Dermatopathol* 1987; 9: 406–412.

4. Maddox JC, Evans HL. Angiosarcoma of the skin and soft tissue: a study of forty-four cases. *Cancer* 1981; 44: 1907–1921.
5. Masuzawa M, Higashi K, Nishioka K, Nishiyama S. Successful immunotherapy for malignant hemangioendothelioma using recombinant interleukin-2. *Jpn J Dermatol* 1988; 98: 367–369.
6. Furue M, Yamada N, Takahashi T, Kikuchi K, Tsuchida T, Ishibashi Y, et al. Immunotherapy for Stewart-Treves syndrome. *J Am Acad Dermatol* 1994; 30: 899–903.

Accepted November 29, 1998.

V. Simonetti, M. Folgaresi and A. Motolese
Department of Dermatology, University of Modena, Via del Pozzo 71,
IT-41100, Modena, Italy. E-mail: segdermo@unimo.it.

Fournier's Gangrene: a Case Report

Sir,

Fournier's gangrene is a rare necrotizing fasciitis of the genitalia, characterized by acute onset in healthy young males and by rapid progression (1). At present, its cause is ascribed to a synergistic polymicrobial infection. Individuals suffering from diabetes and chronic alcoholism are mainly affected, and the disease appears to have a mechanism connected with hypersensitivity, like Shwartzman phenomenon (2).

CASE REPORT

A 52-year-old debilitated alcoholic man with cirrhosis following hepatitis C infection and hypersplenism was referred to us by a surgeon for massive swelling and erythema with skin necrosis localized in the right thigh, hip, groin and genitalia (Fig. 1). There was no scrotal or inguinal crepitus. The condition had first appeared in the groin some days after crosssectomy for chronic venous insufficiency of the lower limbs and had progressed rapidly. Laboratory tests showed an erythro-

cyte sedimentation rate of 29 mm/h, and increased fibrinogen and α_2 globulin. Thrombocytopenia was present. Ecography of the scrotum showed hypoechoic tissue with indistinct margins. Microbial culture from the infected site gave a mixed growth of *Pseudomonas maltophile* and *Escherichia coli*.

A broad-spectrum antibiotic therapy, consisting of meropenem, metronidazole, teicoplanin and ceftazidime, was administered according to antibiotic sensitivity testing and chemical progression, together with a supportive therapy with albumin, phytomenadione and anti-thrombin.

Surgical debridement was performed and topical medication with rifamicin solution and gentamycin cream was applied. Resolution of the disease, leaving scarred skin, occurred within 2 months (Fig. 2).

DISCUSSION

About 400 cases of Fournier's gangrene have been reported. It is more common in males (85%) than females. Its progression is rapid and it is lethal in 20–30% of cases. The condition is

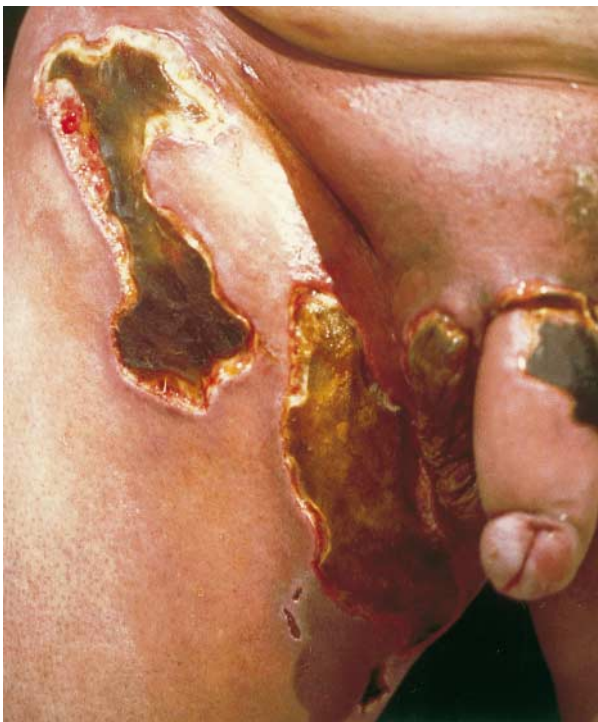

Fig. 1. Skin necrosis in the right groin, thigh and genitalia.

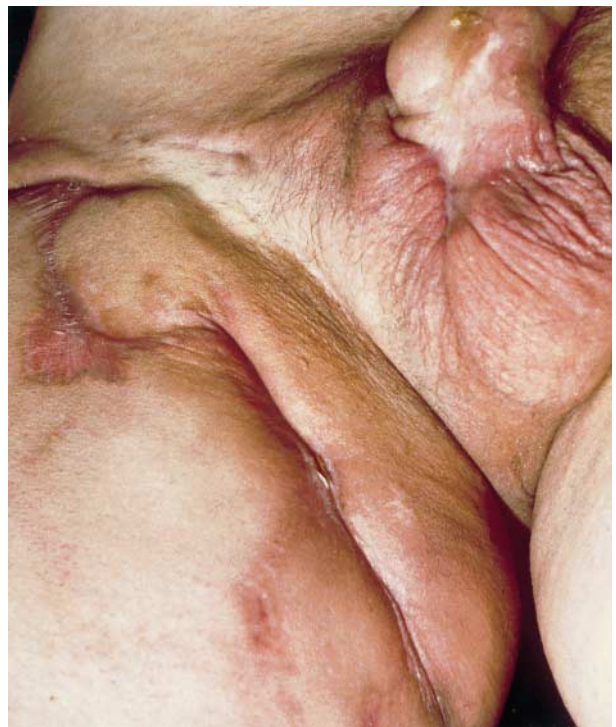

Fig. 2. Resolution of the disease with skin scarring after 2 months.