

# Quantitative Image Analysis of Hair Follicles in Alopecia Areata

IL-HWAN KIM, HO-YEON JO, CHANG GEUN CHO, HYAN-CHUL CHOI and CHIL-HWAN OH

Department of Dermatology, College of Medicine, Korea University, Seoul, Korea

**We took biopsies from similar sites on the scalps of normal controls, normal looking and hair loss areas of patients with alopecia areata. The specimens were sectioned serially and horizontally. We measured morphological parameters, such as the diameter of the hair shaft, the thickness of the inner root sheath, the diameter of the outer root sheath, the irregularity of the outer root sheath and the ratio between the diameters of the hair shaft and the outer root sheath, using a computerized image analysis system. There were significant differences in 5 parameters between hair loss areas and normal controls. The proportions of vellus and telogen hair were significantly higher in the areata areas than in the controls. The 5 morphological parameters and most quantitative-measured parameters of normal-looking areas from patients with alopecia values intermediate between the other groups. Key words: alopecia areata; transverse section image analysis.**

(Accepted November 12, 1998.)

Acta Derm Venereol 1999; 79: 214–216.

C.-H. Oh, Department of Dermatology, Korea University College of Medicine, 80 Guro-dong, Guro-gu, Seoul 152-703, South Korea.

The horizontal sections of scalp biopsies in alopecia areata (AA) provide more diagnostic and suitable information for the quantitative and morphometric analysis of follicular structures than do vertical sections (1–5). Conventional vertical sections of cylindrical punch biopsy specimens disclosed only about 10–15% of the follicles in the tissue sample (1–3). Diagnostic morphological features of AA included a significantly decreased terminal hair, increased follicular stela, decreased anagen, increased telogen, often increased catagen hairs, and increased vellus hairs (6). Any histological study requiring accurate vellus hair counts and terminal:vellus hair ratio requires the use of transverse sections (1, 3). Quantitative assessment of hair or hair follicle morphology using image analysis is particularly valuable for the diagnosis and disease progress of the hair disorder including AA (7–8). In this study, we applied image analysis to obtain detailed morphological and quantitative parameters of the hair follicles, using horizontally sectioned scalp biopsies from normal controls and AA patients.

## MATERIAL AND METHODS

Biopsies were taken from the scalps of 3 groups with a 6 mm disposable punch: the scalps of 12 healthy subjects (6 men and 6 women; aged 7–65 years, mean 25.7 years), the hair loss area of 46 subjects (28 men and 18 women; aged 6 to 75 years, mean 28.2 years) with AA (LAA) and the normal scalp area of 23 subjects (11 men and 12 women; aged 7 to 66 years, mean 27.3 years) from an AA patient group (NAA). In the NAA patient group, a biopsy was taken from the lesion and surrounding normal-hair bearing non-lesional skin of the same patients. The duration of lesions in alopecia areata patients group ranged from 2 weeks to 3 months. Speci-

mens were sectioned into 2 segments 1 mm from the junction of the dermis and subcutis. Each segment was then embedded in paraffin, the segment was sectioned serially and horizontally by microtome (5–7  $\mu$ m) in the direction of the upper dermis (superior segment) and lower dermis (inferior segment). Each slide contained 3–4 sections, all at different levels from within the specimen. This allowed us to examine the hairs from the isthmus to the bulbar portion and thereby differentiate vellus, catagen and telogen hair. We used the H & E and toluidine blue stain for all sections and one of the authors (HY Jo) searched for hair from the isthmus to the bulbar portion of terminal hair. We analysed 1,528 hair follicular structures (18–20 structures for each specimen) in 3 groups. To reduce measurement errors, the morphological parameters were measured repeatedly on the same specimens by 2 of us (CH Oh, HY Jo).

### Measurement of the morphological parameters using image analysis (Table 1)

We examined the level of scalp hair follicle stems following the above preparations for transverse section of the dermis and subcutis under 40 $\times$  power light microscope (Olympus Inc, BHS-313w). The images were continuously monitored by video camera (Pualani TM440) and displayed on a RGB monitor (Sony Inc, PVM 1342Q). The analogue video signals were digitized and analysed with an image analysis system (AIC Co, Ca). Linear measurements were obtained using the Video Trace mode. We calculated the 5 morphological parameters (Fig. 1) using the given equation (9). Statistical analysis was performed with NCSS (Number Cruncher Statistical System).

### Quantitative measurements under light microscope (H&E stain, $\times 40$ )

The following quantitative parameters were measured in the whole area of the horizontal section under light microscope (Fig. 1).

1. The number of hair structures per unit area ( $\text{mm}^2$ ) and telogen germinal unit, which contains a central island of basaloid cells with peripheral palisading of the nuclei.
2. The percentage of terminal hair, vellus hair, anagen hair, catagen hair, telogen hair and follicular stela, comprising condensed perifolliculum with blood vessels.

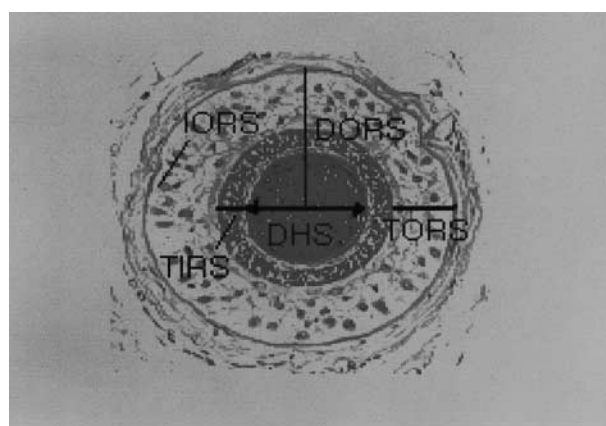


Fig. 1. The 5 morphological parameters: TIRS, thickness of inner root sheath; TORS, thickness of outer root sheath; DHS, diameter of hair shaft; DORS, diameter of outer root sheath; IORS, irregularity of outer root sheath ( $\text{perimeter}^3/\text{area}^2$ ); DORS/DHS ratio; A, area of hair shaft transects; D, diameter.  $D = 2(A/\pi)^{1/2}$ .

Table I. Comparisons of quantitative measurement under light microscopy in each group per mm<sup>2</sup> (mean ± SE)

	LAA	NAA	NC
No. of hairs/mm <sup>2</sup>	3.3±0.5	3.2±0.6	3.0±0.4
Terminal (%)			
Anagen	17.2±1.1	70.0±0.4	96.0±0.1
Catagen	14.6±1.3	4.4±1.7	0.3±3.5
Telogen	18.1±1.2	2.9±1.7	0.4±3.5
Total	50.0	77.2	96.7
Vellus (%)			
Anagen	15.6±1.4	11.3±1.5	0.4±2.3
Catagen	11.4±1.3	2.9±1.8	0.3±3.5
Telogen	11.6±1.0	4.2±1.4	1.4±3.5
Total	38.6	18.5	2.2
Terminal : vellus ratio	1.3 : 1	4.2 : 1	44.5 : 1
Anagen : telogen ratio	1.1 : 1	11.4 : 1	32 : 1
Follicular stela (%)	11.2±1.3	4.3±2.2	0.7±2.4
Telogen germinal unit	6.9	6.8	0

Most data were converted by hair structure per mm<sup>2</sup>.

LAA, lesion site of alopecia areata; NAA, normal site of alopecia areata; NC, normal control.

3. The ratio of terminal hair : vellus hair (T : V ratio) and anagen hair : terminal hair (A : T ratio).

## RESULTS

The results of measurements of the morphological parameters using the image analysis system are shown in Table II and the results from qualitative measurement under light microscope in Table I. There were no significant differences between men and women in the above measurements.

## DISCUSSION

In the LAA group, the diameter of the hair shaft (DHS) and the diameter of inner (DIRS) and outer root sheath DORS were decreased. Our measurement of the DHS of the LAA group was smaller than the control group (2.57 times larger than the LAA group) or NAA group (1.57 times larger than the LAA group). This result reflects that proportion of terminal hair in the control group which is larger than in the AA groups (LAA and NAA), while the proportion of vellus hair in the AA group is larger than in the control group. Thus we

consider DHS and DORS as useful parameters for differentiating between the AA patient groups and the control group. The DORS : DHS ratio was increased in the AA groups, it was largest in the LAA group and it was decreased in the NAA and control group in descending order. These results reflect that the DHS decreased more than the DORS in the AA group. The irregularity of outer root sheath (IORS) was largest in the LAA group and was decreased in the NAA and control groups in descending order. This was shown by the increased proportions of telogen hair in the hair loss area of the AA group. The thickness of the inner root sheath (TIRS) was larger in the control group than in the AA patient group, but there was no difference in TIRS between the NAA and LAA groups. Our study demonstrates that most of the 5 morphological parameters were statistically significant in difference through each pair of the 3 groups except TIRS. AA is a rapid and largely inflammatory process causing miniaturization of the hair follicles (5, 10). There is a progressive replacement or loss of coarse terminal hairs normally covering the scalp by fine short vellus hairs (11). The size of hair follicles decreased significantly in the AA scalp biopsies, similarly to a previous report on androgenetic alopecia (8). In our results, the DHS, TIRS and DORS of the AA groups (NAA and LAA) were significant smaller than in the control group. But the DORS : DHS ratio and the IORS in the AA group were significantly larger than in the control group.

This study raised the question about the definition of vellus hair by Headington (1). Headington's definition of vellus hair (that the cross-sectional diameter of vellus hair shaft is 30 µm or less thicker than TIOR) was inconsistent with our result. The amount of vellus hair which corroborated Headington's definition was only 23.75% in our study. However, the amount of vellus hair with thicker DHS than TIRS and a diameter of less than 0.03 mm was 76.25%. Our study shows quite different results from Headington's definition. In the pathological process of AA, the diameter of the hair shaft decreases to miniaturized hair and leads to vellus hair formation. So we might consider vellus hairs with a diameter of less than 0.03 mm and greater than the associated inner root sheath as a possible explanation.

In quantitative measurements under light microscope, our study also indicates that the number of anagen hairs and the T : V ratio were decreased and the number of catagen, telogen and vellus hair were increased in the AA patient group. The proportion of anagen hair in total hair was 96.74% in the control group, 77.24% in the NAA group and 49.98% in the LAA

Table II. Comparisons of the morphological data for the hair structures using image analysis (mean ± SE)

	LAA (hair loss in alopecia)	NAA (normal alopecia areata)	Controls	<i>p</i> value <0.0001 (ANOVA)
Diameter of hair shaft (DHS)	44.0±2.6	61.5±3.1	112.9±3.3	LAA vs. controls (<0.001)
Thickness of inner root sheath (TIRS)	17.0±0.6	16.3±0.6	20.2±0.8	LAA vs. controls (<0.01) NAA vs. controls (NS)
Diameter of outer root sheath (DORS)	180.6±5.9	225.2±9.3	266.7±9.5	LAA vs. controls (<0.001) LAA vs. NAA (<0.001)
DORS/DHS	5.7±0.3	4.5±0.2	2.6±0.1	LAA vs. controls (<0.0001)
Irregularity of outer root sheath (IORS)	2.1±2.4	0.7±1.3	0.3±0.3	LAA vs. controls (<0.01) LAA vs. NAA (<0.01)

\* Prob > F: DHS, DORS, IORS, DORS and DORS/DHS ratio.

group. The proportion of vellus hairs in total hair was 2.17% in the control group, 18.46% in the NAA group and 38.61% in the LAA group. This data was similar to the results of previous studies (4–5). The A:T ratio was 32:1 in the control group, 11.4:1 in the NAA group and 1.14:1 in the LAA group. This is presumably caused by short anagen cycles of the miniaturized hairs in AA with a resulting increase in the frequency of telogen hair (5). Our result, which shows a relatively higher T:V ratio for the normal group than in other reports, is due to differences in the level of horizontal sections, including a deeper lower dermis with mainly anagen hairs which contained only a small number of vellus hair. We studied the horizontal sections through the lower segment of the follicle (lower dermis) but other reports were done through the isthmus portion (4).

Measurements of the density of hair follicles did not show a significant ( $p > 0.01$ ) difference between normal (control,  $3.03 \pm 0.37 \text{ mm}^2$ ) and AA scalp biopsies (LAA- $3.29 \pm 0.45 \text{ mm}^2$ , NAA- $3.21 \pm 0.61 \text{ mm}^2$ ). Whiting (12) insists that in AA a concentration of 1 or less follicular structures per  $\text{mm}^2$  is likely to be inadequate for significant regrowth of hair at some future time. We also studied the follicular stelaes separately, because it was difficult to differentiate the catagen hair from telogen hair. Follicular stelaes were found at 11.21% in the LAA group and 0.72% in control group. The telogen germinal unit is the resting or end-stage telogen follicle, which is considered to be an early finding of AA. It was not seen in the NC group but best seen on the horizontal section of AA patient group (4). In our study, it was increased in the alopecia areata group (LAA 6.94%, NAA 6.78%). Because the major differences in most parameters in the NAA group showed a value intermediate between the LAA and control group, the quantitative and morphometric data of normal scalp in AA patients (NAA group) may be useful to predict the prognosis of advancing AA (13).

Image analysis with horizontal sections is a simple technique and much faster to perform than linear measurements and can therefore be used to quantify rapidly the severity and extent of

AA. It also may represent a method of quantifying the effectiveness of hair growth promoters in clinical trials.

In conclusion, our study indicates that image analysis is a useful tool to quantify and morphologically evaluate hair follicular structures in horizontal sections of AA.

## REFERENCES

1. Headington JT. Transverse microscopic anatomy of the human scalp. *Arch Dermatol* 1984; 120: 449–456.
2. Whiting DA. The value of horizontal sections of scalp biopsies. *J Cutan Aging Cosmet Dermatol* 1990; 1: 165–173.
3. Sperling LC, Winton GB. The transverse anatomy of androgenetic alopecia. *J Dermatol Surg Oncol* 1990; 16: 1127–1324.
4. Whiting DA. Histopathology of alopecia areata in horizontal sections of scalp biopsies. *J Invest Dermatol* 1995; 104: 26–27.
5. Messenger AG, Slater DN, Bleehen SS. Alopecia areata. Alterations in the hair growth cycle and correlation with the follicular pathology. *Br J Dermatol* 1986; 114: 337–347.
6. Eckert J, Church RE, Ebling FJ. The pathogenesis of alopecia areata. *Br J Dermatol* 1968; 80: 203–210.
7. Gibbons RD, Fiedler Weiss VC, West DP, Lapin G. Quantification of scalp hair – a computer-aided methodology. *J Invest Dermatol* 1986; 86 (1): 78–82.
8. Lee MS, Kossard S, Wilkinson B, Doyle JA. Quantification of hair follicle parameters using computer image analysis. A comparison of androgenetic alopecia with normal scalp biopsies. *Aust J Dermatol* 1995; 36: 143–147.
9. Bhawan J, Smolle J. Computerized video image analysis in dermatopathology. *Adv Dermatol* 1994; 9: 115–119.
10. Nelson DA, Spievogel RL. Alopecia areata. *Int J Dermatol* 1985; 24: 26–32.
11. Sperling LC. Hair anatomy for the clinician. *J Am Acad Dermatol* 1991; 25: 1–17.
12. Whiting DA. Diagnostic and predictive value of transverse sections of scalp biopsies in alopecia areata. *J Cutan Pathol* 15; 350, 1988.
13. Peereboom-Wynia JDR, Beek CH, Mulder PG, Stolz E. The trichogram as a prognostic tool in alopecia areata. *Acta Derm Venereol (Stockh)* 1993; 73: 280–282.