

## Five-year Results of Mohs' Micrographic Surgery for Aggressive Facial Basal Cell Carcinoma in Sweden

ANN-MARIE WENNBERG<sup>1</sup>, OLLE LARKÖ<sup>1</sup> and BO STENQUIST<sup>2</sup>

<sup>1</sup>Department of Dermatology, Göteborg University, Sahlgrenska University Hospital and <sup>2</sup>Department of Surgery, Lundby Hospital, Göteborg, Sweden

**Mohs' micrographic surgery of facial basal cell carcinoma ensures a high cure rate with maximal preservation of healthy tissue. Using precise margin control, this procedure allows complete examination of all margins of tissue removed. Due to the insufficient facilities for Mohs' micrographic surgery in Sweden, only the most aggressive tumours are referred for this procedure, which could increase the risk of recurrences. We have operated on 228 basal cell carcinomas, 87 primary and 141 recurrent tumours, over the period 1983 to 1992. The tumours were located on the face and all patients were followed for 5 years after surgery. The recurrence rate was 6.5% for primary and 10% for recurrent basal cell carcinomas. After 12 months the functional and cosmetic results were evaluated, showing good or satisfactory results in 93% of cases. Mohs' surgery is an underused but still efficacious technique in Sweden and should be recommended to other centres. Key words: skin tumour clinic; recurrence rate; underserved area.**

(Accepted January 28, 1999.)

Acta Derm Venereol 1999; 79: 370–372.

A.-M. Wennberg, Department of Dermatology, Göteborg University, Sahlgrenska University Hospital, S-413 45, Göteborg, Sweden.

A "chemosurgical" technique with zinc chloride for removal of skin cancer was described by Frederic Mohs in 1941 (1). Years later he also introduced the simplified "fresh tissue technique", although it was presented and later published by his colleagues Tromovitch & Stegman (2–4). After using several different names to describe this technique, in 1986 the American College of Chemosurgery finally settled on to the name Mohs' micrographic surgery (MMS), which expresses the use of microscopy and graphic representation (mapping) of the wound on paper (5–10).

MMS is used in several European countries (Portugal, Spain, Belgium, Italy and Germany), and in April 1990 the European Mohs' Micrographic Society was founded in Lisbon. Nevertheless, in Scandinavia it is not a widely used surgical procedure. The technique has been available at the Sahlgrenska University Hospital in Göteborg, Sweden, since 1983. This is the only place in Scandinavia where MMS is regularly used. Our resources are limited and other methods are often used for treatment of skin cancer, even on the face (11). The most commonly accepted indications for MMS are recurrent tumours, tumours located in areas with a high risk of local recurrence or where tissue preservation is mandatory, and those with morpheiform growth (4).

The aim of this study was to evaluate our material. As we are limited to operating only on very aggressive tumours, we wanted to compare our results with those from other centres where the indications for MMS are less restrictive.

### MATERIALS AND METHODS

#### Patients

We have performed MMS on 265 non-melanoma skin cancers from 1983, when the method was introduced, until 1992. Of these tumours, 20 (7.5%) were lost to follow-up and a further 17 were excluded due to other causes (5 squamous cell carcinomas, 3 Paget's disease, 1 recurrence after MMS and 8 tumours not radically excised). The remaining 228 basal cell carcinomas (BCCs) occurred in 221 patients (96 men, 125 women) with a mean age of 68 years (range 24–90 years). A total of 87 were primary tumours (38%) and 141 were recurrent BCCs (62%). The previous treatments used for the recurrent tumours were: cryosurgery, electrodesiccation and excision. All patients had aggressively growing BCCs (morpheiform tumours with ill-defined borders and/or recurrent tumours). Almost all tumours (98.7%) were located on the face and neck ( $n=1$ ) with the most common site being the nose (Fig. 1). Three BCCs were situated on the trunk.

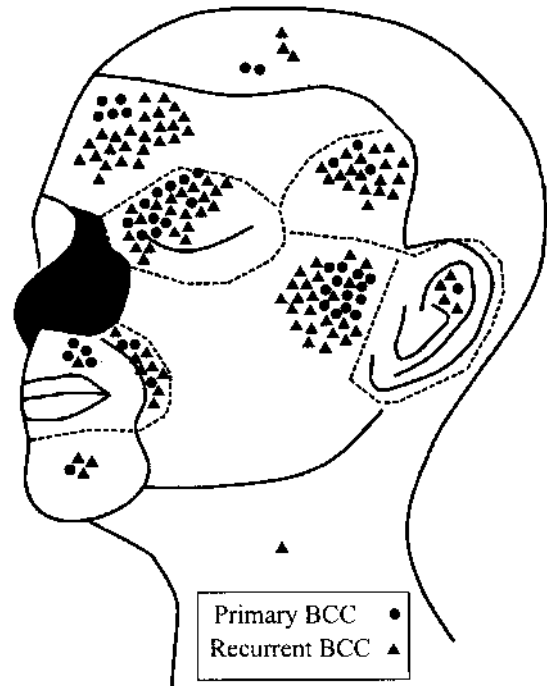


Fig. 1. The location of the BCCs on the face and neck. Each dot (primary BCC) and triangle (recurrent BCC) represents 1 tumour, the nose (shaded grey) being an exception as it is the most common site for both primary ( $n=42$ ) and recurrent ( $n=33$ ) BCCs. Numbers of BCCs are: eye region (primary 11, recurrent 21), temple (primary 3, recurrent 18), forehead (primary 5, recurrent 25), scalp (primary 2, recurrent 3), ear (primary 1, recurrent 4), cheek (primary 13, recurrent 23), nasolabial fold (primary 3, recurrent 8), mouth (primary 4, recurrent 1), chin (primary 1, recurrent 3) and neck (primary 1, recurrent 0).

### Skin tumour clinic

Our MMS team comprises a general surgeon, a dermatologist, a dermatopathologist, a nurse, a nurse's aid and 2 histotechnicians. Approximately 60 patients are operated on each year.

When a patient is referred to us, both the surgeon and the dermatologist examine the patient and decide which treatment is the most suitable. This is a difficult selection because of the limited resources for MMS and usually only tumours located on the face are considered. If, for example, the tumour borders are well defined and no aggressive growth is shown histopathologically, excisional surgery or cryosurgery is performed (11). The patients must also be in a fairly healthy condition to cope with the procedure and patients over the age of 80 years are examined thoroughly before surgery.

### MMS technique

We use a modified Mohs' technique, since the surgeon and the pathologist are different individuals. MMS is usually a day-care procedure performed under local anaesthesia. Both the general surgeon and the dermatologist examine the tumour area under a high illumination lamp in order to delineate the tumour margins preoperatively.

The first Mohs' excision is outlined with ink with a margin to the tumour of 1–2 mm. Long-acting bupivacaine 0.5% (Marcain®) with adrenaline is used for infiltration. The bulk of the tumour is removed by curettage when necessary. From the wound, a 2–3 mm saucer-shaped layer of tissue is excised (in a single piece) by angling the scalpel at 45°. Nicks are made in the 3, 6 and 9 o'clock position for orientation both in the removed specimen and in the remaining wound. A suture is placed in the resected tissue in the 12 o'clock position and a corresponding stitch is left in the normal skin of the patient some centimetres above for orientation in case more excisions are necessary. Computerized bipolar diathermy is used for haemostasis (12).

The excised tissue is then brought to the adjacent Mohs' laboratory, where it is incised on the epidermal surface so that the epidermal and deep margins can be flattened into the same plane at sectioning. The specimen is divided into pieces suitable for frozen section processing. The edges of the pieces are colour-coded by the Davidson Marking System (Bradley Products, Inc. Bloomington MN, USA). The histotechnician maps the excised tissue on a piece of paper, indicating the source of the specimen and the colour coding. The specimen is inverted and 5–7 µm cuts are taken from the bottom of the excised tissue and stained with haematoxylin and eosin. The colour coding is easily seen under the microscope and does not interfere with the reading of the slide. The residual tumour areas are noted on the map. Repeated layers are excised at the precise location. The stepwise procedure is continued until all cancer is removed. The surgeon is intimately involved in all aspects of the Mohs' laboratory but does not read the slides.

### Statistical evaluation

The Kaplan-Meier model was used for the statistical analysis of the recurrence rate (13). All patients were followed for 5 years after surgery with considerations taken to the deaths that occurred during this period (26 patients) and to the patients that were not followed for the whole period (13 patients). To detect possible risk factors, Fisher's exact test was carried out. The parameters tested for differences in recurrence rate after MMS were: different regions (temple, nose, forehead), primary or recurrent BCC, age (above or below 70 years) and number of excisions ( $\leq 2$  vs.  $\geq 3$ ).

## RESULTS

The number of tumours free of recurrence was 210 of the total of 228 during the 5-year follow-up. Table I shows the 18 tumours that recurred in this period. The recurrence rate according to the Kaplan-Meier model was 6.5% for primary

Table I. Recurrences after Mohs' micrographic surgery

Patient no.	Age/sex (M/F)	Location	Primary (p) or recurrent (r) BCC <sup>a</sup>	Time of appearance of recurrences (years)	Excisions (n)
1	84/M	cheek	r	0.5	3
2	81/F	temple	r	0.5	1
3	73/M	eye	r	1.0	3
4	76/M	cheek	r	1.0	3
5	67/M	nose	p	1.0	4
6	65/M	temple	r	1.0	3
7	58/M	cheek	r	1.5	3
8	85/F	nasolabial fold	r	1.5	3
9	80/F	temple	r	2.0	2
10	78/F	cheek	r	3.0	2
11	80/F	forehead	r	3.5	3
12	67/F	nose	r	4.0	3
13	59/F	nose	p	4.0	6
14	57/F	nose	p	4.0	2
15	70/M	temple	r	4.0	5
16	75/F	cheek	p	4.5	2
17	69/F	nose	p	5.0	3
18	85/F	cheek	r	5.0	2

<sup>a</sup> Basal cell carcinoma.

( $n=5$ ) and 10% for recurrent ( $n=13$ ) BCCs, thus leading to a difference of  $3.5 \pm 3.9\%$  (SEM). The difference was not statistically significant. After 6 months we had the first recurrence in the recurrent BCCs. Only 5 of the recurrences occurred in primary tumours and of these 1 appeared after 1 year, 2 after 4 years, 1 after 4.5 years and 1 after 5 years. There was a tendency for the temple region to have more recurrences than other areas ( $p < 0.069$ ) (Table I). No statistically significant difference in recurrence rate after MMS was found between patients aged above and below 70 years.

In the majority (69%) of the MMS operations, 2 or 3 excisions (range 1–7) were required. There was no statistically significant difference in the number of excisions made between the tumours that recurred and the ones that did not. When reconstructing the wounds, primary closure was used for 40 tumours, grafts in 64 and flaps in 90 tumours. In 34 cases the wounds were left for secondary intention.

The final functional and cosmetic result was evaluated 12 months after surgery. A total of 17 wounds (7%) healed with a cosmetically unsatisfactory scar and 8 of these were subjected to reoperation by a plastic surgeon (3.5%). We had problems with wound infections only in isolated cases.

## DISCUSSION

In order to make optimal use of the limited resources for MMS in our area, dermatologists have referred aggressive and large BCCs on the face for assessment at our skin tumour clinic. Some of these patients had to be treated by excisional surgery, cryosurgery or radiotherapy. For tumours on the nose and ear growing less aggressively, curettage and cryosurgery can be a good alternative in areas underserved by MMS (11). In the USA, approximately 30% of all BCCs are treated with MMS (14). In our area of referral, the figure

is less than 1%. We seldom treat patients over the age of 85 years with MMS mainly due to the limited resources. Even when very old patients are operated upon with MMS the advantages of the method are considerable (15).

In this 5-year follow-up of aggressive BCCs on the face we had 6.5% recurrences in primary tumours and 10% recurrences in recurrent (previously treated) BCCs. There was a tendency for the temple region to have more recurrences than other areas. Corresponding figures for non-melanoma skin cancer in American materials were 2% and 7%, respectively (7–10) and in European materials 2% and 5%, respectively (16–17). The majority of the Mohs' surgeons in USA operate upon at least 150 patients each year and 25% of the MMS surgeons perform more than 500 operations a year (6).

There are several possible reasons for the higher recurrence rates in our material. We operate only in the most aggressive cases. Despite thorough clinical examination, only 31% were cured in the first layer. In the majority of the operations (69%) 2 or more excisions were required to achieve microscopic clearance; in 9% we had to make 4 excisions and in certain cases up to 6 or 7 excisions. This high number of stages indicates that we operate upon more aggressive tumours, or perhaps the margins are too narrow. On the other hand, we have an experienced dermatopathologist evaluating the slides instead of the surgeon, which could make this investigation more reliable.

The cosmetic result was good or satisfactory in 93% of cases, probably due to frequent use of dermabrasion or intralesional steroids postoperatively when necessary. Seven percent of the wounds healed with an unsatisfactory scar and 3.5% of the patients were referred for plastic surgery for correction.

In our country, it is often said that MMS is a time-consuming and laborious procedure and therefore very expensive. Even disregarding the fact that the recurrence rate with MMS is about 8%, compared with 30–50% when using conventional methods for this tumour category (18), it has recently been shown in the USA that MMS is cheaper than other forms of treatment (19). MMS is used regularly in a single centre in Sweden and not at all in other Scandinavian countries. Although a time-consuming and personnel-demanding technique it is cost-effective and should be available in centres where aggressive facial BCC is treated.

#### ACKNOWLEDGEMENTS

We thank Tommy Johnsson for statistical guidance and Ann-Christine Sandberg-Nordeke for help with the patients' records.

#### REFERENCES

1. Mohs FE. Chemosurgery: a microscopically controlled method of cancer excision. *Arch Surg* 1941; 42: 279–295.
2. Tromovitch TA, Stegman SJ. Microscopically controlled excision of skin tumours: chemosurgery (Mohs)-fresh tissue technique. *Arch Dermatol* 1974; 110: 231–232.
3. Tromovitch TA, Stegman SJ. Microscopic-controlled excision of cutaneous tumours. Chemosurgery, fresh tissue technique. *Cancer* 1974; 41: 653–658.
4. Shriner DL, McCoy DK, Goldberg DJ, Wagner RF. Mohs micrographic surgery. *J Am Acad Dermatol* 1998; 39: 79–97.
5. Bernstein G, Cottel WI, Bailin PL, Braun M, Sutnick TB, Pollack SV, et al. Mohs' micrographic surgery. *J Dermatol Surg Oncol* 1987; 13: 1.
6. McGillis ST, Wheeland RG, Sebben JE. Current issues in the performance of Mohs micrographic surgery. *J Dermatol Surg Oncol* 1991; 17: 681–684.
7. Rowe DE, Carroll RJ, Day CL Jr. Long-term recurrence rates in previously untreated (primary) basal cell carcinomas: implications for patients follow-up. *J Dermatol Surg Oncol* 1989; 15: 315–328.
8. Rowe DE, Carroll RJ, Day CL Jr. Mohs surgery is the treatment of choice for recurrent (previously treated) basal cell carcinoma. *J Dermatol Surg Oncol* 1989; 15: 424–431.
9. Rowe DE, Carroll RJ, Day CL Jr. Prognostic factors for local recurrence, metastasis and survival rates in squamous cell carcinomas of the skin, ear and lip: implications for treatment modality selection. *J Am Acad Dermatol* 1992; 26: 976–990.
10. Robins P, Dzubow LM, Riegel DS. Squamous cell carcinoma treated by Mohs' surgery. An experience with 414 cases in a period of 15 years. *J Dermatol Surg Oncol* 1981; 7: 800–801.
11. Nordin P, Larkö O, Stenquist B. Five-year results of curettage-cryosurgery of selected large primary basal cell carcinomas on the nose: an alternative treatment in a geographical area underserved by Mohs' surgery. *Br J Dermatol* 1997; 136: 180–183.
12. Bergdahl B, Stenquist B. An automatic computerized bipolar coagulator for dermatologic surgery. *J Dermatol Surg Oncol* 1993; 19: 225–227.
13. Kaplan EL, Meier P. Non-parametric estimation from incomplete observations. *J Am Stat Assoc* 1958; 53: 457–471.
14. Welch ML, Anderson LL, Grabski WJ. How many non-melanoma skin cancers require Mohs' micrographic surgery? *J Dermatol Surg* 1996; 22: 711–713.
15. Mac Farlane DF, Pustelny BL, Goldberg LH. An assessment of the suitability of Mohs' micrographic surgery in patients aged 90 years and older. *J Dermatol Surg* 1997; 23: 389–393.
16. Neumann HAM, Krekels GAM, Verhaegh MEJM. Treatment of 208 extensive basal cell carcinomas with Mohs' micrographic surgery. *J Eur Acad Dermatol Venereol* 1996; 6: 217–225.
17. Julian CG, Bowers PW. A prospective study of Mohs' micrographic surgery in two English centres. *Br J Dermatol* 1997; 136: 515–518.
18. Zitelli J. Mohs' micrographic surgery for skin cancer. *Principles and Practice of Oncology* 1992; 8: 1–10.
19. Cook J, Zitelli J. Mohs' micrographic surgery versus surgical excision with frozen section control: a cost analysis. *J Dermatol Surg* 1988; 24: 482–488.