

## A Juvenile Case of Classic Kaposi's Sarcoma

Sir,

Classic Kaposi's sarcoma (KS) is characterized by vascular-like plaques and nodules, which are most frequently localized on the lower limbs. The majority of cases of classic KS have occurred among elderly men; it is rarely seen in childhood.

We describe here a rare case of classic KS occurring in a young boy.

### CASE REPORT

A 13-year-old boy was admitted to our dermatology outpatient clinic with red to brown macules on his legs and arms. He had had violaceous to red macules on his legs and feet and similar lesions on his arms 1 year before admission. Apart from these complaints, there were no important features in his history or his family history.

On dermatological examination, numerous brownish-red patches, 10–30 mm in diameter, of variable shape were seen on his legs and arms (Figs. 1 and 2). The patches were slightly indurated with thin squams. In addition, there were a few violaceous–red macules, 30–50 mm in diameter, with sharp borders and of various shapes on the soles of his feet and toes. The oral mucosa, fingernails and toenails were of normal appearance.

Multiple lymphadenomegaly in the cervical and submandibular

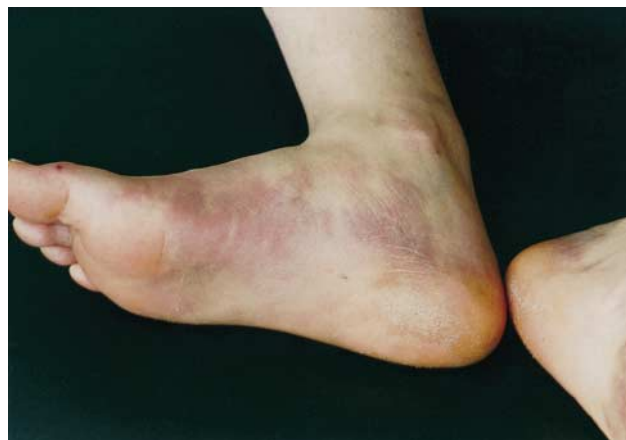

Fig. 1. Violaceous-red patches on the legs and feet.

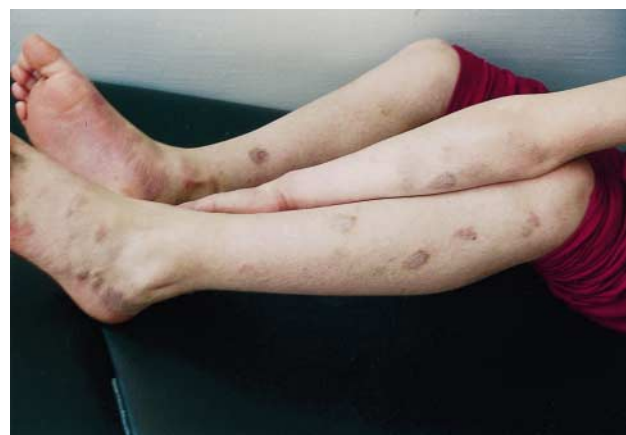

Fig. 2. Numerous brownish-red patches on the arms, legs and feet.

regions and 3–5 lymphadenomegaly, which were mobile and painless, were detected in both the axillary and the inguinal regions. Inguinal biopsy showed reactive lymph nodes. Other organ system examinations were evaluated as normal. There was no pathology in laboratory parameters (complete blood count, urinalysis, blood biochemistry, erythrocyte sedimentation rate, VDRL, TPHA or HIV). HHV-8 was found to be negative by PCR. Chest X-ray, abdominal ultrasound graphics and oesophageal, gastric, duodenal and colon contrast graphics were evaluated as normal. A skin biopsy specimen was taken from the lesion near the left ankle. There was widespread inflammatory mononuclear cell infiltration and prominent vascular proliferation in the medium and upper dermis. The histopathological picture corresponded with late macular stage of KS (Figs. 3 and 4).

Intralesional vinblastine (0.1 ml/cm<sup>2</sup>) was applied as therapy and the patient exhibited a good response. We continue to follow-up the patient at regular periods.

### DISCUSSION

Four types of KS have been described: classic KS, endemic African KS, KS seen in iatrogenically immunosuppressed patients and KS associated with AIDS (1). Although these types differ from each other in terms of their clinical picture, the evaluation and immunological characteristics of all types have similar histopathological characteristics (2). Although endemic African type KS might be seen in children, classic KS is rarely seen in childhood (3). In a literature review, only 4 juvenile KS cases, in 3 reports, were found. In 1 of the papers, a 3-year-old boy had been shown to be a KS case with negative HTLV-3 antibody on post-mortem examination (4). Diffuse internal organ involvement was observed. No skin findings were detected. Italian investigators reported a 10-year-old HIV-negative boy in whom the diagnosis of KS was made by lymph node biopsy. No skin involvement was mentioned (5). These 2 cases correspond to an endemic African type lymphadenopathic KS rather than classic KS. In addition, another Italian research group reported 2 HIV-

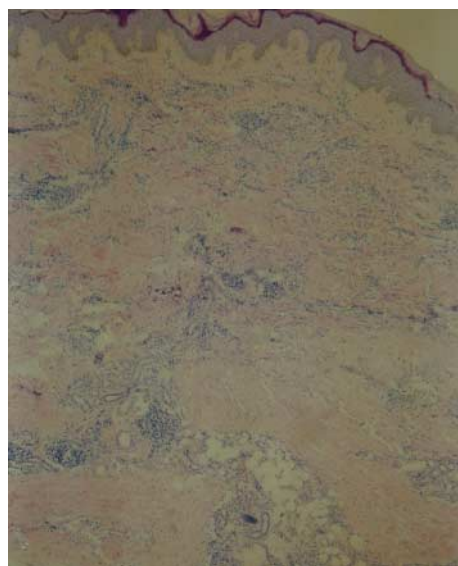


Fig. 3. Prominent vascular proliferation in the dermis ( $\times 40$ , haematoxylin and eosin stain).

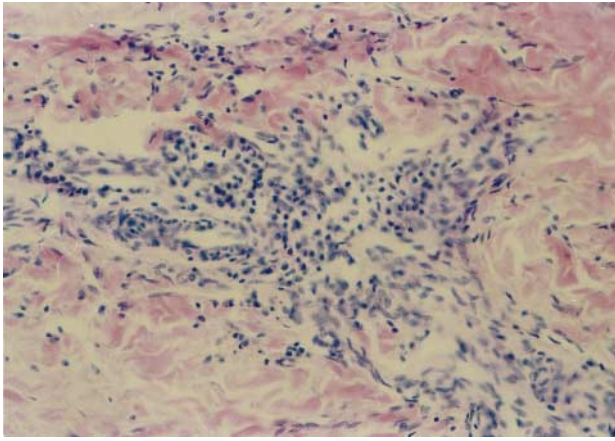


Fig. 4. Perivascular inflammatory mononuclear cell infiltration ( $\times 200$ , haematoxylin and eosin stain).

negative cases of juvenile classic KS. One of them had a family history in which the mother had a history of KS; the latter case had no family history (6).

In a literature review, we found only 2 reports of classic KS in childhood. We now add a further case to this list.

## REFERENCES

1. Rappersberger K, Wolff K, Stingl G. Kaposi's sarcoma. In: Fitzpatrick TB, Eisen AZ, Wolff K, Freedberg IM, Austen KF, eds. *Dermatology in general medicine*, 4th edn. New York: McGraw-Hill, Inc., 1993: 1244–1256.
2. Chor PJ, Santa Cruz DJ. Kaposi's sarcoma: a clinicopathologic review and differential diagnosis. *J Cutan Pathol* 1992; 19: 6–20.
3. Hurwitz S. *Clinical pediatric dermatology*, 2nd ed. Philadelphia: WB Saunders Co., 1993: 38–39.
4. Akman ES, Ertem U, Tankal V, Pamir A, Tuncer AM, Uluoglu O. Aggressive Kaposi's sarcoma in children: a case report. *Turk J Pediatr* 1989; 31: 297–303.
5. Bisceglia M, Amini M, Bosman C. Primary Kaposi's sarcoma of the lymph node in children. *Cancer* 1998; 61: 1715–1718.
6. Zurrada S, Agresti R, Cefalo G. Juvenile classic Kaposi's sarcoma: a report of two cases, one with family history. *Pediatr Hematol Oncol* 1994; 11: 409–416.

Accepted May 27, 1999.

Teoman Erdem, MD, Mustafa Atasoy, MD, Necmettin Akdeniz, MD, Muammer Parlak, MD and Şevki Özdemir, MD  
Department of Dermatology, Faculty of Medicine, University of Atatürk, TU-25240, Erzurum, Turkey.  
E-mail: yildirim@atauni.edu.tr.

## Generalized Severe Lichen Planus Treated with Azathioprine

Sir,

For severe generalized lichen planus, systemic corticosteroids in high doses are effective, but they are likely to cause severe side-effects when the treatment is prolonged. In 2 patients azathioprine has been reported to be effective and safe (1). We describe here a case of generalized severe lichen planus that healed after 3 months' treatment with azathioprine.

### CASE REPORT

A 38-year-old housewife presented with a 6-month history of severely itchy hyperpigmented violaceous papular lesions on her trunk, upper and lower extremities and scalp. The lesions had initially appeared on the abdomen and back and gradually increased to involve the other areas. New lesions were still appearing. She had no history of drug intake for any other problem. She did not have any constitutional or systemic symptoms.

Cutaneous examination revealed multiple, diffusely scattered, 2–5 mm diameter, flat-topped, violaceous, papular lesions on the abdomen, back, buttocks, upper and lower extremities and scalp. The oral mucosa had whitish, irregular plaques in a lacy pattern involving the buccal mucosa. There were no other lesions in the oral cavity. The genital and anal mucosae were normal. The fingernails had dark brown longitudinal striations, but the toenails were normal. The palms, soles and other body sites were not involved. Examination of other systems was unremarkable. Biopsy from a skin lesion revealed irregularly acanthotic epidermis, degeneration of basal cell layer and band-like infiltrate of lymphocytes in the upper dermis. The histopathological features were consistent with lichen planus. Routine

haematological, renal and liver functions tests, urine and stool examination and chest X-ray were within normal limits.

The patient was initially treated with betamethasone, 2 mg daily orally, for a period of 1 month, but this did not control the disease. Moreover, new lesions continued to appear, although there was some improvement in itching. Subsequently she was treated with azathioprine, 50 mg twice daily orally. After 1 month of this treatment she had 50% flattening of all the lesions and no new lesions were noticed during this period. Her itching also improved by 75%. In another month the lesions flattened by 80% and the itching disappeared completely. At the end of 3 months of therapy all the lesions had completely subsided, with dark brown macular pigmentation of the skin lesions and slate grey pigmentation of the mucosal lesions. Haematological, renal and liver function tests repeated every month in order to monitor the toxicity of the drug were normal and she had no other side-effects of the therapy. She had no relapse of the disease during the 1-year follow-up period.

## REFERENCES

1. Lear JT, English JS. Erosive and generalised lichen planus responsive to azathioprine. *Clin Exp Dermatol* 1996; 21: 56–57.

Accepted May 20, 1999.

Kaushal K. Verma, C. S. Sirka and Binod K. Khaitan  
Department of Dermatology and Venereology, All India Institute of Medical Sciences, New Delhi 110 029, India.  
E-mail: kkverma61@hotmail.com.