

## Double-blind Comparison of Azelaic Acid 20% Cream and its Vehicle in Treatment of Papulo-pustular Rosacea

ROAR BJERKE<sup>1</sup>, OLE FYRAND<sup>2</sup> and KLAUS GRAUPE<sup>3</sup>

<sup>1</sup>Departments of Dermatology, <sup>2</sup>Ullevål Hospital, <sup>3</sup>National Hospital (Rikshospitalet), Oslo, Norway and <sup>3</sup>Center of Dermatology, Schering AG, Berlin, Germany

Previous investigations have indicated that topical azelaic acid has beneficial effects in rosacea. This 3-month randomized, double-blind, multicentre study compared the efficacy and safety of azelaic acid 20% cream with its vehicle, in the treatment of papulo-pustular rosacea. A total of 116 patients were enrolled in the study and medication was applied twice daily. Azelaic acid cream produced significantly greater mean reductions in total inflammatory lesions than did vehicle (azelaic acid: 73.4%; vehicle: 50.6%; ( $p=0.011$ ), and erythema severity score (azelaic acid: 47.9%; vehicle: 37.9%; ( $p=0.031$ ). Azelaic acid cream treatment also resulted in significantly more favourable overall improvements than vehicle in both physician ( $p=0.020$ ) and patient ratings ( $p=0.042$ ). Neither azelaic acid cream nor vehicle produced any clinically relevant improvement in telangiectasia. Local adverse events were transient and mainly mild or moderate, and rates were similar for azelaic acid cream (39.5%) and vehicle (38.5%). Burning was the symptom most frequently reported. More than 90% of patients rated the overall local tolerability of their treatment as good or acceptable. In conclusion, azelaic acid 20% cream is effective and well tolerated in the treatment of papulo-pustular rosacea. **Key words:** clinical trial; rosacea therapy; acne; dicarboxylic acids; anti-inflammatory effect.

(Accepted May 3, 1999.)

Acta Derm Venereol 1999; 79: 456–459.

O. Fyrand, Department of Dermatology, National Hospital (Rikshospitalet), Pilestredet 32, N-0027 Oslo, Norway.

Rosacea is a common, chronic dermatosis characterized by facial flushing, erythema, telangiectasia, inflammatory episodes with papules and pustules and, in severe cases, rhinophyma. Little is known about the pathogenesis of rosacea, but microcirculatory dysfunction associated with abnormalities in the perivascular connective tissue as well as in the inflammatory mechanism are considered to be key factors (1, 2).

The current standard pharmacotherapies for rosacea include topical and oral antibiotics, topical and oral metronidazole, and oral isotretinoin, depending on the type and severity of the disease (2, 3). All are successfully able to attenuate the symptoms of rosacea, but their use may be limited by side effects, including gastrointestinal problems (antibiotics) and systemic toxicity (isotretinoin, oral metronidazole).

Azelaic acid, a naturally occurring dicarboxylic acid, is currently used in the treatment of acne and hyperpigmentation (4–6). However, previous investigations have indicated that azelaic acid therapy also has beneficial effects in rosacea (7, 8).

Thus, the present study compared the efficacy and safety of azelaic acid 20% cream with its vehicle, in the treatment of papulo-pustular rosacea.

### MATERIALS AND METHODS

#### Study design

The study was a multicentre, randomized, double-blind, parallel group comparison between azelaic acid 20% cream (Skinoren<sup>®</sup>, Schering AG; Azelex<sup>®</sup>, Allergan Inc.) and its vehicle. To reduce the number of patients receiving vehicle, a ratio of 2:1 was chosen, resulting in a random allocation of 77 patients receiving azelaic acid cream and 39 patients receiving vehicle. All patients gave informed consent prior to the beginning of the trial and were free to terminate their participation at any time. The Declaration of Helsinki and its revisions was followed.

#### Study population

Male and female (not pregnant or nursing) patients enrolled for the study had grade 2 rosacea (Mills and Kligman classification) with at least 10 inflammatory lesions (papules and pustules), persistent erythema and telangiectasia, and were at least 18 years of age. Patients were not eligible if they had a mild form of rosacea (grade 1) characterized by a transient flushing only or by the absence of papules and/or pustules; or had severe forms of rosacea (grade 3) complicated by rhinophyma. Other exclusion criteria comprised marked ophthalmic complications, steroid rosacea, diseases and medications which obscured the course and evaluation of rosacea, and hypersensitivity to the ingredients of the study medications.

#### Study protocol

In order to avoid any carry-over effects from preceding therapy, there was a wash-out period of 2 weeks following topical rosacea treatment or 4 weeks following systemic rosacea treatment. The assignment of study medication was random. Patients applied either azelaic acid cream or its vehicle to the affected areas in the morning and evening for 3 months.

At baseline, general patient data including demographics and previous rosacea history, and baseline severity of rosacea were recorded. During the treatment phase, the therapeutic progress was assessed at monthly intervals (after 1, 2, and 3 months). All evaluable patients were considered in a global evaluation of the results achieved at the end of therapy. Treatment efficacy was assessed by counting the number of inflammatory papules and pustules and rating erythema and telangiectasia. The degree of erythema and telangiectasia was rated in terms of integer scores on a scale of 0 = none to 6 = severe. Each visit included an assessment of local and systemic adverse events as determined by both the patient and physician. At the end of therapy, overall improvement was determined as either complete remission, marked improvement, moderate improvement, no improvement or deterioration. For evaluation the latter two overall ratings were combined as "poor". Also at the end of therapy, patients were queried as to the study medication's efficacy compared with previous therapy, its cosmetic characteristics and general local tolerance.

#### Statistical analysis

All evaluable patients (completed and withdrawals) were included in a confirmatory intent-to-treat (ITT) analysis of treatment differences with the results achieved at their last on-therapy assessment; in withdrawals the last observation was carried forward (LOCF).

Additionally, the results at the monthly visits were analysed exploratory for treatment differences; analysed Wilcoxon's rank sum test (two-tailed) was used in the analyses of the changes from baseline in inflammatory lesions (papules and pustules), erythema and telangiectasia. Overall improvement was analysed with Fisher's exact test.

The level of significance was set at  $p < 0.05$ , with a power  $(1-\beta) = 0.9$ .

## RESULTS

### Patient characteristics

Apart from slight differences in the distribution of patients with regard to gender, the patient baseline characteristics (Table I) were similar for both treatment groups with regard to demographic data and disease activity (inflammatory lesions, erythema and telangiectasia score). The overall mean age for enrolled patients was 49 years, the overall mean previous duration of rosacea was 5.5 years. Approximately 75% of all patients had been previously treated for rosacea. In the azelaic acid group, there were nearly equal numbers of males (52.6%) and females (47.4%). In the vehicle group, there were higher numbers of females (60.5%) than males (39.5%).

Two patients out of the total of 116 enrolled were excluded from evaluation: 1 due to a protocol violation and 1 because the patient only attended the baseline evaluation. Of the 114 evaluable patients, 82.8% completed the full 3-month course of treatment, while 17.2% were prematurely discontinued. Of those discontinued, the majority was due to adverse events or lost to follow-up. Five patients in the azelaic acid group were discontinued due to one or more of the following symptoms: burning, erythema, skin irritation or contact dermatitis. One patient in the vehicle group was discontinued due to skin irritation and erythema.

### Inflammatory lesions

Azelaic acid cream produced significantly greater reductions than vehicle in total inflammatory lesion count (Fig. 1). From baseline to the last on-therapy assessment, the mean decrease in the sum of papules and pustules was 73.4% in the azelaic acid group (mean count at baseline = 30.8; last on-therapy count = 8.3) compared with 50.6% (mean count at baseline = 31.7; last on-therapy count = 15.3) in the vehicle group ( $p = 0.011$ ). Treatment difference was also noted in the completed patients at the month 3 examination ( $p = 0.012$ ).

With regard to the single type of inflammatory lesions between-group differences were evident for papules but not for pustules. A mean overall decrease in papules of 71.5%

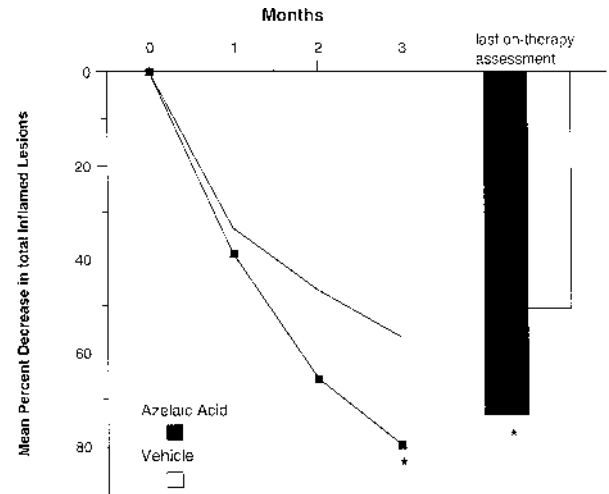


Fig. 1. Reduction in total inflammatory lesion counts. Significantly greater reductions\* with azelaic acid cream were observed at month 3 ( $p = 0.012$ ) and, overall, for the last on-therapy assessment ( $p = 0.011$ ).

(mean count at baseline = 22.9; last on-therapy count = 6.6) was found in the azelaic acid group, compared with 46.5% (mean count at baseline = 23.4; last on-therapy count = 12.8) in the vehicle group. Significant treatment differences were observed after 2 months ( $p = 0.023$ ) and 3 months ( $p = 0.016$ ) of treatment and for the reductions at the last on-therapy assessment ( $p = 0.013$ ).

The mean reduction in pustules achieved for the last on-therapy visit was 81.9% (mean count at baseline = 7.9; last on-therapy count = 1.7) in the azelaic acid group, compared with 70.1% (mean count at baseline = 8.2; last on-therapy count = 2.5) in the vehicle group. No significant treatment differences were found for the reduction in pustules.

### Erythema and telangiectasia

Azelaic acid produced a significantly greater reduction in erythema than did the vehicle. By the last on-therapy assessment, a mean reduction of 47.9% in erythema severity score was achieved with azelaic acid compared with 37.9% with vehicle ( $p = 0.031$ ). Moreover, the change in erythema severity was rated as "better" by slightly more azelaic acid-treated patients (87.5%) than vehicle-treated patients (78.4%).

There was no significant between-group difference for telangiectasia ( $p = 0.979$ ). At the last on-therapy visit, azelaic acid produced a mean reduction of 22.3% in the telangiectasia score, while vehicle produced a 23.5% reduction. The change

Table I. Patient characteristics

Patient characteristics	Azelaic acid	Vehicle
Male/female patients (n)	40/36	15/23
Patients with previous rosacea therapy, n (%)	58 (76.3)	28 (73.7)
Mean age (years)	48.4	50.3
Mean previous duration of rosacea (years)	5.3	6.0
Mean baseline no. of facial inflammatory lesions	30.8	31.7
Mean baseline erythema score <sup>a</sup>	3.6	3.6
Mean baseline telangiectasia score <sup>a</sup>	3.0	2.9

<sup>a</sup>Rated as integer scores from 0 to 6.

in telangiectasia severity was rated as “better” by approximately 54% of both azelaic acid-treated and vehicle-treated patients.

**Overall evaluations**

Azelaic acid treatment resulted in significantly more favourable overall improvements at the last on-therapy assessment visit than did vehicle in both physician ( $p=0.020$ ; Fig. 2A) and patient ratings ( $p=0.042$ ; Fig. 2B). In the physician’s rating, 79.7% of patients in the azelaic acid group achieved either a complete remission or a marked improvement compared with 54.0% in the vehicle group. In patient’s ratings, 82.1% in the azelaic acid group reported either a complete remission or a marked improvement compared with 58.3% in the vehicle group. There were fewer reports of poor results (no improvement or deterioration) with azelaic acid than with vehicle: 6.8% (physician’s rating) and 9.5% (patient’s rating) in the azelaic acid group compared with 27.0% (physician’s rating) and 27.8% (patient’s rating) in the vehicle group reporting poor results.

More patients treated with azelaic acid (64.4%) than with vehicle (42.9%) reported that their medication was better than previous treatments. Furthermore, 89.0% of patients in the azelaic acid group and 88.6% of patients in the vehicle group

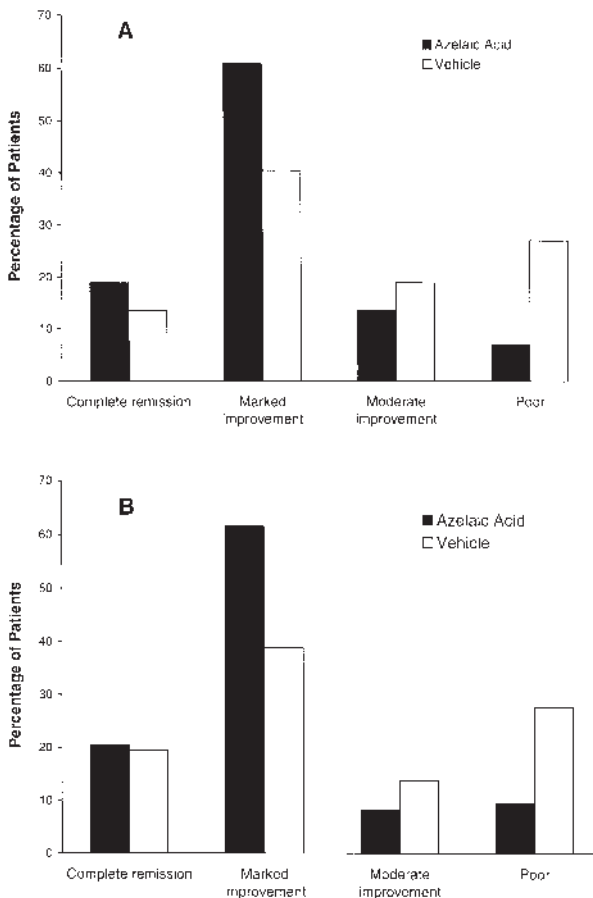


Fig. 2. Overall improvement at the end of therapy. Azelaic acid led to significantly better overall improvement than did vehicle in the investigator rating (A) ( $p=0.020$ ), and in the patient rating (B) ( $p=0.042$ ).

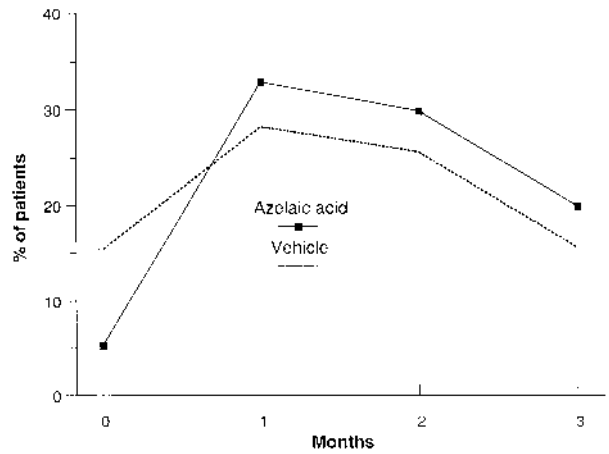


Fig. 3. Incidence rate of local adverse events during the study. In both treatment groups the incidence rate was highest during the first month. Untoward symptoms were also noted prior to treatment.

reported that the cosmetic acceptability of their treatment was very good or good. There were no significant between-group differences for any patient survey results.

**Adverse events**

No serious and no systemic adverse events were reported during the study in either treatment group. There were no significant between-group differences for any adverse event measure reported; cutaneous adverse signs and symptoms were observed in 39.5% of patients (30/76) in the azelaic acid group and 38.5% of patients (15/39) in the vehicle group. In 4 patients (5.3%) of the azelaic acid group and 6 patients (15.4%) allocated to vehicle, local untoward symptoms were noted prior to treatment. The incidence rate was highest during the first month, then decreased throughout the study period (Fig. 3). Most of the local adverse events were rated as “mild” (azelaic acid: 18/30; vehicle: 11/15) or “moderate” (azelaic acid: 7/30; vehicle: 3/15), and the majority of the adverse events for both groups were rated as “transient” in duration. Furthermore, the overall local tolerability of treatment was rated as acceptable or good by 91.7% of azelaic acid-treated patients and 91.4% of vehicle-treated patients.

Table II summarizes treatment-related adverse events.

Table II. Local adverse events (% of patients)

Adverse event	Azelaic acid (%)	Vehicle (%)
Burning	26.3	23.1
Skin irritation	5.3	10.3
Stinging	7.9	2.6
Itching	6.6	7.7
Facial oedema	1.3	0
Eczematous reaction <sup>a</sup>	1.3	0
Scaling	1.3	0
Skin dryness	0	1.3
Skin feels hot	0	1.3
Tightness of skin	0	1.3

<sup>a</sup>Already present at baseline prior to therapy.

Azelaic acid and vehicle produced similar incidence rates of burning, itching, facial oedema, skin dryness, skin feeling hot, tightness of skin and scaling. Burning was the most commonly reported symptom for both groups (azelaic acid, 26.3%; vehicle, 23.1%). Skin irritation was slightly more common in the vehicle group (azelaic acid, 5.3%; vehicle, 10.3%) while stinging was slightly more common in the azelaic acid group (azelaic acid, 7.9%; vehicle, 2.6%).

## DISCUSSION

This study demonstrated the effectiveness and safety of azelaic acid 20% cream in the treatment of papulo-pustular rosacea. Both azelaic acid cream and vehicle led to clinically relevant improvements. While no significant treatment differences were found after the first month of treatment, the statistical analysis showed significant differences favouring azelaic acid cream after the second and in particular after the third month. Thus, significantly greater reductions in inflammatory lesions and erythema (the primary efficacy variables) and significantly better physician's and patient's overall improvement ratings were found with topical azelaic acid. With regard to the single type of inflammatory lesions, treatment differences were evident for papules but not for pustules. The lack of significant treatment difference for the pustules may relate to the relatively low number of lesions in both treatment groups and the possibility of a rupture of the pustules during the application procedure.

Neither treatment produced any major improvement in telangiectasia. This finding was not surprising since there is no known pharmacological basis for an effect of azelaic acid on the underlying vascular component of rosacea. Rather, electrosurgery or laser techniques are the standard treatment strategy for the obliteration of the ectatic vessels (1).

While numerous studies have demonstrated the efficacy and safety of topical azelaic acid in the treatment of acne and hyperpigmentation (4, 5, 9), its significance in rosacea therapy has yet to be defined, due to the paucity of clinical data. An open study by Nazzaro-Porro et al. in 33 rosacea patients (7) showed a progressive reduction in the number of inflammatory lesions and in the severity of erythema; histologically a reduction in epidermal and dermal inflammatory reactions, an absence of very dilated vessels and a reduction in the pathological changes in the perivascular matrix was noted. The results of the present investigation were in good agreement with results of a previous intra-individual split-face comparison of azelaic acid 20% cream and its vehicle, showing significant differences in favour of azelaic acid, both for the decrease in inflammatory lesions, erythema and complete remission or marked improvement (azelaic acid: 78.2%; vehicle: 31.2%). Also here, no effect on telangiectasia was noted (8).

Azelaic acid was safe and was not associated with any serious adverse events. Only 5 patients in the azelaic acid group and 1 patient in the vehicle group were discontinued due to treatment-related local adverse events. As with most topical medications, cutaneous signs and symptoms were observed. The overall incidence rate observed with the vehicle

was equal to that of azelaic acid (approximately 39%), probably reflecting the typically high skin sensitivity of rosacea patients. In fact, it is not uncommon to have a high degree of skin irritation even without rosacea treatment (8). The incidence rate was highest during the first month then decreased throughout the study period, a pattern typical of azelaic acid treatment (9). The majority of patients in both groups experienced only mild or moderate adverse events. The rate of marked local adverse symptoms did not exceed 7% in either group, which is well within the range of 5–10% established in acne patients treated with azelaic acid (9). Furthermore, local tolerability was rated highly in both treatment groups.

In acne, the efficacy of azelaic acid is attributed to its antimicrobial effects on follicular bacteria and its ability to normalize the disturbed follicular keratinization (5). However, in rosacea there is no evidence of bacterial involvement or follicular dyskeratinization. *In vitro* studies have shown that azelaic acid may exert anti-inflammatory effects by inhibiting the formation as well as scavenging neutrophil-generated reactive oxygen radicals (10, 11). Since inflammation is important in the pathogenesis of rosacea, it is possible, therefore, that the anti-inflammatory activity of azelaic acid may account for its beneficial effect in rosacea.

Future clinical studies, including combination with other agents, may contribute to defining an optimal role for azelaic acid in rosacea treatment strategies.

## REFERENCES

1. Wilkins JK. Rosacea: pathophysiology and treatment. *Arch Dermatol* 1994; 130: 359–362.
2. Jansen T, Plewig G. Rosacea: classification and treatment. *J Royal Soc Med* 1997; 90: 144–150.
3. Bleicher PA, Charles JH, Sober AJ. Topical metronidazole therapy for rosacea. *Arch Dermatol* 1987; 123: 609–614.
4. Breathnach AS. Pharmacological properties of azelaic acid. *Clin Drug Invest* 1995; 10 (Suppl 2): 27–33.
5. Fitton A, Goa KL. Azelaic acid. A review of its pharmacological properties and therapeutic efficacy in acne and hyperpigmentary disorders. *Drugs* 1991; 41: 780–798.
6. Graupe K, Cunliffe WJ, Gollnick HPM, Zaumseil R-P. Efficacy and safety of topical azelaic acid (20 percent cream): An overview of results from European clinical trials and experimental reports. *Cutis* 1996; 57: 20–35.
7. Nazzaro-Porro M, Passi S, Picardo M, Balus L, Breathnach AS. L'acido azelaico nella rosacea? *Giornale Italiano di Dermatologia e Venerologia* 1991; 126: 19–27.
8. Carmichael AJ, Marks R, Graupe KA, Zaumseil RP. Topical azelaic acid in the treatment of rosacea. *J Derm Treat* 1993; 4: S19–S22.
9. Gollnick H, Graupe K. Azelaic acid for the treatment of acne: comparative trials. *J Derm Treat* 1989; 1: 27–30.
10. Akamatsu H, Komura J, Asada Y, Miyachi Y, Niwa Y. Inhibitory effect of azelaic acid on neutrophil functions: a possible cause for its efficacy in treating pathogenetically unrelated diseases. *Arch Dermatol Res* 1991; 283: 162–166.
11. Passi S, Picardo M, De Luca C, Breathnach AS, Nazzaro-Porro M. Scavenging activity of azelaic acid on hydroxyl radicals "in vitro." *Free Rad Res Comms* 1991; 6: 329–338.