

Evaluation of the Free-running Ruby Laser for Hair Removal

A Retrospective Study

PETER BJERRING¹, HUGH ZACHARIAE², HANS LYBECKER² and MARC CLEMENT³

¹Department of Dermatology, University Hospital of Aarhus, Denmark, ²The Mølholm-Clinic, Vejle, Denmark, and ³Swansea School of Higher Education, Swansea, UK

The free-running ruby laser has recently been introduced for removal of unwanted hair growth. It is assumed that the mode of action of ruby laser depilation is that of selective photothermolysis of the melanin-rich structures. The present data reflects our results of ruby treatment of 133 patients attending a dermatological laser clinic for hair removal. When success of the laser treatment was defined as greater than 50% hair removal, 59.0% of patients reported successful results after 90 or more days after last treatment. With success defined as greater than 25% hair removal at 90 days, successful treatment was obtained in 75.0%.

Also, the patients evaluated the overall result of their treatments. The percentage of patients who were either "very satisfied" or "satisfied" after 90 days was 64.2%. Only a few side-effects were observed. In general, pain was no clinical problem. No significant scarring was observed. A temporary hypopigmentation was experienced by approximately 10%, but only one patient still had hypopigmentation 90 days after treatment.

Due to variability of hair density as well as anagen and telogen phase durations in different anatomical locations, firm conclusions regarding the long-term effect still cannot be drawn. **Key words:** laser depilation; permanent hair removal; hypertrichosis.

(Accepted August 4, 1997.)

Acta Derm Venereol (Stockh) 1998; 78: 48–51.

Peter Bjerring, Department of Dermatology, Marselisborg Hospital, University Hospital of Aarhus, DK-8000 Aarhus, Denmark.

High-energy ruby laser light can be used for removal of unwanted hair. This phenomenon was discovered independently by Clement and Zaias (1, 2). Excess hair growth in unwanted areas may result from heredity, endocrine disease or drug therapy. Temporary methods of removal include shaving, cold or hot wax depilation, and chemical depilatories that frequently cause contact dermatitis. Electrolysis, which may be permanent, is tedious and usually only partially effective. Regrowth of 15–50% of hair after electrolysis has been reported. Hair removal by laser has been attempted for trichiasis and for grafts obtained from hair-bearing skin. However, destruction of hair follicles based on the theory of selective photothermolysis has not previously been described. Melanin in the hair shafts or follicles or both provides a chromophore absent in the dermis surrounding these follicles. At deeply penetrating wavelengths in the 600 to 1,100 nm region, melanin absorption may therefore be used for selective photothermolysis of hair follicles.

Mode of action of the ruby laser

Based on Monte Carlo computer simulations, the mode of action seems to be the following: red (694 nm) ruby laser light is transmitted through epidermis to dermis, where the light after only a few micrometres is scattered in all directions due to sudden changes of refractive indices of different anatomical structures (fibres, cells, vessels). The absorbing chromophore of the ruby laser wavelength is melanin. Structures such as epidermis, hair shaft and hair bulb are primary targets, while only insignificant absorption occurs in haemoglobins (3). Part of the light enters the hair follicles at different levels and is absorbed in hair melanins and subsequently converted into heat. Melanin in the dermis is normally confined to the hair apparatus, and absorption of red light results in selective heat damage of hairs and surrounding hair follicles. At higher energy levels, a pyrolytic process is initiated and the hairs evaporate instantaneously. In Q-switched mode the ruby laser emits very short pulses in the nano-second range and hence endogenous and artificial pigment granules in the skin will be damaged selectively. This phenomenon has been utilized for tattoo removal (4, 5) and for treatment of benign pigmented lesions (6) for about three decades now, and, to our best knowledge, without long-term side-effects.

Due to the unsynchronized cyclic growth, not all hair follicles will be in the anagen phase (7–12) at the time of treatment. More treatments will therefore be required in the same area to treat all hair follicles while in the anagen phase. Due to the substantial variation in duration of the growth phases in different anatomical locations, the intervals between treatments should be selected according to anatomical region. It is assumed that hairs in the anagen phase are most susceptible to damage by ruby laser treatment.

To date, promising preliminary results have been obtained (13–15) in fair-skinned individuals, but since clinical experience still is limited the question of permanency remains unanswered. Because of the high absorption in epidermis of patients with dark brown or black skin, these should not be offered ruby laser depilation.

In this paper the preliminary results of ruby laser depilation treatments of 133 patients are reported.

MATERIAL AND METHODS

Patients

The study included 133 patients selected for a follow-up interview after having completed a series of ruby laser treatments for hypertrichosis. The subjects for the study were randomly chosen from a total of more than 500 patients treated. Of these selected patients 97.7% were females and the median age was 43 years, range 8–78 years. The patients all belonged to a Caucasian Scandinavian population comprising blonde, red, brown, black, and grey hair as well as

different degrees of skin pigmentation, including various degrees of sun-tan.

Laser equipment

A Chromos 694 depilation ruby laser (SLS/Biophile, Wales, UK) was used for all treatments. The ruby laser was operated in the free running, long pulse mode, and with the shape of the pulse optimized for depilation. The pulse duration could be varied from 0.5–1.0 ms, but all patients participating in the present study were treated with a pulse duration of 0.70 to 0.80 ms. The energy density was adjustable from 10 to 25 J/cm². Skin pigmentation was measured by a reflectance spectrometer (DermaSpectrometer, Cortex Technology, Denmark). The laser energy density was adjusted to the maximum tolerated by the patient's skin pigmentation and measured by an external laser energy meter (Ophir Nova, Ophir, Israel). The spot diameter was 5 mm, and the repetition rate of the laser was 1 Hz.

Treatment regime

Prior to the first treatment, the patients were instructed to refrain from extracting the hairs with tweezers or wax for 1 month. The patients shaved the hairs on the day before treatment so that the hairs would be just visible at the time of treatment. After a pre-treatment interview, which included detailed photography and skin pigmentation measurements, the first treatment was given. The areas treated were: upper lip, cheek, chin/neck, abdomen, thigh, and bikini line. The patients were instructed to return for a touch-up (second) treatment after 2–8 weeks—the actual time interval would depend on the recruitment rate of new hair follicles from the telogen phase back into the anagen phase. The patients were given additional treatment(s) during the following months if further hairs were recruited from the telogen phase after the second treatment. The average number of treatments was 2.2 (range 1–9) and the average treatment area was 28.0 cm². No cooling was applied to the treated skin during or after the laser treatment.

Efficacy evaluation

A post-treatment interview was performed by a trained laser assistant. This comprised basic demographic registrations, including hair colour and skin type referencing. Per cent grey hair, evaluation of percentage hair removed, discomfort or pain experienced during the treatment, side-effects of the treatment, and the patient's overall satisfaction with the treatment were also recorded at the interview. The success rate or efficacy of the treatment was described in two ways: either as greater than 50% hair removal after 90 days or as 25% removal after 90 days. Also, the patients were allocated into two groups having either more than 50% grey hair or less than 50% grey hair.

Statistical analysis

For statistical evaluation of efficacy a logistic regression analysis was performed. For evaluation of the effect of grey hair on the success rate the chi square test was used.

RESULTS

With success defined as greater than 50% hair removal, 59.0% of patients reported successful results for 90 or more days (95% confidence limits: 49.6% to 67.7%). With success defined as greater than 25% removal—also after 90 days—the fraction of patients reporting successful treatment was 75.0% (95% confidence limits: 64.4% to 82.6%).

When efficacy was rated according to the patient's overall evaluation, it was found that 33.5% of patients were "very satisfied" and 30.7% "satisfied" after 90 days.

The anatomical site treated had no influence on the percentage of successful hair removal or overall evaluation of the treatment.

Effect of grey hair

An overall statistically significant inverse correlation between per cent grey hair and the patient's report of successful removal of hair was found ($p=0.003$). When the percentage of grey hair was less than 50%, 69.3% of the patients experienced successful hair removal after 90 days. The success rate decreased to 42.2% among patients with more than 50% grey hair. Also, the fraction of patients who were either "very satisfied" or "satisfied" with the treatment varied inversely with the percentage grey hair ($p=0.003$) (Fig. 1).

When successful hair removal was defined as more than 25% hair removed after 90 days, patients with less than 50% grey hair experienced successful treatment in 79.1% of the cases (95% confidence limits: 68.8% to 86.6%). Patients with more than 50% grey hair had a success rate of 66.9% (51.3% to 79.5%) (Fig. 2).

Side-effects of ruby laser depilation

Ruby laser depilation may be associated with either discomfort or pain. However, none of the patients required any analgesia. Most patients (71.9%) rated the ruby laser depilation procedure as only "slightly painful" or less, while 28.1% rated the procedure to be either moderately painful or very painful. A large proportion of the patients had tried a variety of other depilation methods prior to the ruby laser depilation. More than half of the patients (51.9%) had previously been using the rather painful needle electrolysis. Of these, 79.5% rated the ruby laser depilation as "less than" or "equally painful" compared with needle electrolysis, while patients with no experience with needle electrolysis generally rated the laser treatment as more painful than their previous depilation treatment methods (Fig. 3). The different previous treatments ranged from shaving and use of depilatory creams to extraction of hairs with wax and tweezers.

A weal-and-flare reaction, presumably due to release of local inflammatory mediators in the ruby laser-treated areas, was reported by 34.6% of the patients. On a visual scale

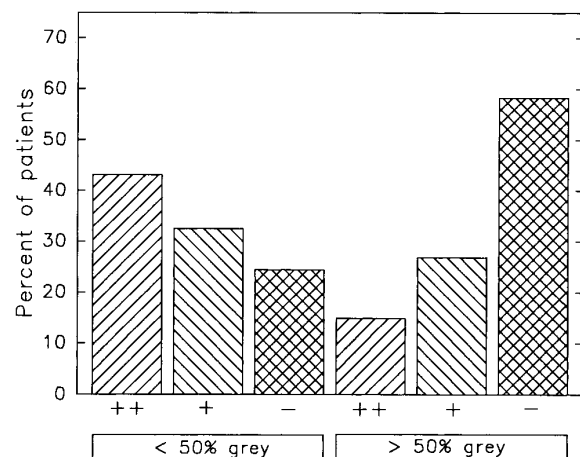


Fig. 1. The influence of grey hairs on ruby laser depilation. Patients' evaluation of the overall treatment result 90 days after ruby laser depilation. (++) : very satisfied, (+) : satisfied, (-) : not satisfied ($n=133$).

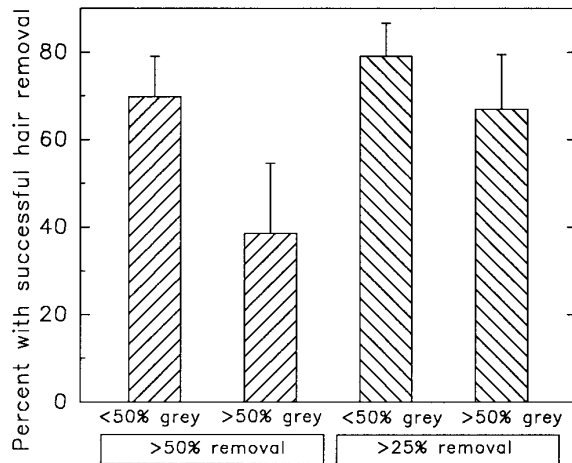


Fig. 2. Patients' evaluation of the overall treatment result 90 days after ruby laser depilation with regard to the influence of grey hairs. Success criteria: either 50% hairs removed or 25% hairs removed ($n=133$).

ranging from 0 to 10 cm these patients rated the swelling intensity to be 2 cm (median rating, range 1–8 cm). In 97.7% of these patients, all swelling and erythema had disappeared within 48 h. Itch was rated on a visual analogue scale (0–10 cm), and 83.5% reported no itch at all. The remaining patients reported only moderate itch (average rating: 2 cm) and most itch (98.5%) subsided within 48 h.

Presumably due to the immediate evaporation of the hairs during the ruby laser treatment, some patients experienced oozing of tissue fluid through the orifices of the hair follicles. A crust of dried tissue fluid on the skin surface may produce a transient brownish discoloration of the treated area. Of all patients, 36.1% did not experience this side-effect, while for the 63.9% who did observe the effect, the median duration was 5 days (range 2–25 days), and the median intensity was 3 cm on a visual analogue scale ranging from 0–10 cm.

Due to the heat-induced inflammation of the hair follicles after ruby laser treatment pigment changes may occur. Among the patients studied 75.9% did not experience any change in pigmentation after the treatments, while 14.3% of the patients reported "hyperpigmentation" and 9.8% hypopigmentation. The duration of the hyperpigmentation was only 7 days (range 1–90 days), leading us to the view that the patients may have misinterpreted the crust formation as hyperpigmentation. Firm data on the incidence and duration of melanocytic pigmentary changes is thus still lacking. The median duration of hypopigmentation was 56 days (21–90 days). At 90 days, none of the patients participating in the study experienced hyperpigmentation and only one patient (12.5%) still had hypopigmentation.

DISCUSSION

It is generally accepted that historically the therapy of idiopathic hirsutism has proven to be disappointing. Where the coarse hairs are relatively few, electrolysis or diathermy in the hands of a fully trained and experienced technician or nurse can be useful. But numerous courses of treatment, often up to thirty, may be necessary. The FDA approval of permanency of electro-depilation—35% of the treated hairs still gone after

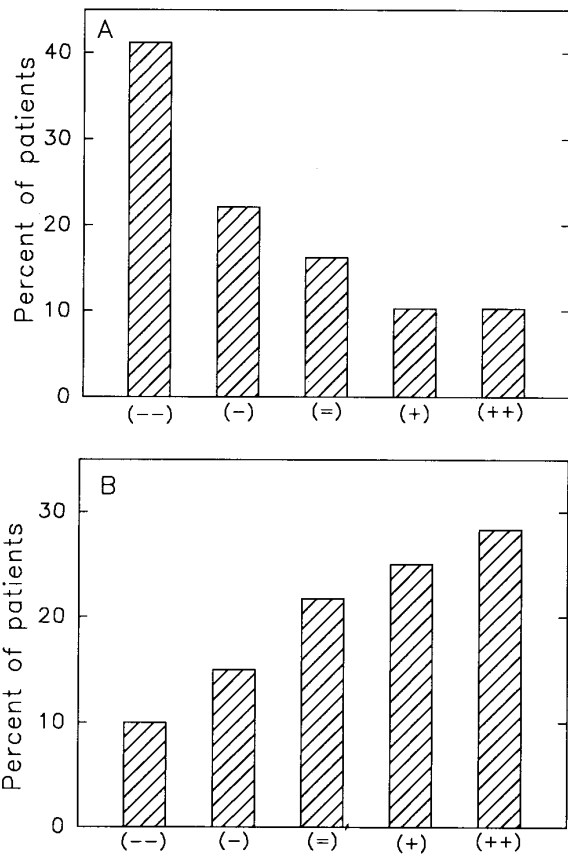


Fig. 3. Pain during ruby laser depilation compared with the pain associated with the patients' different previous depilation treatments. (A) Patients previously treated with painful electrodepilation. (B) Patients who had only had non-invasive, painless treatments before (no electrodepilation). (–): laser treatment much less pain than previous treatment modalities, (–) less pain, (=): equally painful, (+): more painful than previous treatment modalities, (+ +): much more painful than previous treatment modalities.

9 weeks—illustrates the limitations of this type of therapy. Permanent depilation can be achieved by radiotherapy, but only at the expense of a following disfiguring skin damage.

The preliminary results reported here show that hair removal by long-pulse ruby laser light is in many ways promising. Disappearance of more than 50% of the hairs in 59% of the patients after 90 days is a success, when judged by FDA's permanency standard for electrolysis. This standard, however, seems to need reappraisal. The distribution of hairs as well as the duration of anagen and telogen phases vary, as already mentioned, significantly between the anatomical locations (16–26) and also from patient to patient. Observation periods should therefore at least be location-specific or be set in relation to regions with the longest telogen phase, which is around 19 months. In this context, we intend to reevaluate our patients after 24 months.

The side-effects observed in our study were few. Pain was no clinical problem, and pain can be diminished by the use of topical analgesia with EMLA cream (Astra Pharmaceuticals, Södertälje, Sweden). No significant scarring was observed in

any of the patients treated during the study. A temporary hypopigmentation was experienced in approximately 10% of cases but only one patient still had hypopigmentation 90 days after treatment. It should be noted that these observations were recorded in a study that exclusively included Caucasian skin types. Patients with dark brown or black skin will experience enhanced surface light absorption. The effect on those skin types will be the subject of another study planned by this group. The local activation of dormant herpes simplex was observed in only one patient during the study.

It is assumed that the mode of action is that of selective photothermolysis of the melanin-rich structures. With the relatively deep penetration of the ruby laser light, the hair shaft can be reached. Whether a photo-acoustic damage of the hair follicles contributes to the effect is at present unknown. Both the amount of laser energy delivered at the level of the hair follicles, the pulse duration, and the shape of the light pulse seem to be of pivotal importance for the clinical result. Grossman et al. (13) used a rather short pulse duration and hence found primarily a growth delay consistent with induction of a prolonged telogen phase, with permanent hair removal only in some cases.

The limitations of this therapy are evident in patients with lightly pigmented hair, whether grey, white, yellow or red. In the present study, patients with mixtures of different degrees of pigmented hair and grey hair were studied. When more than 50% grey hair was present, the success rate dropped from approximately 70% to approximately 40%. It was also observed that previously electro-epilated or tweezers-treated, scarred areas needed higher laser energy for successful therapy, probably due to a lower light transmittance through the scar tissue. It should also be remembered that skin sites with a high proportion of hairs in the telogen phase, i.e. arms and legs, require repeated treatments long after the initial treatment.

It is concluded that the ruby laser has an advantage, compared to previous depilatory methods, when hairs are dark and the skin is only lightly pigmented. The patients' satisfaction was high in our study. More clinical data is, however, needed to describe the long-term effect of this new technique, and further investigations are in progress.

ACKNOWLEDGEMENT

T. Blake and K. Callahan are acknowledged for their help with the statistical analyses.

REFERENCES

- Clement M. Depilation by ruby laser. PCT patent application GB94/02682.
- Zaias N. Method of hair depilation. U.S. Patent 0,059,192, 1991.
- Anderson RR, Parrish JA. Selective photothermolysis: precise microsurgery by selective absorption of pulsed radiation. *Science* 1983; 220: 524–527.
- Kilmer SL, Anderson RR. Clinical use of the Q-switched ruby and the Q-switched Nd:YAG (1064 nm and 532 nm) lasers for treatment of tattoos. *J Dermatol Surg Oncol* 1993; 19: 330–338.
- Goldman L, Hornby P, Meyer R. Radiation from a Q-switched laser with a total output of 10 megawatts on a tattoo of a man. *J Invest Dermatol* 1965; 44: 69.
- Taylor CC, Anderson RR. Treatment of benign pigmented epidermal lesions by Q-switched ruby laser. *J Invest Dermatol* 1993; 32: 908–912.
- Kligman AM. The human hair cycle. *J Invest Dermatol* 1959; 33: 307.
- Bosse K. Vergleichende Untersuchungen zur Physiologie und Pathologie des Haarwechsels unter besonderer Berücksichtigung seiner Synchronisation. II. Methodische Untersuchungen zur Haarwechselstatusbestimmung und ihre Anwendung an Mensch und Meerschweinchen. *Hautarzt* 1967; 18 :35.
- Braun-Falco O. Dynamik des normalen und pathologischen Haarwachstum. *Archiv für klinische und experimentelle Dermatologie* 1966; 227: 419.
- Straile WE, Chase HB, Arsenault C. Growth and differentiation of hair follicles between periods of activity and quiescence. *J Exp Zoo* 1961; 148: 205.
- Sato Y. The hair cycle and its control mechanism. In: Koboti T, Montagna W, eds. *Biology and disease of the hair*. Baltimore: University Park Press; 1986.
- Randall VA, Ebling FJG. Seasonal changes in human hair growth. *Br J Dermatol* 1991; 124: 146.
- Grossman MC, Dierickx, C, Farinelli W, Flotte T, Anderson RR. Damage to hair follicles by normal-mode ruby laser pulses. *J Am Acad Dermatol* 1996; 35: 889–894.
- Grossman M, Anderson RR. Laser targeted at hair follicles. Annual Conference of the American Society for Lasers in Medicine and Surgery, April 1995 (Abstract).
- Bjerring P. The ruby laser for depilation. Fifth Congress of the European Academy of Dermatology and Venereology, Lisbon, Oct. 1996 (Abstract).
- Beek CH. A study on the extension and distribution of the human body hair. *Dermatologica* 1950; 101: 317.
- Lunde O. A study of body hair density and distribution in normal women. *Am J Phys Anthropol* 1984; 64: 179.
- Myers RJ, Hamilton JB. Regeneration and rate of growth of hair in man. *Ann NY Acad Sci* 1951; 53: 862.
- Pecoraro V, Astore I, Barman JN. Growth rate and hair density of the human axillae. *J Invest Dermatol* 1970; 56: 362.
- Saitoh M, Uzuka M, Sakamoto M. Human hair cycle. *J Invest Dermatol* 1970; 54: 65.
- Witzel M, Braun-Falco O. Über den Haarwurzelstatus am menschlichen Capillitium unter physiologischen Bedingungen. *Archiv für klinische und experimentelle Dermatologie* 1963; 216: 221.
- Shah PN. Human body hair—a quantitative study. *Am J Obst Gynecol* 1957; 73: 1255.
- Szabo G. The regional frequency and distribution of hair follicles in human skin. In: Montagna W, Ellis RA, eds. *The biology of hair growth*. New York: Academic Press; 1958.
- Atkinson SC, Cormia FE, Unrau SA. The diameter and growth phase of hair in relation to age. *Br J Dermatol* 1959; 71: 309.
- Barth JH. Measurement of hair growth. *Clin Exp Dermatol* 1986; 11: 127.
- Seago SV, Ebling FJG. The hair cycle on the human thigh and upper arm. *Br J Dermatol* 1985; 113: 9.