

Expression of Endoglin in the Transition between Psoriatic Uninvolved and Involved Skin

P. C. M. VAN DE KERKHOF, H. F. C. RULO, J. P. A. VAN PELT, I. M. J. J. VAN VLIJMEN-WILLEMS and E. M. G. J. DE JONG

Department of Dermatology, University Hospital Nijmegen, The Netherlands

Endoglin is a glycoprotein which is predominantly expressed on endothelial cells. It is upregulated under inflammatory conditions as well as in skin lesions where endothelial cell proliferation occurs. Endoglin has the capacity to bind transforming growth factor beta (TGF- β) and can reduce the bioavailability of TGF- β . TGF- β has a growth-inhibiting effect on keratinocytes and a restraining influence on the extravasation of peripheral white blood cells.

In order to find out how endoglin is expressed in the margin zone of psoriatic plaques and how it correlates with the appearance of an inflammatory infiltrate, punch biopsies were taken from the margin zone of actively spreading psoriatic plaques in 8 patients. Indirect immunoperoxidase staining was performed using PAL-E (vascular endothelium), PN-E2 (anti-endoglin) and T11 (T-lymphocytes).

In all patients it was found that the appearance of parakeratosis correlated with a clear increase of PN-E2 expression. PAL-E and PN-E2 expression was assessed, using a 5-point scale. Thus a tendency to decreased PN-E2 expression in uninvolved skin compared to PAL-E expression was found within the margin zone (1.6 ± 0.4 and 2.2 ± 0.4 , respectively), whereas in involved skin PN-E2 expression and PAL-E expression were in agreement (2.6 ± 0.5 and 2.6 ± 0.5 respectively), suggesting that in the overt plaque all endothelium is in a so-called activated state. Also correlating with PN-E2 expression was the appearance of a huge dermal lymphocytic infiltrate and epidermal T-lymphocytic expression.

The present study lends further support for a permissive role of endoglin expression in the development of the psoriatic lesion.

(Accepted June 23, 1997.)

Acta Derm Venereol (Stockh) 1998; 78: 19–21.

P. C. M. van de Kerkhof, Department of Dermatology, University Hospital Nijmegen, PO Box 9101, NL-6500 HB Nijmegen, The Netherlands.

Endoglin is a glycoprotein, present on the luminal membrane of dermal endothelial cells, activated monocytes and macrophages (1). It is involved in adhesion processes and has the capacity to bind transforming growth factor beta (TGF- β) (1, 2). It binds TGF- β_1 and TGF- β_3 with high affinity but has virtually no affinity for TGF- β_2 (2). TGF- β has a restraining effect on the extravasation of peripheral white blood cells and inhibits epidermal proliferation (3–6). Endoglin expression has been reported to be considerably upregulated in conditions characterized by cutaneous inflammation and endothelial cell proliferation (7). Therefore, a decreased availability of TGF- β under these conditions might be an inflammation-enhancing factor.

Psoriasis is characterized by epidermal hyperproliferation, premature keratinization and cutaneous inflammation, with accumulation of T-lymphocytes, polymorphonuclear leuko-

cytes, monocytes and macrophages. In psoriasis angiogenesis occurs as well. In the symptomless skin, however, immediately outside the sharply demarcated lesion, no major inflammatory changes are observed histologically. In the distant, clinically uninvolved skin the activity of phospholipase A₂, the rate-limiting step in the production of inflammatory eicosanoids, is increased, as well as the production of leukotriene B₄ (LTB₄). Nevertheless, the inflammatory response to epicutaneous application of LTB₄ has been reported to be decreased (8–11).

Therefore, in addition to pro-inflammatory events also anti-inflammatory principles exist in the symptomless skin.

In a previous communication we reported on the distribution of endoglin expression in lesional and distant, clinically uninvolved skin. In contrast to its increased expression in lesional skin, a markedly reduced expression in the distant, clinically uninvolved skin was observed (12). If endoglin acts as a scavenger by decreasing the biological availability of TGF- β , this implies decreased availability of TGF- β in the lesional skin and increased availability of TGF- β in the distant, clinically uninvolved skin. This would functionally imply enhancement of inflammation in the lesional skin and inhibition of inflammation in the distant, clinically uninvolved skin.

It is attractive to hypothesize that the sharp demarcation of the psoriatic lesion is caused by the dual role of the expression of endoglin as an inflammation-enhancing factor in the lesion and an anti-inflammatory factor in the symptomless skin.

In the present study the expression of endoglin in the margin zone of spreading psoriatic plaques was studied in order to find out:

- Whether the transition between decreased expression and increased expression of endoglin is sharply demarcated or more gradual.
- In which stage of the transition from uninvolved into clinically involved psoriatic skin the change of endoglin occurs.

MATERIALS AND METHODS

Patients

Eight psoriatic patients (5 males and 3 females) participated in the present study, after giving informed consent. The patients had a mean age of 47 years and the extent of their lesions was less than 5% of the body surface. They had received no topical antipsoriatic treatment for at least 2 weeks and no systemic treatment for at least 1 year. In every patient an actively spreading lesion was selected, characterized by pinpoint papules just outside the lesion, and/or a previous history of expansion of the lesion during the previous 2 weeks.

Biopsies

In each patient one single punch biopsy (6 mm diameter) was taken across the border of the psoriatic lesion after infiltration with a local anaesthetic. All biopsy specimens were embedded in Tissue Tek OCT

compound (Miles Scientific, Naperville, USA), snap-frozen in liquid nitrogen and stored at -80°C until use. Subsequently, 7- μm frozen sections were cut and fixed in acetone for 10 min.

Immunohistochemistry

In order to visualise the vascular endothelium, without staining the lymphatic vessels, PAL-E, a monoclonal antibody, diluted 1:25 (Department of Pathology, University Hospital Nijmegen, the Netherlands), was used (13, 14). For the assessment of endoglin expression, the monoclonal antibody PN-E2, diluted 1:25 (Department of Pathology, University Hospital Nijmegen, the Netherlands), was used. Pan T-lymphocytes were stained by the monoclonal antibody DAKO-T11, diluted 1:100 (Dakopatts, Copenhagen, Denmark).

Slides were rehydrated in phosphate-buffered saline (PBS) and then incubated with the monoclonal antibody for 60 min. After three washes in PBS they were incubated for 30 min with peroxidase-conjugated rabbit-antimouse antibody (RAMPO, Dakopatts, Copenhagen, Denmark). Three more washes preceded a pre-incubation with sodium acetate buffer (pH 4.9), after which the slides were stained with freshly prepared 3-amino-9-ethyl-carbazole 200 mg/l in sodium acetate buffer and 0.01% H_2O_2 (AEC solution). All slides were finally washed with demineralized water, counterstained with Mayer's haematoxylin (Sigma, St. Louis, MO) and mounted in glycerin gelatin.

Slides were studied by light microscopy and the staining pattern was assessed at the papillary and subpapillary region of the dermis, using a 5-point scale. Staining area, but not staining intensity, was scored.

RESULTS

In the more central part of the margin zone ("involved") the architecture was psoriasiform with parakeratosis, acanthosis and a mixed inflammatory infiltrate. In the more distal part ("uninvolved") the architecture was that of normal skin. The transition between involved and uninvolved psoriatic skin was sharp with respect to the transition between orthokeratosis and parakeratosis but more gradual with respect to acanthosis and infiltrate formation.

The staining results of PAL-E and PN-E2 are summarized in Table I. It can be seen that in the involved part of the margin zone the density of the PN-E2-positive vascular endothelium approximated the density of vascular endothelium, as visualized by PAL-E. In contrast, PN-E2 staining was markedly reduced in the uninvolved part of the margin zone. Although the differences within the margin zone between the "involved" and "uninvolved" parts are substantial, no statistical significance was reached at the number of 8 patients. The transition between the involved and uninvolved part of the

Table I. Assessment of PAL-E and PN-E2 positive area in the margin of the spreading psoriatic plaque (mean \pm SEM)

	Margin zone			
	Involved		Uninvolved	
	Papillary	Subpapillary	Papillary	Subpapillary
PAL-E staining	2.6 \pm 0.5	2.4 \pm 0.2	2.2 \pm 0.4	2.0 \pm 0.3
PN-E2 staining	2.6 \pm 0.5	2.1 \pm 0.2	1.6 \pm 0.4	1.6 \pm 0.2

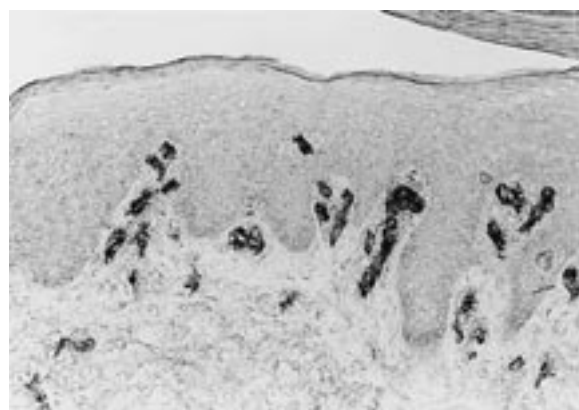
"Involved" implies the more central area of the margin zone, characterized by parakeratosis. "Uninvolved" implies the more peripheral part of the margin zone, characterized by orthokeratosis.

margin zone comprised only a few papillae. PN-E2 staining in the margin zone is visualized in Fig. 1. The appearance of a pronounced dermal infiltrate of T-lymphocytes and epidermal accumulation of these cells correlated with the PN-E2 expression.

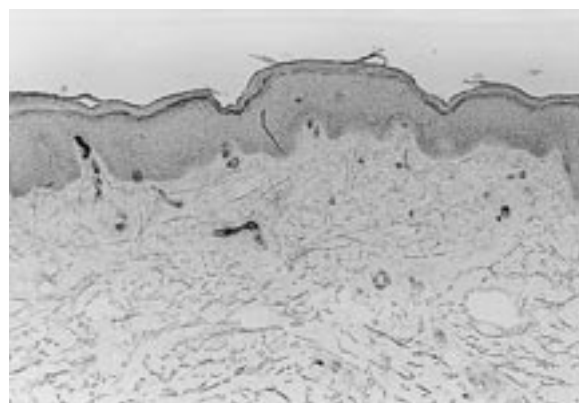
DISCUSSION

In normal skin of healthy volunteers, and also in the psoriatic plaque, the ratio of PAL-E-positive endothelium to PN-E2-positive endothelium was 1:1 (12).

In a previous communication it has been reported that the expression of PAL-E, indicating total vascular endothelium, was reduced in the distant, clinically uninvolved skin. In addition, less endothelium expressing endoglin was demonstrated in the distant, clinically uninvolved skin as compared to normal skin (12). The relatively reduced expression of endoglin in the distant, clinically uninvolved skin proved to advance into the margin zone of the spreading lesion, showing an abrupt transition into a marked expression, in the "involved part" of the margin zone. The transition from normal into acanthotic epidermis, from orthokeratosis into parakeratosis and from low-density into high-density lymphocytic infiltration coincides with this abrupt transition of endoglin expression.



a



b

Fig. 1. PN-E2 expression in the margin zone of the psoriatic plaque. (a) "Involved part" (100 \times). (b) "Uninvolved part" (75 \times).

However, a major reduction of vascular endothelium (PAL-E-positive cells) does take place in the distant, uninvolved skin as compared to the skin of normal volunteers (12). The expression of PAL-E in the uninvolved part of the margin zone approaches the markedly increased expression in the lesional skin.

Increased bloodflow, increased alkaline phosphatase activity and increased tenascin expression in an annular zone around the psoriatic plaque indicate early involvement of the microvasculature and stroma in the development of the lesion (15–17).

The sharp demarcation of the psoriatic plaque is reflected in a sharp transition of endoglin expression. It is attractive to speculate that within the lesion the relatively high expression of endoglin decreases the availability of TGF- β , hence enhancing inflammation. In contrast, the decreased expression of endoglin in the distant, uninvolved skin is likely to result in increased TGF- β levels and hence might counteract inflammatory stimuli.

REFERENCES

- Gougos A, St Jaques S, Greaves MA, O'Connell PJ, d'Apice AJF, Bühring HJ, et al. Identification of distinct epitopes of endoglin, an RGD-containing glycoprotein of endothelial cells, leukemic cells and syncytiotrophoblasts. *Int Immunol* 1992; 4: 83–92.
- Cheifetz S, Bellón T, Calés C, Vera S, Bernabeu C, Massagué J, et al. Endoglin is a component of the TGF- β receptor system in human endothelial cells. *J Biol Chem* 1992; 267: 19027–19030.
- Cai JP, Falanga V, Tailor JR, Chin Y-H. Transforming growth factor β differentially regulates the adhesiveness of normal and psoriatic dermal microvascular endothelial cells for peripheral blood mononuclear cells. *J Invest Dermatol* 1992; 98: 405–409.
- Hendriksen R, Gobl A, Wilander E, Oberg K, Miyazono K, Funai K. Expression and prognostic significance of TGF- β isotypes, latent TGF- β binding protein, TGF- β type I and type II receptors, and endoglin in normal ovary and ovarian neoplasms. *Lab Invest* 1995; 73: 213–220.
- Yamada N, Kato M, Yamashita H, Nister M, Miyazono K, Heldin CH, et al. Enhanced expression of transforming growth factor- β and its type-I and type-II receptors in human glioblastoma. *Int J Cancer* 1995; 62: 386–392.
- Szekanecz Z, Haines GK, Harlow LA, Shah MR, Fong TW, Fu R, et al. Increased synovial expression of transforming growth factor (TGF)- β receptor endoglin and TGF- β I in rheumatoid arthritis; possible interactions in the pathogenesis of the disease. *Clin Immunol Immunopathol* 1995; 76: 187–194.
- Westphal JR, Willems HW, Schalkwijk CJM, Ruiter DJ, de Waal RMW. A new 180 KD dermal endothelial cell activation antigen: in vitro and in situ characteristics. *J Invest Dermatol* 1993; 100: 27–34.
- Forster S, Ilderton E, Summerley R, Yardley H. The level of phospholipase A₂ activity is raised in the uninvolved epidermis of psoriasis. *Br J Dermatol* 1983; 108: 103–106.
- Ziboh VA, Casebolt TL, Marcelo CL, Voorhees JJ. Biosynthesis of lipoxygenase products by enzyme preparations from normal and psoriatic skin. *J Invest Dermatol* 1984; 83: 426–430.
- Wong E, Camp RD, Derm FF, Greaves MW. The responses of normal and psoriatic skin to single and multiple topical applications of leukotriene B₄. *J Invest Dermatol* 1985; 84: 421–423.
- Lammers AM, van de Kerkhof PCM. Response of polymorphonuclear leukocytes to topical leukotriene B₄ in healthy and psoriatic skin. *Br J Dermatol* 1987; 116: 521–524.
- Rulo HFC, Westphal JR, van de Kerkhof PCM, de Waal RMW, van Vlijmen IMJJ, Ruiter DJ. Expression of endoglin in psoriatic involved and uninvolved skin. *J Derm Sci* 1995; 10: 103–109.
- Ruiter DJ, Schlingemann RO, Rietveld FJR, de Waal RMW. Monoclonal antibody defined human endothelial antigens as vascular markers. *J Invest Dermatol* 1989; 93: 25S–32S.
- Schlingemann RO, Dingjan GM, Emeis JJ, Blok J, Warnaar SO, Ruiter DJ. Monoclonal antibody PAL-E specific for endothelium. *Lab Invest* 1985; 52: 71–76.
- Kerkhof van de PCM, van Rennes H, de Grood R, Bauer FW, Mier PD. Metabolic changes at the margin of the spreading psoriatic lesion. *Br J Dermatol* 1983; 108: 647–652.
- Jong de EMGJ, Schalkwijk J, van de Kerkhof PCM. Epidermal proliferation and differentiation, composition of the inflammatory infiltrate and the extracellular matrix in the margin of the spreading psoriatic lesion. *Eur J Dermatol* 1991; 1: 221–227.
- Hull MS, Goodfield M, Wood EJ, Cunliffe WJ. Active and inactive edges of psoriatic plaques: identification by tracing and investigation by laser-Doppler flowmetry and immunohistochemical techniques. *J Invest Dermatol* 1989; 92: 782–785.