

Adnexal Polyp of Neonatal Skin Observed Beyond the Neonatal Period

Sir,

Adnexal polyp of neonatal skin is a small tumor occurring mostly on the areola of the nipple (1). It is observed in about 4% of Japanese newborns. The polyp usually falls off spontaneously within a week after birth. Persistent congenital skin changes on the breast are supernumerary breasts or nipples, amastia (absent breast) and rudimentary nipples. The incidence of supernumerary breasts or nipples is about 2%. The accessory nipple often looks like nevus pigmentosus, although in some cases it can be easily recognized as a nipple. We report two patients with adnexal polyps of neonatal skin that remained for a longer time.

CASE REPORT

Case 1: A 53-day-old male infant was presented to us with two tumors on the breast present since birth. The day before the visit to our clinic, one of them became blackish. Polypoid pedunculated nodules about 1 mm in diameter were on the inner side of both areolae. The tumor on the right breast was a skin-coloured elastic firm tumor (Fig. 1). Since the tumor on the left was firm, dry and blackish, it was considered to be a condition of dry gangrene. The black tumor fell off in a few days. The tumor on the right breast was histologically examined and the diagnosis was confirmed.

Case 2: A 370-day-old female infant had a tumor on the right breast from birth. No change occurred till just before she visited our clinic. On the right areola near the nipple, there was a skin-coloured polypoid pedunculated tumor about 1 mm in diameter (Fig. 2).

The skin-coloured tumors in both cases were histologically examined, with similar findings. The epidermis was normal. In the center of the tumor, a hair follicle was present (Fig. 3). No hair was contained. Collagen bundles with fibroblasts and nests of squamous cells surrounded the follicles. Epithelial strand budding from the follicles, obvious sebaceous glands or sweat glands were not present. Small vessels were noticed in the loose fibrous tissue. No smooth muscle bundles or lactiferous ducts were found.

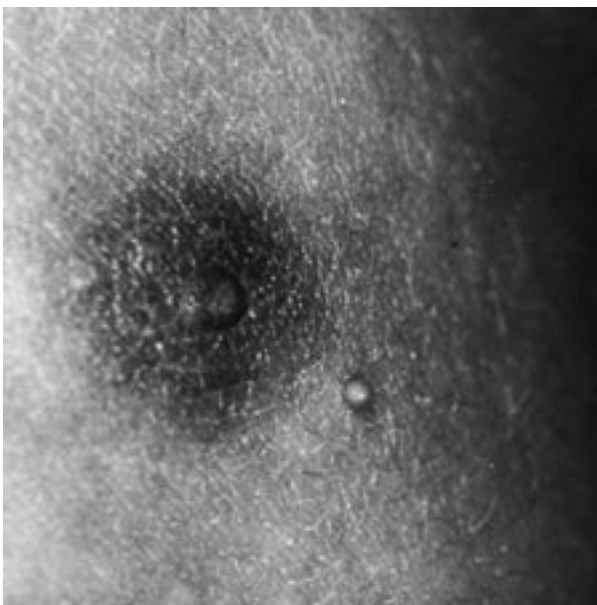


Fig. 1. Polyps on the right breast of case 1.

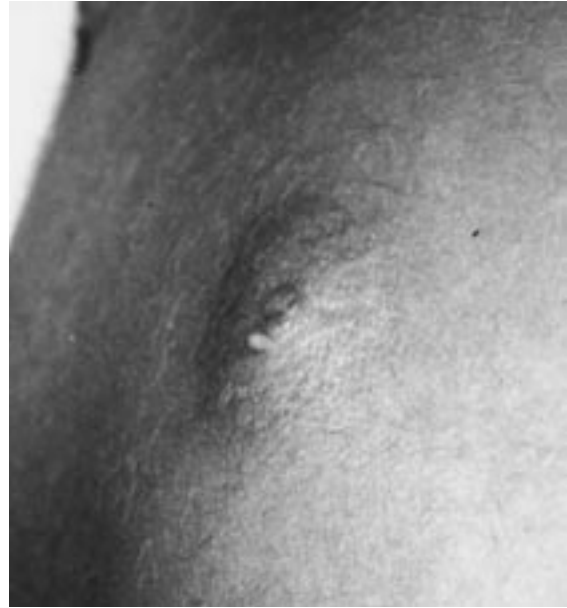

Fig. 2. Polyps on the breast of case 2.

DISCUSSION

The characteristics of the adnexal polyp of neonatal skin have been summarized as follows (1): (i) it is a small, usually solitary tumor of the skin observed exclusively in the newborn infant; (ii) the majority of tumors are found on the areola of the nipple; (iii) within a few days, the tumors fall off spontaneously; (iv) microscopically, hair follicles, vestigial sebaceous glands and sweat glands are noted in the center of the tumor. Adnexal polyps of neonatal skin are observed in about 4% of Japanese newborns (1, 2). In Hidano's reports, one black infant from Zaire was also described. Sedlackek et al. reported that 0.7% of newborns had adnexal polyps of neonatal skin in Czechoslovakia (3). The incidence seems to be lower in Europeans than in Japanese. Rohr reported that skin tags were found in 0.2% of 3-day-old

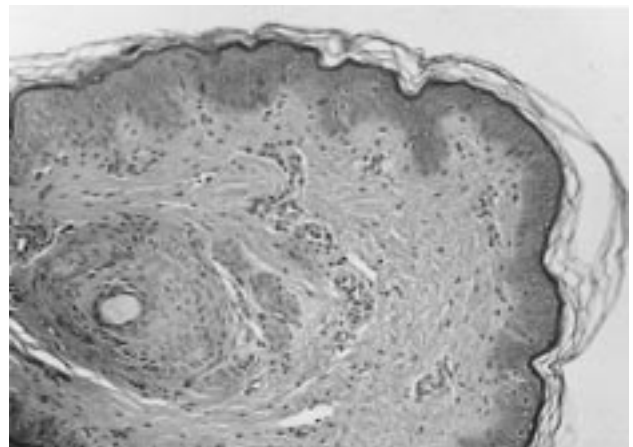


Fig. 3. Case 2. Hair follicle and nests of squamous cells in the center of the tumor (haematoxylin and eosin: ×50).

infants in Australia, although no adnexal polyps were noted (4). In Rohr's study, no histological examination was performed, so the skin tags he noticed might have been adnexal polyps of neonatal skin.

The histological findings matched those of the adnexal polyp; however, sebaceous glands and sweat glands were not identified. Only nests of squamous cells surrounded the follicles. For diagnosis, accessory auricles, skin tags, and supernumerary nipples (polythelia) should be considered. The accessory auricle is different from the adnexal polyp of neonatal skin histologically and clinically. In skin tags, skin appendages are not contained; skin tags can also appear in adults. Although polythelia is congenital and appears near the areola, smooth muscles and lactiferous ducts are characteristic histological features (5).

The unusual feature of our cases is the longer existence of the adnexal polyps. The adnexal polyp of neonatal skin is said to be easily removable using the fingertip, followed by bleeding. Within a week after birth, the tumors fall off spontaneously. It is reported that just one 26-day-old infant had a longer-lasting tumor (1). Our findings demonstrate that adnexal polyps can be present in infants older than one

week. The adnexal polyp of neonatal skin should be considered one of the small tumors seen on the trunk of infants, not only in neonates.

REFERENCES

1. Hidano A, Kobayashi T. Adnexal polyp of neonatal skin. *Br J Dermatol* 1975; 92: 659–662.
2. Hidano A, Purwoko R, Jitsukawa K. Statistical survey of skin changes in Japanese neonates. *Ped Dermatol* 1986; 3: 140–144.
3. Sedlackek V, Chejovska A, Khun K. Adnexal polyp on neonatal skin. *Ceskoslovenska Dermatologie* 1978; 53: 394–397.
4. Rohr JB. The skin of the newborn. *Aust J Dermatol* 1975; 16: 118–120.
5. Saunders TS. Supernumerary nipple (polythelia). In: Demis DJ, ed. *Clinical Dermatology*, Vol. 4. Philadelphia/New York: Lippincott-Raven, 1995; unit 27-3.

Accepted March 23, 1998.

Hiroko Koizumi, Eri Itoh and Akira Ohkawara
Department of Dermatology, Hokkaido University School of Medicine, Kita 15 Nishi 7, Kita-ku, Sapporo, 060, Japan.

Erythema Multiforme Combined with Legionellosis

Sir,

Infections often cause erythema multiforme, and more rarely, drugs are the cause. We describe a case of erythema multiforme occurring in the course of *Legionella pneumophila* (LP) infection.

CASE REPORT

A 56-year-old man was admitted for a febrile eruption, principally involving the buccal and genital areas, and cough. He was a chronic alcoholic and heavy smoker, and had alcoholic cirrhosis. In spite of antibiotic treatment (amoxicillin + clavulanic acid) for 5 days, fever persisted at 40°C.

Dermatologic examination showed crusted hemorrhagic lip erosions, oral erosions, and crusted erosions of the scrotum. Lung examination revealed cough, crepitations at the bases of both lungs, hypoxemia (pO₂: 74 mmHg), hypocapnia (pCO₂: 31 mmHg), and an interstitial syndrome on the chest X-ray. His general state of health had deteriorated, and he had mental confusion and epigastralgia.

Blood tests showed hyperleukocytosis (15 200/mm³ with 84% polymorphonuclear cells) and raised C-reactive protein (118 mg/l, normal <8 mg/l). Natriemia, creatininemia and liver function tests were normal. Blood and urine bacterial cultures were negative, and stool examination revealed no pathogens. Serodiagnosis for HIV, chlamydia, rickettsiosis, HSV and mycoplasma were negative or showed previous immunization. The first *Legionella pneumophila* serology was negative, and then seroconversion occurred (titre 1/128).

The patient was treated with spiramycin for 8 days, without success, and then with fluoroquinolon (ciprofloxacin 1 g/24h). Breathing difficulties disappeared after 3–4 days. The mucous lesions disappeared within 15 days.

DISCUSSION

The patient had erythema multiforme with mucosal involvement occurring in Legionnaire's disease. The diagnosis of

Legionella pneumophila infection was established on the basis of the breathing disorder, fever, pneumonia, chest X-ray and seroconversion for LP.

LP infection is only exceptionally linked with cutaneous lesions. In fact, only one case of cutaneous abscess has been described in an immunosuppressed patient (1), one case of pretibial rash (2), and one case of rash and renal failure (3). Only one other case of Legionnaire's disease combined with erythema multiforme has been described in a 3-year-old boy (also with seroconversion) (4).

The possibility of LP infection should be eliminated when erythema multiforme is combined with breathing disorder.

REFERENCES

1. Ampel NM, Ruben FL, Norden CW. Cutaneous abscess caused by legionella micdadei in an immunosuppressed patient. *Ann Intern Med* 1985; 102: 630–632.
2. Helms LM, Johnson W, Donaldson MF, Corry RI. Pretibial rash in *Legionella pneumophila* pneumonia. *JAMA* 1981; 245: 1758–1759.
3. Allen TP, Fried JS, Wiegmann TB, Hodges GR, Dixon AY, Lee SH, et al. Legionnaire's disease associated with rash and renal failure. *Arch Intern Med* 1985; 145: 729–730.
4. Andersen R, Bergan T, Halvorsen K, Kallings I, Orstavik I. Legionnaire's disease combined with erythema multiforme in a 3-year-old-boy. *Acta Paediatr Scand* 1981; 70: 427–430.

Accepted March 23, 1998.

C. Toledano¹, L. Machel¹, N. Gironet¹, V. Jan¹, N. Van der Mee-Marquet², L. Vaillant¹ and G. Lorette¹

¹Department of Dermatology, Hôpital Trousseau, CHU Tours, F-37044 Tours Cedex and ²Department of Bacteriology, Hôpital Trousseau, CHU Tours, F-37044 Tours Cedex, France.