

The So-called Striated Muscle Hamartoma is a Hamartoma of Cutaneous Adnexa and Mesenchyme, But Not of Striated Muscle

Sir,

Striated muscle hamartoma or rhabdomyomatous mesenchymal hamartoma is a rare benign papillomatous lesion occurring on the face and neck that is usually present from birth. It has been reported in different races in males and females. Histopathologically, the lesion consists of a core of fibroadipous tissue covered by a normal epidermis and containing abundant hair follicles, sebaceous and eccrine glands, nerve fibres, blood vessels, and mature striated muscle, in the form of individual fibres penetrating into the dermis and arranged perpendicularly to the epidermis. Some patients with striated muscle hamartoma have Delleman's syndrome, a recently described syndrome characterized by ocular cysts, cerebral malformations, focal cutaneous hypoplasia and accessory skin appendages (1). The presence of striated muscle has been considered its most characteristic histopathologic finding, and therefore the name "striated muscle hamartoma" has been the most frequent denomination for this lesion. In our opinion, striated muscle is a normal component of the dermis in some cutaneous areas of the face, the same areas where this hamartoma is located. For this reason, we believe that "striated muscle hamartoma" is a misnomer, and that hamartoma of adnexa and mesenchyme is the most appropriate denomination for this entity. We present herein an additional example of this hamartoma.

CASE REPORT

A 9-year-old white boy was referred to our department because of an asymptomatic lesion on his nose that had been present since birth.

Examination revealed a 0.5 × 0.3-cm papillomatous skin-coloured pedunculated lesion at the opening of his right nostril, covered by apparently normal skin. Its size had increased only according to the child's growth.

The patient had an unaffected univitelline twin brother. No other

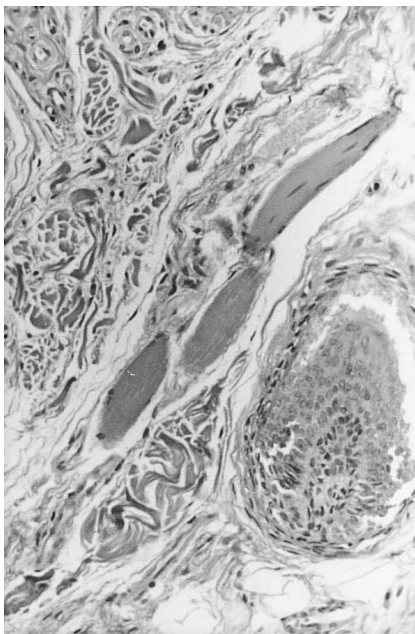


Fig. 1. Detail of the lesion showing striated muscle fibers.

relevant history was recorded. The lesion was excised with no recurrences and with a good cosmetic outcome. Further physical examination, an ophthalmologist consultation and a cerebral CT disclosed no abnormalities. Therefore Delleman's syndrome was ruled out.

The histopathologic study demonstrated an exophytic and pedunculated lesion covered by normal epidermis. The central core of the lesion contained numerous folliculo-sebaceous units, many blood vessels, nerves and some striated muscle fibers arranged perpendicularly to the epidermis (Fig. 1). Cutaneous adnexa appeared mature and structurally normal, but they were arranged haphazardly; some of them were too superficial and too close to the epidermis, whereas others were positioned too deep in the dermis. Immunohistochemical analysis revealed striated muscle fibres which were Desmin positive.

DISCUSSION

Striated muscle hamartoma was originally described in 1986 by Hendrick et al. (2). In our review of the literature, we found 13 additional examples of this hamartoma, including the one reported here. To describe examples of this hamartoma, different names have been used, including rhabdomyomatous mesenchymal hamartoma of the skin, congenital rhabdomyomatous mesenchymal hamartoma, congenital midline hamartoma, and striated muscle hamartoma (3).

Striated muscle is a normal component of the dermis in the skin of some areas of the face and neck (4). We think that "hamartoma of adnexa and mesenchyme" is a better term because it describes adequately the components of the hamartoma.

The problem is that the term "cutaneous hamartoma of adnexa and mesenchyme" has already been used by Fogt & Tahan (5) to describe a variant of folliculosebaceous cystic hamartoma (6) with a prominent vascular component.

REFERENCES

1. Delleman JW, Oorthuys JWE. Orbital cyst in addition to congenital cerebral and focal dermal malformations: a new entity? *Clin Genet* 1981; 19: 191–198.
2. Hendrick SJ, Sanchez RL, Blackwell SJ, Raimer SS. Striated muscle hamartoma: description of two cases. *Pediatr Dermatol* 1986; 3: 153–157.
3. Sánchez RL, Raimer SS. Clinical and histologic features of striated muscle hamartoma: possible relationship to Delleman's Syndrome. *J Cutan Pathol* 1994; 21: 40–46.
4. Soria Arteaga L, Ruiz Fernández P, Sanchez Yus E. *Histología regional de la cara. Piel* 1995; 10: 378–382.
5. Fogt F, Tahan SR. Cutaneous hamartoma of adnexa and mesenchyme. A variant of folliculosebaceous cystic hamartoma with vascular-mesenchymal overgrowth. *Am J Dermatopathol* 1993; 15: 73–76.
6. Kimura T, Miyazawa H, Aoyagi T, Ackerman AB. Folliculosebaceous cystic hamartoma. A distinctive malformation of the skin. *Am J Dermatopathol* 1991; 13: 213–220.

Accepted March 23, 1998.

Renato Grilli MD¹, Pilar Escalonilla MD¹, M. Luisa Soriano MD¹, M. Carmen Fariña MD¹, Guadalupe Renedo MD², Lucía Martín MD¹ and Luis Requena MD¹

Departments of, ¹Dermatology and ²Pathology, Fundación Jiménez Díaz, Avda. Reyes Católicos N° 2, ES-28040, Madrid, Spain.