

Tenascin-C is not a Useful Marker for Disease Activity in Psoriasis

MIEKE A. H. E. LATIJNHOUWERS¹, MIEKE BERGERS¹, ASTRID L. A. KUIJPERS¹, CARINE J. M. VAN DER VLEUTEN¹, HENRI DIJKMAN², PETER C. M. VAN DE KERKHOF¹ and JOOST SCHALKWIJK¹

Departments of ¹Dermatology and ²Pathology, University Hospital Nijmegen, Nijmegen, The Netherlands

Tenascin-C is an extracellular matrix glycoprotein that is markedly upregulated in the dermis of psoriatic skin. In this study, we have addressed the question whether the presence of tenascin-C in the lesion or in serum is a marker for disease activity. Immunohistochemical staining of tenascin-C before and after treatment with different topical and systemic medication showed that tenascin-C remained abundant after clinical remission of lesions, indicating that downregulation of tenascin-C to normal values is a slow process. By using a sensitive enzyme-linked immunosorbent assay to measure levels of serum tenascin-C in psoriatic patients and unaffected individuals, we found that tenascin-C levels in most patients were within the normal range. Moreover, tenascin-C values did not correlate with disease activity. We conclude that tenascin-C is not useful as a marker for disease activity in psoriasis. Key words: corticosteroid; retinoic acid; acitretin; methotrexate; cyclosporin A.

(Accepted March 13, 1998.)

Acta Derm Venereol (Stockh) 1998; 78: 331–334.

Joost Schalkwijk, Department of Dermatology, University Hospital Nijmegen, P.O. Box 9101, NL-6500 HB Nijmegen, The Netherlands.

One of the earliest abnormalities seen in the onset of formation of psoriatic lesions is the upregulation of the extracellular matrix protein tenascin-C (TN-C) (1–3). TN-C is a large hexameric glycoprotein consisting of subunits of 220–320 kDa that are linked by disulphide bonds (see (4) for review). In normal adult skin, TN-C surrounds blood vessels and epidermal adnexa and is sparsely distributed at the dermal–epidermal junction (Fig. 1) (1, 5, 6). TN-C expression in the papillary dermis is markedly increased in psoriatic lesions (1), in epidermal tumours (6–8) and after injury ((9–11) and references therein). Recently we showed that TN-C is not exclusively produced by dermal cells: in healing skin wounds, TN-C mRNA is expressed by epidermal keratinocytes as well (10). *In vitro* studies suggested various functions for TN-C, including modulation of cell proliferation, differentiation, adhesion and migration, and suppression of the immune response (reviewed in (4, 12)). The role of TN-C *in vivo*, however, remains elusive, especially because knocking out the TN-C gene in mice did not cause marked phenotypical changes (13).

TN-C protein is deposited in the extracellular matrix of various tissues, but in addition, TN-C is present in the circulation ((14) and references therein). Various reports show that low levels of TN-C can be detected in serum of healthy individuals, while TN-C levels increase in pathologic conditions, suggesting that TN-C could be useful as a diagnostic marker for some diseases.

The aim of this study was to investigate the dynamics of TN-C expression in psoriasis. Our data indicate that TN-C cannot be used as a marker for disease activity in psoriasis.

MATERIAL AND METHODS

TN-C expression in psoriatic plaques

Patients and therapies. Thirty-four patients with chronic plaque psoriasis were included for immunohistochemical evaluation of TN-C. A summary describing the medication in each of the four different treatment groups is given in Table I. In one patient group, a left-right study was performed comparing 0.1% hydrocortisone-17-butyrate cream (Locoid Crelo, Yamanouchi, Leiderdorp, The Netherlands) with vehicle as a placebo control. Clobetasol-17-propionate (Dermovate, Glaxo, Zeist, The Netherlands) was applied as ointment and as lotion, the latter under occlusion of a hydrocolloid dressing (Duoderm EG, Convatec, Woerden, The Netherlands).

In addition to the effect of topical treatments with corticosteroids on TN-C expression in psoriatic plaques, we investigated the effect of systemic treatment with the synthetic retinoic acid agonist acitretin (Roche, Basel, Switzerland). Ten patients with severe psoriasis were treated with 25 mg acitretin once daily, and this dosage was increased to 50 mg in patients who showed no improvement of the clinical scores after 8 weeks of treatment. Clinical efficacy of the topical treatments was assessed using the sum score: erythema, induration and desquamation were scored on a 5-point scale (0=no cutaneous involvement, 1=slight, 2=moderate, 3=marked, 4=severe involvement) and the three scores were added to obtain the sum score. To evaluate the extent and severity of the psoriasis and to assess the clinical effectiveness of systemic treatment with acitretin, the psoriasis area and severity index (PASI) was scored. Permission for experiments on humans was obtained from the Medical Ethical Committee of the University Hospital in Nijmegen, and patients gave their written informed consent to participate in this study.

Biopsies. Punch biopsies with a diameter of 3 or 4 mm were taken under local anaesthesia from the psoriatic lesions before and at the end of treatment, as indicated in Table I. Biopsies from patients who were treated with clobetasol-17-propionate were embedded in Tissue Tek OCT compound and stored at –80°C until use, while biopsies of patients who received other medication were formalin-fixed and embedded in paraffin.

Immunohistochemistry. The mouse monoclonal antiserum T2H5, which was kindly provided by A. Verstraeten (Free University, Amsterdam, The Netherlands), was used for staining of TN-C in cryostat sections. TN-C was visualized according to an indirect immunoperoxidase staining protocol described previously (1). For formalin-fixed sections of patients treated with hydrocortisone-17-butyrate, TN-C was detected by indirect immunoperoxidase staining (11) with the rabbit polyclonal antiserum A107 (Telios, San Diego, CA). TN953 was applied for detecting TN-C in biopsies of the acitretin-treated group, in combination with the peroxidase Vectastain Elite ABC kit (Vector Laboratories, Burlingame, CA). TN953 we raised in New Zealand White rabbits by immunization with highly purified human TN-C as previously described (10). Note that staining of psoriatic skin with either T2H5, A107 or TN953 gives the same TN-C staining pattern. The staining pattern obtained in normal skin is comparable for the different antisera as well.

For evaluation, staining of TN-C in the dermis was assessed using an 8-point scale (15): 0=no staining, 1=sporadic staining in the upper dermis adjacent to the basement membrane of the dermo-epidermal junction, 2=a patchy distribution in the upper dermis adjacent to the basement membrane, but not present in all dermal papillae, 3=a pat-

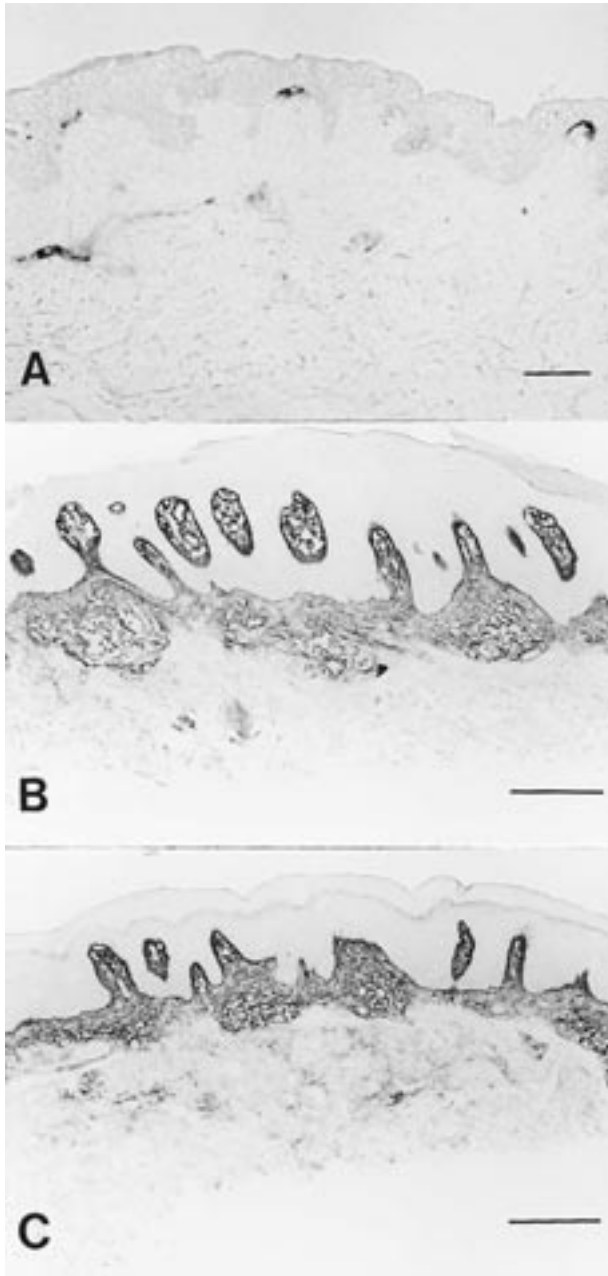


Fig. 1. Immunohistochemical staining of TN-C. (A) In normal human skin, TN-C is sparsely distributed in the papillary dermis and surrounds blood vessels. In psoriasis, TN-C is abundant before (B) and after (C) treatment with clobetasol-17-propionate lotion under occlusion. Scale bars: 100 μ m.

chy expression in the tips of all dermal papillae, but not continuous, 4 = a patchy expression in the tips of all dermal papillae that is not continuous but extends deeper into the dermis, 5 = a thin, but continuous layer adjacent to the basement membrane, 6 = a continuous layer, adjacent to the basement membrane and further in the papillary dermis, 7 = a continuous layer, adjacent to the basement membrane and extending into the reticular dermis.

TN-C in serum of psoriatic patients

Patients and therapies. Serum samples were collected from 7 healthy volunteers (3 males, 4 females) that participated in this study. For determination of circadian variation in TN-C values, blood was drawn

every 4 h during 24 h in a psoriatic patient and a healthy control. To study TN-C in psoriasis, 15 patients with severe chronic plaque psoriasis who were treated with cyclosporin A ($n=9$) or methotrexate ($n=6$) were included. Patients had not used systemic treatment for at least 4 weeks or local treatment for at least 1 week prior to the start of this study. Initial dosage of cyclosporin A was 3 mg/kg body weight; in 2 patients, this dosage was increased up to 4 mg/kg body weight after 8 weeks of treatment. At the start of the cyclosporin A therapy and after 2, 4, 8, 12 and 16 weeks, serum samples were collected, and the PASI score was determined as a measure of disease activity. Patients who received methotrexate initially started with 7.5 mg once weekly according to the Weinstein Schedule, and depending on their individual clinical response, this dosage was subsequently adjusted. Serum samples and PASI scores were obtained at various time points during treatment with methotrexate. Permission for experiments on humans was obtained from the Medical Ethical Committee of the University Hospital in Nijmegen, and patients gave their written informed consent to participate in this study.

Enzyme-linked immunosorbent assay. To quantify TN-C concentrations in sera, a modification of the sandwich-type enzyme-linked immunosorbent assay (ELISA) that we developed previously was applied (10). Normal goat serum (1% in PBS) was used instead of BSA to block free protein-binding sites. Binding of the secondary antiserum against TN-C was assessed with the peroxidase Vectastain Elite ABC kit (Vector Laboratories, Burlingame, USA) to make the assay more sensitive. The detection limit was approximately 5 ng TN-C per ml.

RESULTS

TN-C remains abundant after remission of psoriatic lesions

Biopsies were taken before and after treatment with topically applied corticosteroids (clobetasol-17-propionate or hydrocortisone-17-butyrate) or a systemically administered retinoic acid analogue (acitretin). TN-C was detected immunohistochemically and staining was assessed using an 8-point scale. Before treatment, TN-C was continuously distributed along the basement membrane at the dermal epidermal junction (scoring 5–7) in all biopsies. Although the medication used was clinically effective in most patients, as indicated by a decrease in their clinical score, TN-C staining patterns did not change significantly (see Table II and Fig. 1).

TN-C levels in the serum of psoriatic patients do not correlate with disease

We quantified TN-C in the serum of patients with severe psoriasis during treatment with cyclosporin A or methotrexate by ELISA. As a control, we measured TN-C levels in the serum of 7 healthy persons. TN-C concentrations in the control group ranged from 0.54–1.4 μ g/ml (mean 1.11 ± 0.39 μ g/ml); this correlates very well with the data published by other authors (14). In our study, we found no effect of age or sex on TN-C levels and observed no circadian rhythm (data not shown). TN-C levels in the serum of psoriatic patients showed considerable variation between individuals. Although many of the patients had serum levels in the normal range, in others, TN-C was increased compared to the levels in serum of unaffected subjects. In the whole set of patient sera tested, the TN-C concentrations measured ranged from 0.29–4.45 μ g/ml (mean 1.27 ± 0.79 μ g/ml). The difference in serum TN-C levels between patients and controls was not statistically significant.

Table I. Patients included in the immunohistochemical part of the study and their medication

Treatment	Patient number	Pharmacological type	Application	Application frequency	Duration of treatment
Hydrocortisone-17-butyrate ^a	6	Corticosteroid II	Topical	Twice daily	4 weeks
Placebo ^a	6	–	Topical	Twice daily	4 weeks
Clobetasol-17-propionate	9	Corticosteroid IV	Topical	Once weekly	6 weeks ^b
Clobetasol-17-propionate + occlusion	9	Corticosteroid IV	Topical	Twice daily	6 weeks ^b
Acitretin	10	Retinoic acid	Systemic	Once daily	12 weeks

^a Six patients participated in a left-right study in which treatment of a plaque on one side of the body with hydrocortisone-17-butyrate was compared with treatment of a plaque on the opposite side of the body with vehicle as a placebo control.

^b Patients were treated with clobetasol-17-propionate for a maximum of 6 weeks or less in cases of clearance of the lesion.

Table II. Tenascin-C in psoriatic plaques before and after treatment with different local or systemic medication

Therapy	Tenascin-C		Clinical score	
	Before	After	Before	After
Hydrocortisone-17-butyrate	5.8 (0.4)	5.8 (0.4)	6.8 (1.7)	2.3 (1.8)
Placebo	5.8 (0.4)	6.2 (0.4)	6.3 (1.4)	5.5 (1.2)
Clobetasol-17-propionate	6.0 (0.0)	6.0 (0.0)	5.7 (1.3)	1.6 (1.2)
Clobetasol-17-propionate + occlusion	6.0 (0.0)	6.1 (0.3)	6.6 (0.9)	0.8 (0.4)
Acitretin	5.9 (0.6)	5.5 (1.1)	20 (2.3)	13 (1.9)

TN-C was detected immunohistochemically, and staining was assessed using an 8-point scale. The clinical severity of the psoriasis was assessed using the sum score for topical treatments, and the PASI score for systemic treatment with acitretin. Data shown are mean values of Tenascin-C scoring and clinical scores plus SD.

No significant correlation was found between PASI scores and TN-C serum levels.

DISCUSSION

To gain further insight into the kinetics and patterns of TN-C at the protein level during different stages of the disease, we studied TN-C immunohistochemically in psoriatic lesions. As reported previously, TN-C was markedly upregulated at the dermal – epidermal junction in untreated lesions. Furthermore, we found that TN-C continued to be present at elevated levels after clinical remission of lesions. This was seen after topical treatment with corticosteroids of different classes as well as after systemic treatment with the retinoic acid derivative acitretin. Clinical efficacy of these therapies is accompanied by normalization of the expression pattern of other histological markers of psoriasis, including the proliferation marker Ki-67, and differentiation markers such as transglutaminase, cytokeratin 16, and SKALP/elafin ((16) and unpublished results). This clearly contrasts with the regulation of TN-C during clearance: the normal distribution of TN-C seems to be restored much more slowly. It is likely that prolonged treatment will ultimately result in a reduction of TN-C in the psoriatic lesion. We hypothesize that TN-C might be a marker for complete resolution of a lesion. Further studies are needed to test whether evaluating TN-C immunoreactivity might provide an approach to ascertain complete resolution of psoriatic lesions, and to see whether downregulation of TN-C to normal levels could be associated with prolonged remission of lesions.

The effect of corticosteroids on TN-C production was previously investigated in experiments with cultured cells and in animal models. Addition of dexamethasone to the culture med-

ium of fibroblasts and other cells was shown to inhibit the synthesis of TN-C (17). In mice, oral administration of dexamethasone decreased the expression of TN-C mRNA in wounds and experimental tumours (18, 19). These findings differ from the results presented here, where we did not observe an effect of corticosteroids on TN-C in psoriatic lesions. However, we examined the effect of corticosteroids on the presence of TN-C protein in the extracellular matrix, while in the other studies, synthesis of new TN-C was examined by quantifying TN-C mRNA or metabolically labelled protein. If turnover of TN-C protein is slow in psoriatic lesions, the protein will still be abundant even if TN-C synthesis was blocked by the corticosteroids that we applied. Another explanation for the difference in observations might be that TN-C is not affected in this study because the effective corticosteroid concentration obtained through local administration might be too low to reduce TN-C expression.

In addition to examining TN-C in sections of psoriatic lesions, we also studied the kinetics of TN-C during psoriasis at a more systemic level by quantifying TN-C in the serum of psoriatic patients. Although some patients had TN-C levels up to 4 times the mean value obtained for unaffected individuals, many patients had values in the normal range. Moreover, serum TN-C levels did not significantly correlate with the clinical course of disease. Others have reported that an increase in TN-C levels in the serum correlates with inflammation (14, 20). Such a correlation with inflammation was not observed in the psoriatic patients that participated in this study, as neither induration nor erythema scores were indicative for the amount of TN-C detected in the serum.

We conclude from our data that neither the presence of TN-C in the dermis, nor its presence in serum, can be used as a marker for disease activity in psoriasis.

ACKNOWLEDGEMENTS

The authors thank Gijs de Jongh for his skilful statistical evaluation of results. This work was financially supported by a grant from The Netherlands Organization for Scientific Research.

REFERENCES

- Schalkwijk J, van Vlijmen I, Oosterling B, Perret C, Koopman R, van den Born J, et al. Tenascin expression in hyperproliferative skin diseases. *Br J Dermatol* 1991; 124: 13–20.
- de Jong EMGJ, Schalkwijk J, van de Kerkhof PCM. Epidermal proliferation and differentiation, composition of the inflammatory infiltrate and the extracellular matrix in the margin of the spreading psoriatic lesion. *Eur J Dermatol* 1991; 1: 221–227.
- Gerritsen MJP, Elbers ME, de Jong EMGJ, van de Kerkhof PCM. Recruitment of cycling epidermal cells and expression of fillagrin, involucrin and tenascin in the margin of the active psoriatic plaque, in the uninvolved skin of psoriatic patients and in the normal healthy skin. *J Dermatol Sci* 1997; 14: 179–188.
- Lightner VA. Tenascin: does it play a role in epidermal morphogenesis and homeostasis? *J Invest Dermatol* 1994; 102: 273–277.
- Lightner VA, Gumkowski F, Bigner DD, Erickson HP. Tenascin/hexabrachion in human skin: biochemical identification and localization by light and electron microscopy. *J Cell Biol* 1989; 108: 2483–2493.
- Shikata N, Oyaizu T, Andachi H, Tsubura A. Tenascin expression in normal human adult skin and skin appendage tumours. *Virchows Arch* 1994; 424: 511–516.
- Sakakura T, Kusakabe M. Can tenascin be redundant in cancer development? *Perspect Dev Neurobiol* 1994; 2: 111–116.
- Verstraeten AA, Mackie EJ, Hageman PC, Hilgers J, Schol DJ, de Jongh GJ, et al. Tenascin expression in basal cell carcinoma. *Br J Dermatol* 1992; 127: 571–574.
- Schalkwijk J, Steijlen PM, van Vlijmen Willems IM, Oosterling B, Mackie EJ, Verstraeten AA. Tenascin expression in human dermis is related to epidermal proliferation. *Am J Pathol* 1991; 139: 1143–1150.
- Latijnhouwers MAHE, Bergers M, Ponc M, Dijkman H, Andriessen MPN, Schalkwijk J. Human epidermal keratinocytes are a source of tenascin-C during wound healing. *J Invest Dermatol* 1997; 108: 776–783.
- Latijnhouwers MA, Bergers M, Vanbergen BH, Spruijt KI, Andriessen MP, Schalkwijk J. Tenascin expression during wound healing in human skin. *J Pathol* 1996; 178: 30–35.
- Chiquet Ehrismann R, Hagios C, Schenk S. The complexity in regulating the expression of tenascins. *Bioassays* 1995; 17: 873–878.
- Saga Y, Yagi T, Ikawa Y, Sakakura T, Aizawa S. Mice develop normally without tenascin. *Genes Dev* 1992; 6: 1821–1831.
- Schenk S, Muser J, Vollmer G, Chiquet Ehrismann R. Tenascin-C in serum: a questionable tumor marker. *Int J Cancer* 1995; 61: 443–449.
- Seyger MMB, van Pelt JPA, van den Born J, Latijnhouwers MA, de Jong EMGJ. Epicutaneous application of leukotriene B4 induces patterns of tenascin and a heparan sulfate proteoglycan epitope that are typical for psoriatic lesions. *Arch Dermatol Res* 1997; 289: 331–336.
- Kuijpers ALA, Bergers M, Siegenthaler G, Zeeuwen PLJM, van de Kerkhof PCM, Schalkwijk J. Skin-derived antileukoproteinase (SKALP) and epidermal fatty acid-binding protein (E-FABP): two novel markers of the psoriatic phenotype that respond differentially to topical steroid. *Acta Derm Venereol (Stockh)* 1997; 77: 14–19.
- Eklom M, Fassler R, Tomasini Johansson B, Nilsson K, Eklom P. Downregulation of tenascin expression by glucocorticoids in bone marrow stromal cells and in fibroblasts. *J Cell Biol* 1993; 123: 1037–1045.
- Fässler R, Sasaki T, Timpl R, Chu ML, Werner S. Differential regulation of fibulin, tenascin-C, and nidogen expression during wound healing of normal and glucocorticoid-treated mice. *Exp Cell Res* 1996; 222: 111–116.
- Talts JF, Weller A, Timpl R, Eklom M, Eklom P. Regulation of mesenchymal extracellular matrix protein synthesis by transforming growth factor-beta and glucocorticoids in tumor stroma. *J Cell Sci* 1995; 108: 2153–2162.
- Schenk S, Muser J, Vollmer G, Chiquet Ehrismann R. Tenascin-C in serum: an acute-phase protein or a carcinoma marker? [letter]. *Int J Cancer* 1995; 60: 145.