

INVESTIGATIVE REPORTS

Morphological Assessment of the Effects of Cyclosporin A on Mast Cell - Nerve Relationship in Atopic Dermatitis

MASAHIKO TOYODA and MASA AKI MOROHASHI

Department of Dermatology, Faculty of Medicine, Toyama Medical and Pharmaceutical University, Toyama, Japan

There is considerable clinical and experimental evidence that cyclosporin A has powerful therapeutic effects on severe, therapy-resistant atopic dermatitis. To further clarify the mechanism of beneficial action of cyclosporin A for atopic dermatitis, we assessed its effects on mast cell morphology and on the topographical relationship between mast cells and cutaneous nerves in lesional skin of atopic dermatitis. The ultrastructural features of mast cell - specific granules in cyclosporin A-treated skin compared with those in the pretreated skin included an increase in the stable granule population and the disappearance of signs of granule exocytosis. The close apposition of mast cells to peripheral nerve fibres in the upper dermis and an invasion of mast cells into nerve bundles in the lower dermis were immunohistochemically noted, and an intimate association between mast cells and unmyelinated dermal nerves or Schwann cells was observed ultrastructurally in the pretreated lesional skin. After cyclosporin A therapy, the close interrelation of mast cells and cutaneous nerves was not seen. These findings suggest that cyclosporin A may exert its therapeutic efficacy by inhibiting mast cell activation, and by affecting the interaction between mast cells and nerves, which may explain the beneficial therapeutic action of cyclosporin A in the management of the disease. *Key words: electron microscopy; immunohistochemistry; skin; therapy.*

(Accepted February 27, 1998.)

Acta Derm Venereol (Stockh) 1998; 78: 321–325.

M. Toyoda, Department of Dermatology, Toyama Medical and Pharmaceutical University, 2630 Sugitani, Toyama 930-0194, Japan.

The pathogenesis of atopic dermatitis (AD) is multifactorial and involves genetic, physiological, pharmacological, psychological, and immunologic factors. Mast cells (MCs) are known to participate not only in immediate-type hypersensitivity but also in chronic inflammation and delayed immune response, and to contribute to the pathomechanism of various allergic skin disorders, such as AD (1, 2). The nervous system is also closely associated with exacerbation as well as onset of AD through emotional stress (3), altered patterns of cutaneous innervation, and abnormal expression of neuropeptides in lesional skin (4–7). All of these factors could contribute to interaction between the nervous system and the immune system, referred to as neurogenic inflammation in AD. Histamine released from MCs is thought to amplify neurogenic inflammation in the skin, and, in turn, some types of neuropeptides released from sensory nerve endings upon stimulation are capable of inducing the release of chemical mediators from skin MCs, which leads to a cell-mediated inflammatory skin condition (1, 8). In addition, an intimate spatial relationship of MCs to peripheral nerve fibres has been reported in lesional skin of

AD patients (9), and therefore close interaction between MCs and the cutaneous nervous system may play a significant role in the pathophysiology of AD.

Cyclosporin A (CsA) has been shown to be a potent and effective therapeutic agent in many inflammatory and immunologically mediated dermatologic disorders, including AD. Many clinical trials have confirmed the remarkable efficacy of oral CsA therapy in patients with severe, drug-resistant AD, which results in a marked reduction in disease severity as well as in itch intensity (10–12). Although the exact mechanism of the beneficial effects of CsA therapy in AD has not been sufficiently elucidated because of its manifold modes of action, most of the evidence suggests that CsA suppresses T-lymphocyte function and the production of cytokines involved in the immunopathogenesis of AD (13, 14). Although there have been several studies about the effects of CsA on MCs (1, 15–18), a morphological assessment of human skin MCs and the MC - nerve relationship in lesional skin of AD patients treated with CsA has never been reported in the literature.

The aim of this study was to ascertain whether CsA therapy elicits alterations in the morphology of MCs and/or in the topographical relationship between MCs and cutaneous nerves in patients with severe, chronic AD.

MATERIALS AND METHODS

Patients

Informed consent was obtained from two male patients, aged 25 and 28, with severe, constitutional eczematous lesions and with a chronic course of more than 10 years who fulfilled the diagnostic clinical criteria for AD (19, 20). They were treated with CsA (Sandimmune, Novartis Pharma K.K.), at a dose of 5 mg/kg/day, given orally for 1 month as a single evening dose (21). Both patients had been resistant to various other systemic and topical treatments in the past. Systemic treatments for AD, such as PUVA therapy and oral administration of antihistamines, had been discontinued 4 weeks before the start of treatment with CsA, and neither patients had received any topical therapy for 2 weeks before treatment. No other concurrent therapy was given during the course of CsA therapy in either patient.

Biopsies and tissue processing

Four-millimeter punch biopsy specimens were obtained from lichenified lesions on the back of each patient before treatment with CsA. Subsequently, biopsy specimens were taken 1 month after the start of CsA therapy from lesional skin near sites from which the pretreatment specimens had been obtained.

Half of each biopsy specimen was fixed in 10% buffered neutral formalin and embedded in paraffin. For histological examination, 4 µm tissue sections were stained with hematoxylin and eosin and with 1% toluidine blue, pH 7.0, to identify MCs. For immunohistochemical studies, the formalin-fixed and paraffin-embedded tissue sections were deparaffinized, rehydrated, rinsed in phosphate-buffered saline, and

then stained using the avidin-biotin-peroxidase complex method (22) with an antibody recognizing the general neuronal marker, protein gene product 9.5 (Ultraclone Ltd., Isle of Wight, UK), which stains various populations of cutaneous nerves (23). Controls examined consisted of sections in which the primary antibody was omitted and/or was substituted by an irrelevant monoclonal antibody of a similar isotype. After the immunohistochemical procedures, the sections were counterstained with toluidine blue, which made it possible to recognize the topographical relationship between MCs and nerves using conventional microscopy.

The remaining halves of the biopsy specimens for electron microscopy were fixed in 2.5% glutaraldehyde and postfixed in 2% osmium tetroxide, and then stained *en bloc* in 3% aqueous uranyl acetate. They were dehydrated in graded steps of ethanol and embedded in Epon 812. Ultrathin sections (70 nm) were doubly stained in uranyl acetate and lead citrate prior to examination in an H-300 transmission electron microscope (Hitachi, Tokyo) at an acceleration voltage of 100 kv.

Quantification of MCs

The number of MCs in the papillary dermis and the subpapillary region was counted in 10 non-serial sections for each skin sample in 10 different visual fields at a magnification of $\times 400$ with a light microscope, and mean number of MCs was recorded for each skin sample. The results of MC number before and after treatment with CsA were analysed statistically using a paired *t*-test.

RESULTS

A substantial clinical improvement, characterized by a rapid relief of itch intensity and a remarkable reduction in disease severity, was achieved after oral administration of CsA in both patients. The histological changes observed in skin sections before and after CsA treatment paralleled the clinical improvement. After the CsA therapy, a clear reduction in the dermal mononuclear cell infiltrate was observed, as was a remarkable decrease in epidermal thickness and in the number of intraepidermal microvesicles.

The number of MCs

In lesional skin before treatment, the number of MCs was 73.4 ± 6.2 (mean \pm SD) and 80.5 ± 8.1 in the 2 patients in 10 visual fields at a magnification of $\times 400$. After 1 month of CsA treatment, a slight but statistically insignificant reduction was observed in MC number of the 2 patients (68.5 ± 5.5 and 75.0 ± 4.9 , respectively). Morphological changes of MCs, such as in their cell size or in their distribution, were not observed at the light microscopic level before or after CsA therapy.

Ultrastructure of MCs

A comparison of specimens taken before and after treatment with CsA showed some interesting ultrastructural alterations in MCs, especially in their specific granules. In lesional skin prior to treatment, MCs possessed specific granules which exhibited various degrees of degranulation. Most of the specific granules were homogeneous, showing decreased electron density of the granule matrix, whereas adjacent homogeneous granules were often fused with each other, forming masses of flocculent material. MC granules were frequently in contact with extracellular spaces, a sign of granule exocytosis (Fig. 1a). MC granules were also observed in extracellular spaces near MCs in some sections. By comparison, MCs in the skin of AD patients after 1 month of CsA therapy possessed not only homogeneous granules but also a population

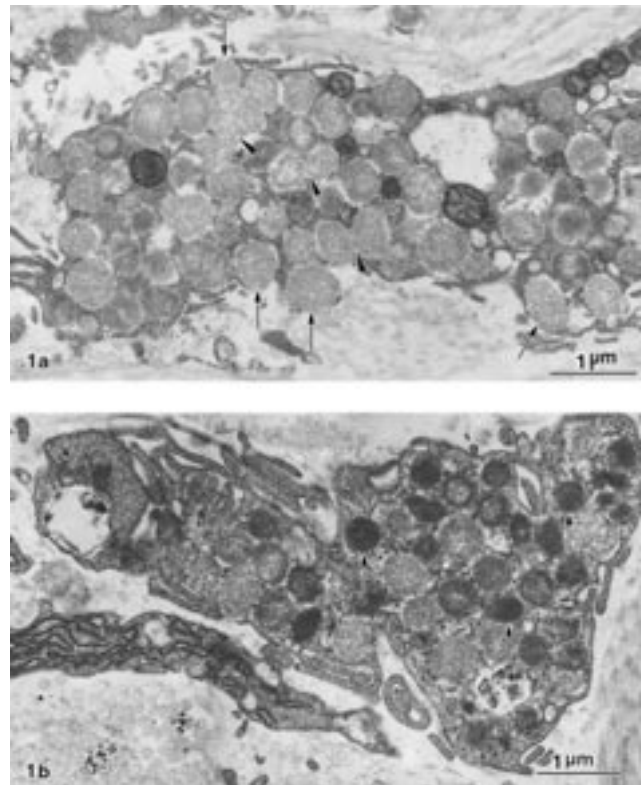


Fig. 1. Transmission electron micrographs of MCs in lesional back skin of AD patients before (a) and after (b) treatment with CsA. (a) Granules of MCs show fusion of adjacent granules (arrow-heads), and contact with the extracellular space (arrows). (b) The MC possesses homogeneous granules and stable granules (arrows).

of stable granules which were uniformly electron-dense and surrounded by the distinct outline of a perigranular membrane. Exocytosis of MC granules, as was seen in MCs in skin before treatment with CsA, were rarely observed (Fig. 1b).

The relationship between MCs and nerve fibres

Immunoreactivity for protein gene product 9.5 in lesional skin of AD patients was seen in the epidermis, dermis and around vessels and cutaneous adnexa. In sections of skin taken prior to CsA therapy, counterstaining with toluidine-blue following immunostaining with protein gene product 9.5 showed the close apposition of MCs to peripheral nerve fibres mainly in the perivascular area of the upper dermis (Fig. 2a). Nerve fibres were often surrounded by several MCs (Fig. 2b). In the lower dermis, many trespassing nerve bundles were also immunoreactive for protein gene product 9.5. Lesional skin taken before CsA treatment showed invasion or attachment of MCs to those nerve bundles (Fig. 2c, d). In contrast, such close association between MCs and cutaneous dermal nerve fibres seen in untreated lesional skin was not observed in the skin of AD patients after CsA treatment.

The intimate topographical relation between MCs and nerve fibres in untreated lesional skin was amply confirmed by ultrastructural studies. MCs showing degranulation processes were in close or direct proximity to nerve bundles (Fig. 3a, b), and some MCs showed close apposition to Schwann cells (Fig. 3c). These findings were never observed in any sections of lesional skin from CsA-treated AD patients.

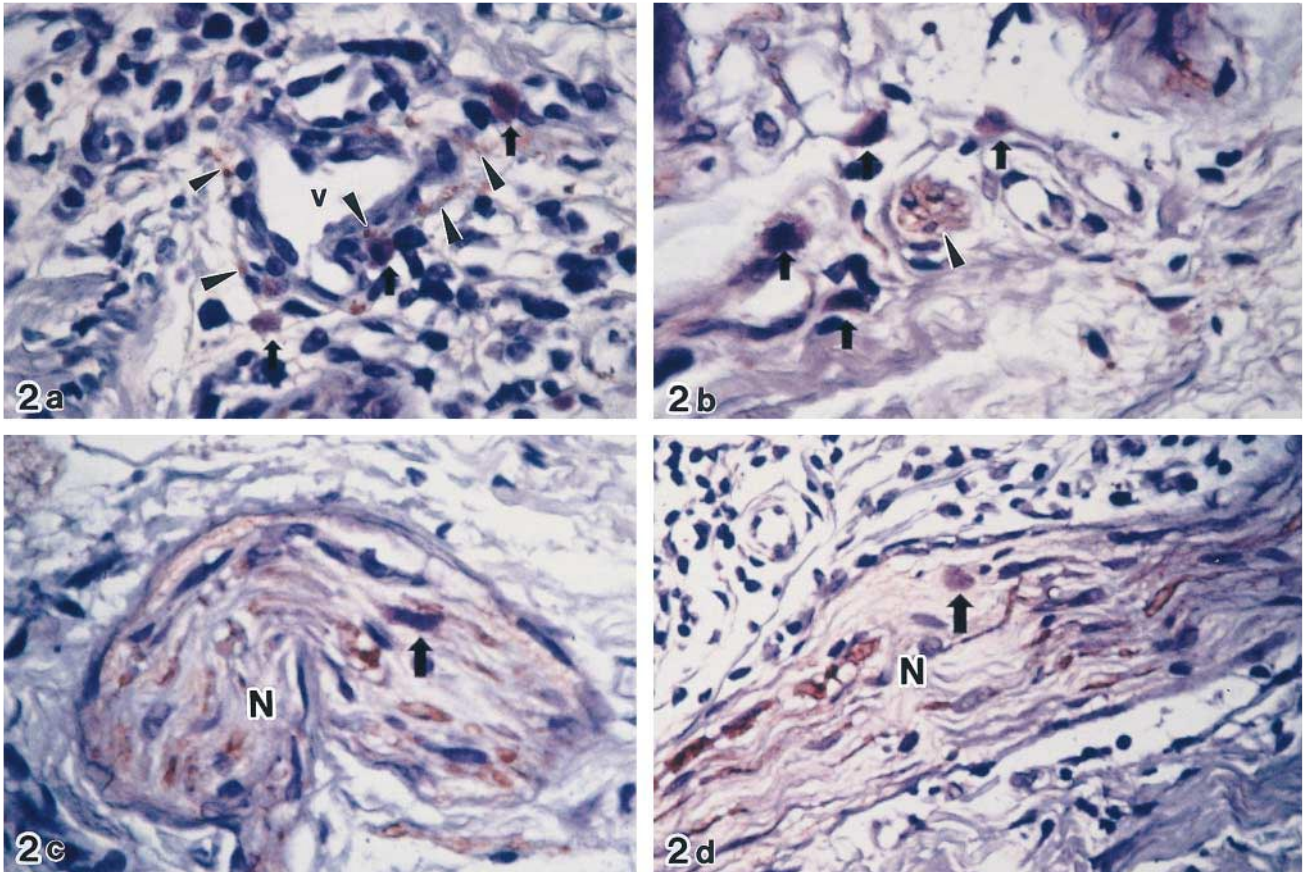


Fig. 2. Close association of MC with cutaneous nerves in AD lesional skin before CsA therapy in the upper dermis (a, b) and in the lower dermis (c, d). Immunohistochemical staining with monoclonal PGP 9.5 antibody was followed by counterstain with toluidine blue, pH 7.0. (a) PGP 9.5 immunoreactive nerve profiles (arrow-heads) in close apposition to MC (arrows) around a superficial vessel (V) (patient 1, $\times 400$). (b) A PGP 9.5 immunoreactive nerve (arrow-head) surrounded by several mast cells (arrows) (patient 2, $\times 400$). (c), (d) MCs (arrows) invading thick trespassing nerve bundles (N) visualized by strong immunoreactivity for PGP 9.5. (c: patient 1, d: patient 2, $\times 400$).

DISCUSSION

It has been recognized for some time that the beneficial effects of CsA in the treatment of patients with AD can be attributed primarily to inhibition of T-helper cell activation, which results in the suppression of cytokine production, such as IL-2, IL-4 and IL-5 (14). CsA also indirectly inhibits the growth and differentiation of B lymphocytes and the functional activities of mononuclear phagocytes, Langerhans' cells and eosinophils (1). Furthermore, our recent immunohistochemical study revealed that CsA may play a therapeutic role via effects on the cutaneous nervous system through altered innervation and neuropeptide expression in lesional skin of AD (24). In addition to these previously reported modes of CsA action, the present morphological study offers a strong indication that CsA may exert its clinical efficacy for AD by inhibiting MC activation and by alterations of a topographical relationship between MCs and cutaneous nerves in lesional skin, suggesting a new aspect of the effects of CsA in the management of the disease.

In allergic diseases, exposure of sensitized subjects to specific allergens causes the activation of tissue MCs, and a subsequent immediate-type hypersensitivity response and, in some individuals, a late phase response, which may also be involved in the pathogenesis of AD (25). It is known that there is enhanced histamine release by cutaneous MCs specifically upon immu-

nologic challenge of AD patients compared with healthy controls (26). MCs containing the proteinases tryptase and chymase in their secretory granules are the predominant MC type in normal human skin, but MCs containing only tryptase have been reported to be significantly increased in lesional AD skin (27). Morphologically, human cutaneous MCs in lichenified lesions of AD patients show a significant increase in number accompanied by accelerated degranulation (28, 29), and a unique cluster formation by activated MCs, a feature characteristic of obstinate cases of AD (30). MCs are thus undoubtedly involved in the pathophysiology of AD.

We have demonstrated in this study that the number of MCs in lesional AD skin remained unchanged before and after 1 month of oral CsA administration, in spite of apparent clinical and histological improvement. This result seems to disagree with a previous report that numbers of mucosal MC were diminished in CsA-treated animals exhibiting graft-vs-host disease or helminth infections (31). This apparent discrepancy may result from several different factors in these studies, including types of diseases, the species and organs examined, the total dose of CsA administered and the duration of therapy. However, it is difficult to draw a conclusion at this time regarding the effect of CsA on the MC population in AD because of the low number of biopsies studied. The presence of MCs in lesional AD skin after CsA treatment may partially

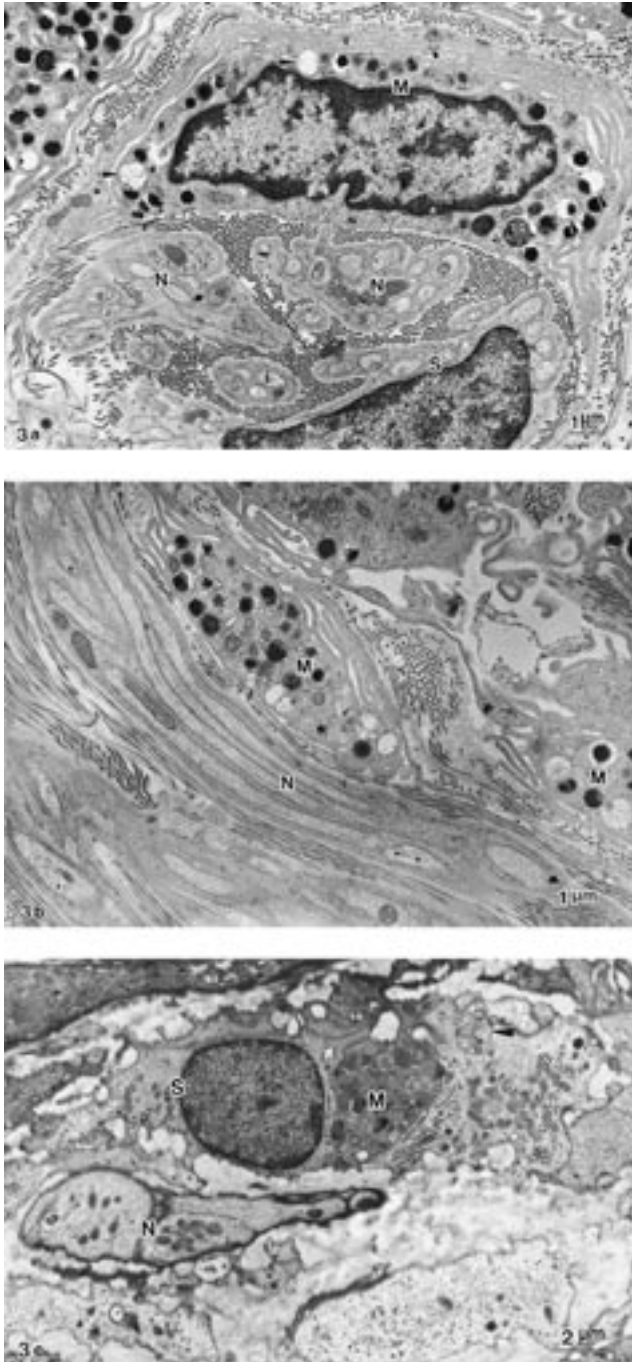


Fig. 3. Transmission electron micrographs of the intimate relationship between MC and nerves in AD lesional skin before CsA therapy. (a) Transversely cut nerve fibres (N) in close apposition to a mast cell (M) containing degranulated specific granules (arrow-heads). Note that villous projections (v) of the MC are remarkably extended. S: Schwann cell (b) Mast cells (M) adjacent to a longitudinally cut nerve fibre (N). (c) A mast cell (M) in direct contact with a Schwann cell (S). Note a nerve fibre (N) situated near the Schwann cell and an axon (arrow-head) enveloped by the cytoplasm of the Schwann cell.

explain the relapses noted in several clinical trials (12, 19, 32, 33) following cessation of CsA administration.

We observed visible ultrastructural alterations of MC-specific granules in CsA-treated AD skin compared with AD skin prior to treatment. Our observations of an increase in

the stable granule population, a decrease in homogeneous granules indicating an initial stage of degranulation, and the disappearance of adjacent granule fusion and subsequent exocytosis of granules after CsA treatment provide the first ultrastructural evidence of the effects of CsA on the inhibition of MC activation processes in AD skin. These findings support previous *in vitro* studies on the inhibitory effect of CsA on the immunologic activation of MCs (1, 15). Stellato et al. (15) reported that CsA rapidly and irreversibly inhibits the release of preformed (histamine) and of de novo synthesized (prostaglandin D₂) mediators from purified human skin MCs challenged with anti-IgE. It is interesting to note that, in that study, CsA exerted no inhibitory effect on substance P-induced histamine release from MCs, suggesting that the inhibitory effect of CsA has a high degree of selectivity depending on the nature of the stimulus. In addition, MCs are able to produce a variety of cytokines, such as IL-4, IL-5, IL-6, tumour necrosis factor- α and interferon- γ , which are extensively involved in modulating inflammatory responses in the skin (1). TNF- α is an especially important determinant of inflammatory cell-endothelial cell adhesive interactions during the genesis of cellular inflammation in the skin (34), and within MC granules TNF- α is rapidly released into the extracellular space upon degranulation. Wershil et al. (16) reported that CsA interferes with the pathogenesis of IgE-, MC- and cytokine-dependent inflammatory reactions by inhibiting IgE-dependent TNF- α mRNA production and thus the synthesis of TNF- α protein. Taken together, the possibility that CsA may ameliorate disturbances of cell-mediated immunity in AD by suppressing the release of histamine, lipid mediators, active proteinases and cytokines from MCs should be considered. Our ultrastructural findings in this study support the inhibitory effects of MC activation by CsA.

To our knowledge, this is the first study in which alterations of MC-nerve relationships following CsA therapy of AD lesional skin have been observed using immunohistochemical and ultrastructural methods. The close interaction between MCs and cutaneous nerves has long been recognized. Electrical stimulation of nerve fibres or various neuropeptides antidromically released from peripheral nerve fibres induces MC degranulation (8, 35). Although the close topographical relationship of cutaneous nerve fibres or the anatomical direct contact of neuropeptide-containing sensory nerves with MCs has already been described (36, 37), the exact role of this interaction remains to be elucidated. Sugiura et al. (9) observed MC invasion into peripheral nerves in 9 of 10 AD lesional skin specimens at the ultrastructural level. They proposed that the invasion of MCs showing degranulation into dermal nerves may be related to provoking or aggravating the itch in AD. Our immunohistochemical observation revealed the close apposition of MCs to peripheral nerve fibres mainly in the perivascular area of the upper dermis. Taking into account the decrease in density of perivascular nerve fibres in CsA-treated AD skin compared with AD skin prior to treatment (24), lack of this apposition between MCs and perivascular nerves after CsA therapy may be due to the effect of CsA on the innervation in lesional AD skin. In addition, the invasion of MCs into trespassing nerve bundles was observed in the lower dermis of AD lesional skin. The close association between MCs and unmyelinated dermal nerves or Schwann cells was further confirmed by electron microscopy. These findings support the concept that interactions between MCs and the cutaneous nervous system may play an important role in the pathogenesis of AD.

However, this intimate interrelation of MCs to nerves was not recognized at all in either AD case examined after 1 month of CsA therapy.

The possibility that the changes seen in this study are not directly due to CsA but simply a non-specific effect of resolution of AD cannot be excluded at present. Effects which are specific to CsA and not a non-specific effect of lesional clearance could be demonstrated by studying biopsies taken a short time after starting CsA, although biopsies were taken after a month of CsA treatment in our study. A comparison with the findings in the patients treated with other methods, such as topical steroids, has also to be performed. Nevertheless, our results suggest that CsA may have more potential modes of action for the management of AD than hitherto suspected, and we believe that this study should be one step in clarifying the significance of the MC - nerve relationship in AD and the mechanism of possible effects on these interactions by CsA.

REFERENCES

- Harvima I, Horsmanheimo L, Naukkarinen A, Horsmanheimo M. Mast cell proteinases and cytokines in skin inflammation. *Arch Dermatol Res* 1994; 287: 61–67.
- Van Bever HP. Recent advances in the pathogenesis of atopic dermatitis. *Eur J Pediatr* 1992; 151: 870–873.
- Hanifin JM. Atopic dermatitis. *J Allergy Clin Immunol* 1984; 73: 211–222.
- Giannetti A, Girolomoni G. Skin reactivity to neuropeptides in atopic dermatitis. *Br J Dermatol* 1989; 121: 618–688.
- Pincelli C, Fantini F, Massimi P, Girolomoni G, Seidenari S, Giannetti A. Neuropeptides in skin from patients with atopic dermatitis: an immunohistochemical study. *Br J Dermatol* 1990; 122: 745–750.
- Tobin D, Nabarro G, Baart de la Faille H, Van Vloten WA, van der Putte SCJ, Schuurman HJ. Increased number of immunoreactive nerve fibers in atopic dermatitis. *J Allergy Clin Immunol* 1992; 90: 613–622.
- Ostlere LS, Cowen T, Rustin MHA. Neuropeptides in the skin of patients with atopic dermatitis. *Clin Exp Derm* 1995; 20: 462–467.
- Pincelli C, Fantini F, Giannetti A. Neuropeptides and skin inflammation. *Dermatology* 1993; 187: 153–158.
- Sugiura H, Maeda T, Uehara M. Mast cell invasion of peripheral nerve in skin lesions of atopic dermatitis. *Acta Derm Venereol (Stockh)* 1992; Suppl 176: 74–76.
- Van Joost T, Stolz E, Heule F. Efficacy of low dose cyclosporin in severe atopic skin disease. *Arch Dermatol* 1987; 123: 166–167.
- Sowden JM, Berth-Jones J, Ross JS, Motley RJ, Marks R, et al. Double-blind controlled cross-over study of cyclosporine in adults with severe refractory atopic dermatitis. *Lancet* 1991; 338: 137–140.
- Garnier-Lyonnet S, Thivolet J, van Dongen M, Viac J, Frappaz A. Cyclosporin A improves severe atopic dermatitis in adults and reduces activated CD4⁺ T lymphocytes. *Eur J Dermatol* 1995; 5: 481–485.
- Van Joost T, Kozel MMA, Tank B, Troost R, Prens EP. Cyclosporine in atopic dermatitis. Modulation in the expression of immunologic markers in lesional skin. *J Am Acad Dermatol* 1992; 27: 922–928.
- Faulds D, Goa KL, Benfield P. Cyclosporin-A review of its pharmacodynamic and pharmacokinetic properties, and therapeutic use in immunoregulatory disorders. *Drugs* 1993; 45: 953–1040.
- Stellato C, de Paulis A, Ciccarelli A, Cirillo R, Patella V, Casolaro V, Marone G. Anti-inflammatory effect of cyclosporin A on human skin mast cells. *J Invest Dermatol* 1992; 98: 800–804.
- Wershil BK, Furuta GT, Lavigne JA, Choudhury AR, Wang ZS, Galli SJ. Dexamethasone and cyclosporin A suppress mast cell-leukocyte cytokine cascades by multiple mechanisms. *Int Arch Allergy Immunol* 1995; 107: 323–324.
- Dráberová L. Cyclosporin A inhibits rat mast cell activation. *Eur J Immunol* 1990; 20: 1469–1473.
- Columbo M, Bochner BS, Marone G. Human skin mast cells express functional beta 1 integrins that mediate adhesion to extracellular matrix proteins. *J Immunol* 1995; 154: 6058–6064.
- Svensson A, Edman B, Möller H. A diagnostic tool for atopic dermatitis based on clinical criteria. *Acta Derm Venereol (Stockh)* 1985; Suppl 114: 33–40.
- Hanifin JM, Cooper KD, Royh HL. Atopy and atopic dermatitis. *J Am Acad Dermatol* 1986; 15: 703–706.
- Munro CS, Higgins EM, Marks JM, Daly BM, Friedmann PS, Shuster S. Cyclosporin A in atopic dermatitis: therapeutic response is dissociated from effects on allergic reactions. *Br J Dermatol* 1991; 124: 43–48.
- Hsu SM, Raine L, Fanger H. Use of avidin-biotin-peroxidase complex (ABC) in immunoperoxidase techniques: a comparison between ABC and unlabelled antibody (PAP) procedures. *J Histochem Cytochem* 1981; 29: 577–580.
- Dalsgaard CJ, Rydh M, Haegerstrand A. Cutaneous innervation in man visualized with protein gene-product (PGP 9.5) antibodies. *Histochemistry* 1989; 92: 385–389.
- Toyoda M, Morimatsu S, Morohashi M. The alterations of cutaneous innervation and neuropeptides expression by cyclosporin A treatment in atopic dermatitis: an immunohistochemical study. *Jpn J Dermatol* 1997; 107: 1275–1279.
- Katayama I, Tanei R, Yokozeki H, Nishioka K, Doi Y. Induction of eczematous skin reaction in experimentally induced hyperplastic skin of Balb/c mouse by monoclonal anti-DNP IgE antibody: possible implication for skin lesion formation in atopic dermatitis. *Int Arch Allergy Appl. Immunol* 1990; 93: 148–154.
- Ruzicka T, Glück S. Cutaneous histamine levels and histamine releasability from the skin in atopic dermatitis and hyper-IgE-syndrome. *Arch Dermatol Res* 1983; 275: 41–44.
- Irani AM, Sampson HG, Schwartz LB. Mast cells in atopic dermatitis. *Allergy* 1989; 44 (Suppl 9): 31–34.
- Mihm M Jr, Soter NA, Dvorak H, Austen KF. The structure of normal skin and the morphology of atopic eczema. *J Invest Dermatol* 1976; 67: 305–312.
- Soter NA. Morphology of atopic eczema. *Allergy* 1989; 14 (Suppl): 16–19.
- Toyoda M, Maruyama T, Morohashi M, Takaya K. An electron microscopic study of the mast cell in obstinate cases of atopic dermatitis: morphology of specific granules and cluster formation. *Jpn J Dermatol* 1993; 103: 1445–1449.
- Cummins AG, Munro GH, Ferguson A. Effect of cyclosporin A on rat mucosal mast cells and the associated protease RMCP II. *Clin Exp Immunol* 1988; 72: 136–140.
- Wahlgren CF, Scheynius A, Hägermark Ö. Antipruritic effect of oral cyclosporin A in atopic dermatitis. *Acta Derm Venereol (Stockh)* 1990; 70: 323–329.
- Motley RJ, Whittaker JA, Holt PJA. Resolution of atopic dermatitis in a patient treated with cyclosporin. *Clin Exp Dermatol* 1989; 14: 243–244.
- Dustin ML, Springer TA. Role of lymphocyte adhesion receptors in transient interactions and cell locomotion. *Annu Rev Immunol* 1991; 9: 27–35.
- Dimitriadou V, Buzzi MG, Moskowitz MA, Theoharides TC. Trigeminal sensory fiber stimulation induces morphological changes reflecting secretion in rat dura mater mast cells. *Neuroscience* 1991; 44: 97–112.
- Wiesner-Menzel L, Schulz B, Vakilzadeh F, Czarnetzki BM. Electron microscopical evidence for a direct contact between nerve fibers and mast cells. *Acta Derm Venereol (Stockh)* 1981; 61: 465–469.
- Bienenstock J, Tomioka M, Matsuda H, Stead RH, Quinonez G, Simon GT, et al. The role of mast cells in inflammatory processes: evidence for nerve/mast cell interactions. *Int Arch Allergy Appl Immunol* 1987; 82: 238–243.