

Acquired Malalignment: A Complication of Lateral Longitudinal Nail Biopsy

DAVID A. R DE BERKER¹ and ROBERT BARAN²

¹Department of Dermatology, Bristol Royal Infirmary, Bristol, England and ²Nail Diseases Centre, Cannes, France

We report the development of malalignment of the nail following lateral longitudinal biopsy of the nail unit in seven subjects. The lateral biopsies were in excess of the routine 3 mm diagnostic biopsy performed for investigation of a nail dystrophy, being indicated for excision of focal pathology. Deviation of the distal nail towards the side of excision might be accounted for by one or both of two mechanisms. First, the matrix might become skewed by the unilateral loss of a ligamentous structure extending from the lateral ligament of the distal interphalangeal joint. Second, there may be a reduction of embedding of nail in the lateral nail fold on the operative side in spite of a thorough lateral nail fold reconstruction. This reduction may result in an unopposed inward force from the remaining nail fold. Key words: dystrophy; matrix; surgery. (Accepted May 13, 1998.)

Acta Derm Venereol (Stockh) 1998; 78: 468–470.

Lateral longitudinal biopsy of the nail unit is the standard definitive method of diagnostic biopsy in nail disease (1). Where the focus of destructive or neoplastic disease is limited to the lateral margin of one nail, this pattern of biopsy may also be

therapeutic (2). Longitudinal biopsy performed within the central region of the nail may produce chronic dystrophy with a nick in the tip of the nail or a complete split. Lateral biopsy has neither of these complications; the only permanent sequel being a reduction of nail width. We report seven cases in which a previously unreported complication arose in the form of acquired malalignment.

MATERIALS AND METHODS

Patients were treated and followed in one of two departments of dermatology between 1990 and 1995. Four men and 3 women (aged 42–66 years) required lateral longitudinal biopsy for diagnosis and removal of focal pathology on the lateral region of the nail matrix (2 of the thumb and 5 of the index finger). The disease for which excisional biopsy was indicated was squamous cell carcinoma ($n=3$), longitudinal melanonychia ($n=3$) and onychomatricoma ($n=1$). One patient was on medication (frusemide, diltiazem, atenolol).

Biopsy was performed under local anaesthetic with complete excision of the pathology from the nail bed to the matrix. In one case squamous cell carcinoma was excised using micrographic surgery, resulting in removal of a broad lateral zone of nail unit. In all except this last case, lateral nail fold reconstruction was performed (3) (Fig. 1) with removal of sutures at 10 days. No wound infection was seen. All subjects were followed for a minimum of 12 months, and the surgical outcome recorded photographically.

RESULTS

Orientation of the nail changed within 3 months of the procedure in all the reported cases. Deviation towards the excision margin was maximal and constant by 6 months (Fig. 2). In spite of lateral nail fold reconstruction, the lateral margin of the nail was less embedded in the nail fold on the operative side. The angle of the junction between the lateral and

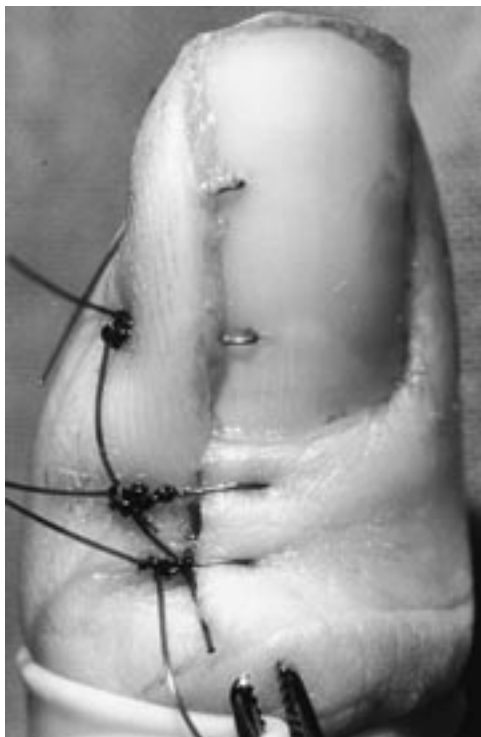

Fig. 1. Lateral nail fold reconstruction following excision of a longitudinal melanonychia in case 1.

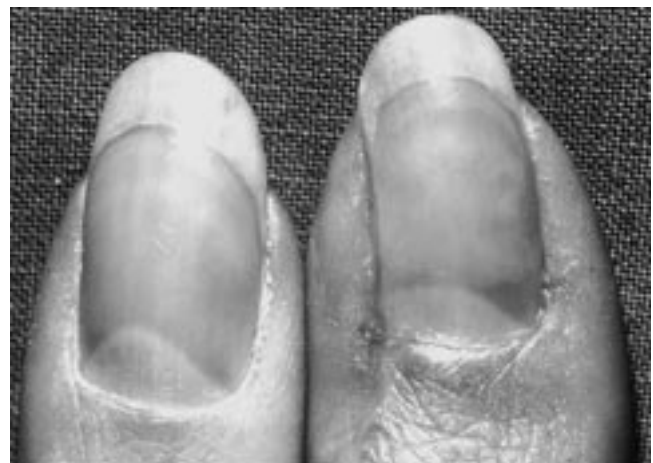

Fig. 2. Case 1, 6 months postoperatively, with acquired malalignment.

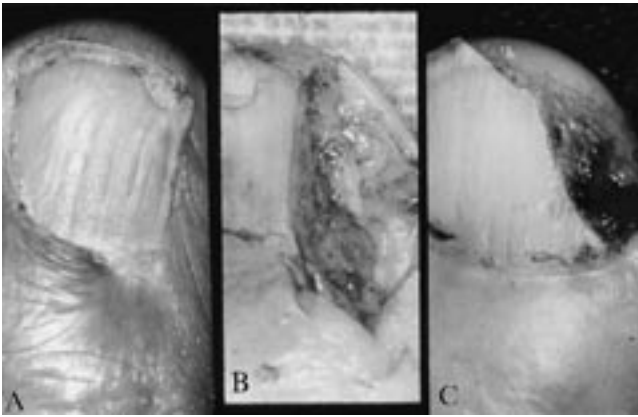


Fig. 3. A. The surface markings of the nail are malaligned across the entire nail and there is loss of embedding of the nail in the lateral nail fold on the operative side. B. Excision of tumour partially revealed in C.

proximal nail folds was more acute on the operative side, in contrast to the normal curve. Features of scarring, with loss of dermal substance, could also be seen at this site.

The longitudinal surface markings of the affected nails became curved to match the acquired deviation, such that the whole nail, and not just the lateral margin, appeared to be growing according to the new orientation (Fig. 3). This observation was corroborated by the constancy of the nail width when comparing the proximal and distal nail. Width measurements were made from projected transparencies of digits 6 months after surgery, giving a magnification of $\times 50$.

DISCUSSION

Our observation of acquired malalignment suggests that it is a potential complication following the excision of more than 3 mm of lateral nail unit. The operations were for excision of pathology, rather than routine diagnosis, and hence were larger than 3 mm in width. The measurement of remaining nail width was constant along the nail, meaning that the malalignment was genuine and not an appearance afforded by the splaying out of the distal part of the nail.

Nail malalignment in the absence of surgery is often associated with change in nail thickness and sometimes with pain. Both these features are probably due to a measure of ingrowing, where the nail embeds into the lateral nail fold. Inflammation is seen in some infants and younger individuals, whereas thickening of the nail is more common in older patients. This distinction may be because thickening will diminish the likelihood of nail cutting into the nail fold. Any physical factor obstructing longitudinal nail growth may be overcome by an increase in vertical growth, otherwise expressed as an increase in thickness. Pain and change in thickness were not seen in our series and this may be explained by the partial loss of the normal degree of embedding of the nail in the lateral nail fold on the operative side.

Rotation of any longitudinal structure can be accounted for by pushing or pulling in two opposite directions on either side of the axis. Given the postoperative anatomy of the nail unit, this effect could have been achieved by movement of the matrix towards the normal side, or movement of the distal half of the nail towards the excision margin (Fig. 4).

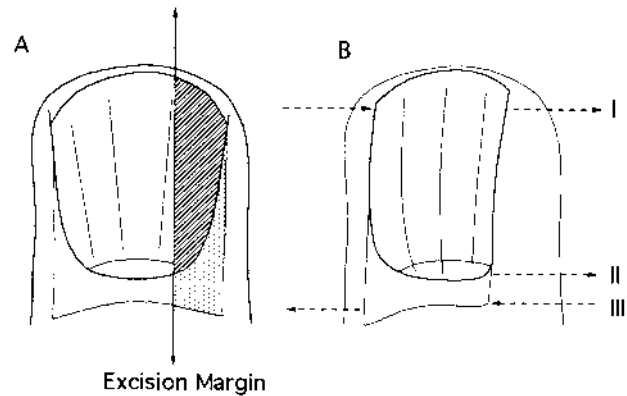


Fig. 4. A. A wide lateral longitudinal excision removing matrix and nail bed. B. (I) Illustrates force acting via intact lateral nail fold upon distal nail. (II) Outgrowth of distal matrix following surgery seems an unlikely explanation of malalignment. (III) Loss of tethering of the matrix on the operative side might allow the attachments on the normal side to draw the entire matrix away from the side of surgery.

Proximally, such an explanation would entail movement of the entire matrix towards the normal side. This could not be explained solely on the basis of scar tissue. However, Guero et al. have described the presence of a ligamentous structure comprising a dorsal expansion of the lateral ligament of the distal interphalangeal joint (4). This might normally place the matrix under a state of symmetrical tension, exerted in a proximal and lateral direction. The unilateral loss of this attachment could both release the matrix on the operative side and draw it to the normal side.

If the loss of the structure described by Guero et al. was to cause rotation of the nail unit, it would be necessary for the force to be acting around a fixed axis or to be matched by a second force acting in the opposite direction on the other side of the axis. Such a second force might be provided by imbalance of the lateral nail folds. In spite of the surgical reconstruction of the lateral nail fold, the width of the biopsies resulted in a reduction of lateral embedding on the operative side. When lateral nail folds are equal they may act symmetrically upon the nail, ensuring longitudinal growth. Our experience of congenital malalignment of the great toenail illustrates the effect of the lateral nail fold upon nail growth (5). It is likely that the reduction of the nail fold on one side allows the existing nail fold to exert an unopposed lateral force upon the emerging nail (Fig. 4). Alone, or in combination with a shift of matrix in the opposite direction, this could achieve malalignment.

A third possibility is that distal matrix regenerates beyond the wound margin after surgery in order to give the appearance of malalignment. However, the deviation of all the longitudinal surface nail markings and the constant width of the nail demonstrates that the malalignment was genuine and involved matrix on the normal and operative sides.

Congenital malalignment results in a thickened, discoloured nail with transverse ridges (6). This may be treated by surgical realignment of the entire nail unit (7). This treatment prevents obstruction of nail growth by the lateral nail fold, into which the malaligned nail is directed. It is this obstruction that gives rise to the changes in the nail plate, illustrating the significance of the lateral nail folds in nail morphology and direction of

growth. There is no clear understanding of the aetiology of the malalignment, although it appears to have a genetic basis (8). It is possible that the ligamentous structure proposed by Guero et al. is congenitally absent on one side and corrective surgery would, amongst other things, disrupt the intact ligament on the other side.

We conclude that malalignment of the nail is a potential complication of broad lateral longitudinal excisions from the finger or thumb. It is likely that this arises secondary to forces within the nail unit acting on the matrix and/or distal nail.

REFERENCES

1. Hanno R, Mathes BM, Krull EA. Longitudinal nail biopsy in the evaluation of acquired nail dystrophy. *J Am Acad Dermatol* 1986; 14: 803–806.
2. Baran R, Kechijian P. Longitudinal melanonychia (melanonychia striata). Diagnosis and management. *J Am Acad Dermatol* 1989; 21: 1165–1175.
3. Haneke E. Exzisions- und Biopsieverfahren. *Z Hautkr* 1988; 63 Suppl: 17–19.
4. Guero S, Guichard S, Fraitag SR. Ligamentary structure of the base of the nail. *Surg Radiol Anat* 1994; 16: 47–52.
5. Baran R. Congenital malalignment of toenail. *Arch Dermatol* 1980; 116: 1346.
6. Samman PD. Great toenail dystrophy. *Clin Exp Dermatol* 1978; 3: 81–82.
7. Baran R, Bureau H. Congenital malalignment of the big toenail as a cause of ingrowing in infancy. Pathology and treatment (a study of 30 cases). *Clin Exp Dermatol* 1983; 8: 619–623.
8. Barth JH, Dawber RPR, Ashton RE, Baran R. Congenital malalignment of the great toenails in two sets of monozygotic twins. *Arch Dermatol* 1986; 122: 379–380.