

Possible Role of Epidermal Growth Factor in the Lesional Skin of Nodular Morphea

Sir,

We have recently described a case of generalized morphea with nodular lesions (1). Here we report on the effect of epidermal growth factor (EGF) on the cultured fibroblast strains established from lesional skin.

Biopsy was performed from the macular and nodular morphea in a 52-year-old female (1). The biopsies were cut into three and one was fixed with 10% formalin solution for routine HE and toluidine blue stain for the identification of mast cells, one was snap-frozen in OCT compound (Miles Elkhart, IN) in liquid nitrogen and stored at -80°C ; the other was used for culture. Standard avidine-biotin peroxidase technique (Nichirei, Tokyo, Japan) was performed using anti-stem cell factor (SCF) antibody (Genzyme, Cambridge, MA) (diluted 1:200). The sections were developed with 3,3'-diaminobenzidine solution as chromogen and counterstained with hematoxylin, dehydrated, cleared and mounted. Negative controls were prepared by omission of the primary antibody, and by its substitution with an appropriately diluted, non-specific mouse IgG antibody.

Fibroblasts were cultured from nodular lesion, macular lesion, transitional inflammatory lesion, and uninvolved skin of the patient. Fibroblasts from the third passages in Dulbecco's modified Eagle's medium (DMEM) with 7% fetal calf serum (FCS) were seeded into a 96-well tissue culture plate (Falcon no. 3072, Becton Dickinson, NJ) at a density of 5×10^3 cells/well. Culture medium was discarded after 24 h and replaced with DMEM supplemented with 0.1% FCS. Twenty-four hours later, fibroblasts were stimulated by EGF (1-1, 000 ng/ml) (R&D Systems, Minneapolis, MN) for a further 24 h; 0.2 μCi /well of ^3H -thymidine was added to the culture medium for the last 6 h before harvesting. Fibroblasts were treated with 0.125% trypsin-0.01% EDTA at 37°C for 10-20 min and then harvested on a glass filter sheet by using a semiautomatic cell harvester (Labomash LM 101; Laboscience, USA). The radioactivity of the glass filter was counted using liquid scintillation counter.

The second passage cultured fibroblasts of each strain were seeded at 5×10^4 /well in a 24-well plate (Costar, Cambridge, MA). SCF concentration in the culture supernatant, both spontaneous and stimulated by varying concentrations of EGF for 24 h, was measured by enzyme-linked immunosorbent assay (ELISA) kit (Amersham, UK).

The induction of SCF gene expression of fibroblast-released factor on keratinocytes was examined using reverse transcriptase-polymerase chain reaction (RT-PCR). Human trichilemmal cell line, TL-1 (2) was seeded at 1×10^6 per dish (Falcon no. 3003) and stimulated by culture supernatants (10%) in DMEM supplemented with 7% FCS for 24 h. Total RNA was isolated from TL-1 using RNAzol (Cinna/Biotech Laboratories, Houston, TX), and then 100 ng of total RNA was reversely transcribed to cDNA with RAV-2 reverse transcriptase (Takara 2610B, Tokyo, Japan). PCR was performed in a solution containing 10 pmol/l of SCF-specific primer pairs (5' GGGCTGGATCGCAGCGC 3' and 5' CTCCACAAGGT-CATCCAC 3') (3). We used the following conditions for SCF mRNA preparation: 35 cycles each of denaturation at 95°C for 1 min, annealing at 47°C for 1 min and extension at 72°C for 2 min (decided in a preliminary experiment). PCR products were

electrophoresed in 1.7% agarose gel. The gel was stained with 1% ethidium bromide and visualized under ultraviolet light. To quantify the PCR products, the intensity of each band was measured by a densitometer (EPA-3000, Chemiway, Tokyo, Japan) and compared with that of β -actin. Results were expressed as mean \pm SD. Statistical analysis was performed using Student's *t*-test.

Histological examination of the nodular morphea showed dermal sclerosis with thickened collagen bundles, and thickened overlying epidermis. Toluidine blue stain revealed that numerous numbers of mast cells were also located in the papillary layer of the upper dermis between the elongated rete ridges in nodular morphea. Immunohistochemistry revealed that SCF was expressed on the keratinocytes of the acanthotic epidermis, fibroblasts in the lower dermis, endothelial cells and mast cells in both lesions of macular and nodular morphea; however, there was no significant difference in the staining intensity between these lesions.

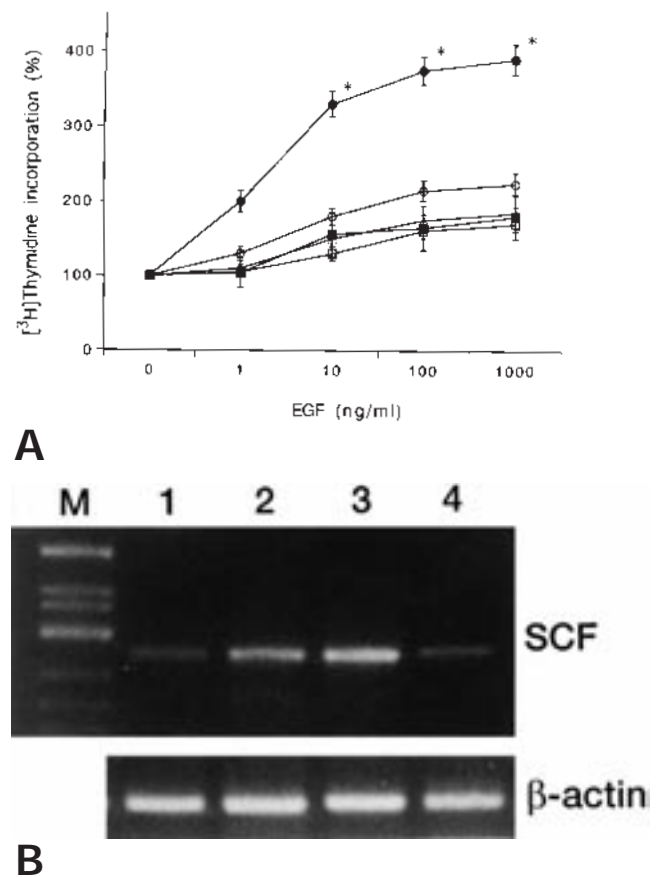


Fig. 1. (A) Effects of EGF on mitogenic response in nodular morphea-derived (●), macular morphea-derived (○), transitional lesion-derived (△), uninvolved lesion-derived (□) and normal (○) fibroblasts. (B) PCR assay for SCF gene expression in cultured TL-1 cells stimulated by supernatants of different fibroblast strains. M. Marker; lane 1, unstimulated TL-1 cells; lane 2, TL-1 stimulated by culture supernatant of macular morphea-derived fibroblasts; lane 3, TL-1 stimulated by culture supernatant of nodular morphea-derived fibroblasts; lane 4, TL-1 stimulated by culture supernatant of uninvolved skin-derived fibroblasts.

The value for $^3\text{H-TdR}$ incorporation in control wells that had no growth factors added was set at 100%. There was no significant difference in basal $^3\text{H-TdR}$ incorporation between morphea and normal fibroblasts (data not shown). The mitogenic response to EGF in fibroblasts derived from nodular morphea was significantly greater than that in the normal fibroblasts (330 ± 42 vs. $160 \pm 27\%$, $p < 0.05$) (Fig. 1A). The mitogenic response to EGF (1–1,000 ng/ml) increased in a concentration-dependent manner in morphea-derived fibroblasts and normal fibroblasts.

Fibroblasts derived from nodular morphea showed significantly greater SCF production in exposure to EGF dose-dependently, while other strains and normal fibroblasts presented within sensitive limits, even in exposure to EGF. EGF treatment (1,000 ng/ml) increased SCF production approximately 1.5-fold (44.6 pg/ml) as compared with spontaneous release (31.3 pg/ml).

SCF mRNA expression was strongly induced when stimulated by culture supernatant of fibroblasts derived from both macular and nodular morphea lesions, while that derived from uninvolved skin did not show any effects (Fig. 1B). Culture supernatant of normal skin derived fibroblasts did not show any effects. Densitometric quantitation revealed that there was approximately 2-fold and 4-fold greater accumulation of SCF mRNA in TL-1 stimulated by culture supernatant derived from macular and nodular morphea lesions respectively, as compared with unstimulated TL-1.

The interaction of mast cell granule constituents with connective tissue cells, extracellular matrix components and inflammatory cells suggests the participation of mast cells in the active fibrotic process including scleroderma, hypertrophic scar, and dermatofibroma. It is also easily speculated that there are interactions between fibroblasts and keratinocytes of the overlying epidermis; however, the pathogenesis is not fully elucidated as yet. In our case, histological examination of nodular morphea revealed thickened overlying epidermis and an increased number of mast cells in the upper dermis, which resembled the feature of dermatofibroma. SCF was also expressed in the keratinocytes of the overlying epidermis. There are possibilities that mast cell is increased in number via SCF, which influences mast cell proliferation and differentiation, released from dermal fibroblasts and keratinocytes. RT-PCR analysis showed that culture supernatant induced SCF mRNA expression on cultured keratinocytes *in vitro*. This suggests that fibroblast-derived factor may cause keratinocytes to release SCF, leading to an increased number of mast cells.

In turn, mast-cell-derived factor must also be considered.

Basic fibroblast growth factor (bFGF) is a candidate which has recently been reported to be expressed on human mast cells (4, 5). bFGF is a fibroblast growth factor, but also could be mitogenic for skin-derived keratinocytes (6, 7). In addition, we examined the effects of EGF on cultured fibroblast proliferation and SCF production, as EGF has a growth stimulatory activity for fibroblasts as well as keratinocytes. Results showed that nodular morphea-derived fibroblasts proliferated and produced a significantly elevated level of SCF by stimulation with EGF as compared with other site skin-derived and normal fibroblasts. These results correspond with the histological findings that mast cells are most increased in number in the lesion of nodular morphea in our patient. Our results suggest that there may exist some direct and/or indirect interaction mediated by mast cells between the fibrous lesion and overlying epidermis in the nodular morphea, and EGF may play a role in the induction of the local formation of nodular sclerosis.

REFERENCES

1. Sakashita S, Yamamoto T, Sawada Y, Katayama I, Nishioka K. A case of generalized morphea with nodular lesions. *Jpn J Dermatol* 1997; 107: 967–972 (in Japanese).
2. Kanzaki T, Eto H, Umezawa A, Maeda T, Iwase H, Ito M. Morphological, biological, and biochemical characteristics of a benign human trichilemmoma cell line *in vivo* and *in vitro*. *Cancer Res* 1981; 41: 2468–2475.
3. Longley BJ, Morganroth GS, Tyrrel L, et al. Altered metabolism of mast-cell growth factor (c-kit ligand) in cutaneous mastocytosis. *N Engl J Med* 1993; 328: 1302–1307.
4. Reed JA, Albino AP, McNutt NS. Human cutaneous mast cells express basic fibroblast growth factor. *Lab Invest* 1995; 72: 215–222.
5. Qu Z, Liebler JM, Powers MR, et al. Mast cells are a major source of basic fibroblast growth factor in chronic inflammation and cutaneous hemangioma. *Am J Pathol* 1995; 147: 564–573.
6. O'Keefe EM, Chiu ML, Payne RE. Stimulation of growth of keratinocytes by basic fibroblast growth factor. *J Invest Dermatol* 1988; 90: 767–769.
7. Ristow HJ, Messmer TO. Basic fibroblast growth factor and insulin-like growth factor I are strong mitogens for cultured mouse keratinocytes. *J Cell Physiol* 1988; 137: 277–284.

Accepted February 2, 1998.

Toshiyuki Yamamoto, Sayuri Sakashita, Yasuyuki Sawada, Ichiro Katayama and Kiyoshi Nishioka
Department of Dermatology, Tokyo Medical and Dental University, School of Medicine, 1-5-45 Yushima, Bunkyo-ku, Tokyo 113, Japan.