

White, Fibrous, Papular Lesions Associated with Systemic Lupus Erythematosus

Sir,

A variety of cutaneous manifestations have been described in association with systemic lupus erythematosus. We present a woman who developed multiple, whitish, papular lesions on the trunk. Histology of a biopsy specimen revealed proliferative changes of collagen fibres and fibroblasts in the dermis. It is likely that the eruption is closely related to systemic lupus erythematosus because the course of the lesions paralleled disease activity. To our knowledge, similar cutaneous lesions associated with systemic lupus erythematosus have not been described.

CASE REPORT

A 41-year-old woman was admitted to our hospital in October 1996 with a 1-month history of malaise, subfever, dyspnea on exercise, and haemoptysis. She also complained of cutaneous changes on the trunk which had been present for 3 months. Physical examination showed that whitish, firm papules, ranging from 2 to 3 mm in size, were found scattered on the anterior chest and upper back (Fig. 1). On the back there were also two elevated, scaly plaques with an atrophic, erythematous centre. Similar, scaly plaques were also seen on the earlobes. She had no swelling of the fingers or history of Raynaud's phenomenon.

Histology of a biopsy specimen from a whitish papule on the upper back revealed that closely packed collagen bundles and fibroblasts proliferated in relatively regular arrangement from the upper to lower dermis (Fig. 2). These proliferative changes were well demarcated from the surrounding connective tissue. A stain for elastic tissue showed a severe decrease of elastic fibres in the central, fibrous area. There was no evidence of mucin deposition. Specimens taken from an elevated, erythematous, scaly plaque showed fairly large amounts of mucin deposition between collagen bundles throughout the whole dermis. There were sparse inflammatory infiltrates. Hyperkeratosis, thinning of the stratum malpighii, and mild hydropic degeneration of basal cells were present.

Laboratory investigations revealed the following abnormalities: RBC $367 \times 10^4/\text{mm}^3$, haemoglobin 10.0 g/l, WBC $3000/\text{mm}^3$ (lymphocytes, 18%), erythrocyte sedimentation rate 82 mm/h, IgG 2118 mg/dl (normal, 870 to 2000), IgA 383 mg/dl (normal, 102 to 300), C3 20 mg/dl (normal, 45 to 100), C4 4 mg/dl (normal, 25 to 75). Urinalysis showed mild proteinuria, and protein excretion rates were approximately 400 mg per day. Abnormal results of serum studies for autoantibodies were as follows: antinuclear Ab 1: 1280 with speckled pattern,

anti-DNA Ab 90 IU/ml (normal, <7), anti-double strand DNA IgG Ab 55U/ml (normal, <7), anti-Sm Ab 1: 2, anti-SS-A Ab 1: 16. A chest X-ray showed diffuse acinar infiltrates in the bilateral basilar lung fields. Cultures of the sputum and bronchoalveolar lavage fluid were performed for bacteria, fungus and acid-fast bacilli, which were all negative. A diagnosis of systemic lupus erythematosus was made, and the pulmonary symptom was best regarded as lupus pneumonitis.

Treatment was started with intravenous methylprednisolone at a daily dose of 1000 mg for 3 days, followed by oral prednisolone 40 mg daily. Subfever, malaise, and haemoptysis resolved quickly, and abnormal results in both laboratory investigations and chest X-ray changes gradually improved. Papular lesions on the anterior chest and upper back became flattened, leaving slightly atrophic macules in 4 months. The erythematous, scaly plaque also subsided. The dose of prednisolone was tapered with no sign of relapse, and 5 months later, after admission, her disease was in remission with prednisolone 20 mg daily.

DISCUSSION

Whitish, papular lesions occurred prior to the development of systemic manifestations of lupus erythematosus by 2 months. Based on the clinical course, it is likely that these cutaneous lesions are closely related with disease activity of systemic lupus erythematosus, since cutaneous manifestations often precede visceral involvement in this disease. Concurrent atrophic, scaly, erythematous plaques on the upper back and earlobes were considered to be discoid lupus erythematosus, and abundant, dermal mucin deposition is known to be not infrequently encountered in discoid lupus erythematosus lesions.

Multiple dermatofibromas associated with autoimmune disorders have been reported (1). Among these cases, systemic lupus erythematosus is the most frequently associated condition. In most cases immunosuppressive medications were given prior to onset, or increase in number or size of dermatofibromas. These reports are different in many aspects from the present case in that the lesions are usually found scattered on the limbs as well as the trunk, larger in size, and the surface is pigmented. In addition, the eruption does not involute with improvement of associated disorders.

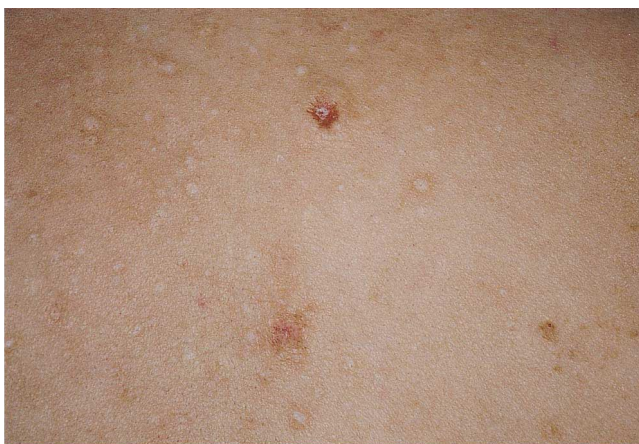

Fig. 1. Whitish papules and erythematous, scaly plaques on the back.

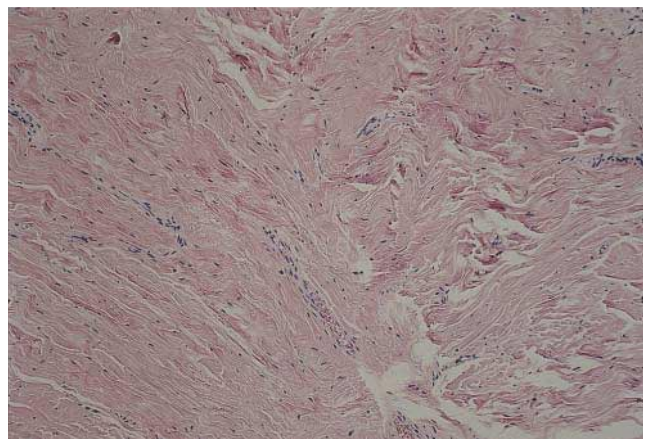


Fig. 2. Biopsy from a whitish papule with closely packed collagen bundles and fibroblasts in relatively regular arrangement (haematoxylin and eosin $\times 100$).

Eruptive histiocytoma (2) should be considered in the differential diagnosis. Papular lesions in this disorder are reddish or brown, and distributed extensively over the face, trunk and extremities. Histological features consist of relatively monomorphic, histiocytic infiltrate in the dermis without proliferation of collagen bundles. Thus the present case is distinctive from this rare disorder.

This patient had pneumonitis probably as a manifestation of systemic lupus erythematosus, which is a relatively rare symptom of this disorder. We speculate that the white, fibrous, papular lesions present in this case are linked to a particular clinical subtype with lupus pneumonitis.

Interestingly, Yamamoto et al. (3) demonstrated that serum from a systemic lupus erythematosus patient with multiple dermatofibromas had an enhanced capability to stimulate the proliferation of dermal fibroblasts.

REFERENCES

1. Cohen PR. Multiple dermatofibromas in patients with autoimmune disorders receiving immunosuppressive therapy. *Int J Dermatol* 1991; 30: 266–270.
2. Umbert IJ, Winkelmann RK. Eruptive histiocytoma. *J Am Acad Dermatol* 1989; 20: 958–964.
3. Yamamoto T, Katayama I, Nishioka K. Involvement of basic fibroblast growth factor in fibroblast-stimulatory serum activity of a patient with systemic lupus erythematosus and multiple dermatofibromas. *Dermatology* 1995; 191: 281–285.

Accepted December 10, 1997.

Kazuhito Hayakawa and Tetsuo Shiohara
Department of Dermatology, Kyorin University School of Medicine,
6-20-2 Shinkawa, Mitaka, Tokyo, 181, Japan.

Recalcitrant Molluscum Contagiosum in a Patient with AIDS Successfully Treated by a Combination of CO₂-laser and Natural Interferon Beta Gel

Sir,

Treatment of molluscum contagiosum in immunodeficient patients remains a major challenge (1, 2). Spontaneous resolution seen in immunocompetent patients does not occur in immunocompromised individuals. A large number of different therapy modalities, such as curettage, CO₂-laser and electrodesiccation, trichloroacetic acid, topical tretinoin and topical podophyllotoxin have been tried. However, no convincing data on successful treatment, either local or systemic, have been reported so far in the literature. In contrast to mucocutaneous herpes virus infections, no specific antiviral compound is available for molluscum contagiosum.

We describe a patient with AIDS and recalcitrant molluscum contagiosum who responded favourably and long-lasting to a combined CO₂-laser and local natural interferon (IFN) beta gel treatment.

CASE REPORT

A 50-year-old man with AIDS presented with widespread partially giant molluscum contagiosum predominantly located on the face and the beard region as well as on the forehead (Fig. 1). Similar lesions were seen in the retroauricular region, on the nipples, on the back and on the perianal skin. HIV infection was detected in 1989 and since 1991 disfiguring molluscum contagiosum lesions have been developing continuously. Also since 1991 the patient has suffered from cytomegalovirus-retinitis, which has led in the meantime to blindness. Additional important findings are severe oral candidosis, numerous Kaposi's sarcomas located on the extremities and on the trunk and in the oral cavity as well as postinflammatory pigmentation due to X-ray irradiation of Kaposi's sarcomas. Several therapies for the molluscum contagiosum located on the face, such as cryotherapy, podophyllotoxin 0.5%, curettage and CO₂-laser, were without success. Regularly, recurrence of lesions occurred some weeks after therapy. Further concurrent medication comprised intravenous foscarnet sodium (60 ml/kg body-weight per day) and oral fluconazol (400 mg per day). The most prominent

laboratory finding was the complete absence of CD4-positive T-helper cells and a negative CD4-/CD8-ratio, as well as absolute skin anergy to ubiquitous antigens in the delayed type hypersensitivity skin test (Multitest Mérieux).

The molluscum contagiosum lesions were removed in general anaesthesia using CO₂-laser (Swift Lase, Sharplan, Israel) evaporation flanked by rigorous smoke evacuation. After complete debulking of the lesions adjuvant interferon beta gel (0.1 Mio International Units natural interferon beta/1 g gel) (Fiblaferon Gel, Dr. Rentschler Arzneimittel, Laupheim, Germany) was given to the wounds five times a day for 4 weeks. Some circumscribed recurrences in the 3 weeks after ablation, consisting of small lesions, were removed using CO₂-laser under local anaesthesia. The remaining wounds were again locally treated with interferon beta gel as described. At perianal sites the combination of CO₂-laser and natural IFN-beta gel was combined with bathing in aqueous solutions of KMnO₄ up to three times per day.

With this treatment complete and long-lasting healing of molluscum contagiosum lesions was achieved (Fig. 1). During a follow-up of 6 months no further relapse of molluscum contagiosum was noticed. Besides some initial itching, no side effects were reported. Skin irritation, in particular, was absent. Keloid scar formation did not occur.

DISCUSSION

Widespread and giant molluscum contagiosum are important markers of advanced immunodeficiency (2, 3). Similar to human papillomavirus (HPV) infections, non-specific ablative therapy modalities have been used for molluscum contagiosum so far with marginal or no success in severely immunodeficient AIDS patients (1), especially in terms of recurrences. This is also true for both intralesional and single parenteral IFN therapy (1). In our hands, CO₂-laser ablation alone did not cure severe molluscum contagiosum in four patients suffering from AIDS (data not published).

The recently developed CO₂-laser Swift lase operating principle enables ablation of surface ultrathin char-free epithelial