

Sequential Therapy with Nimesulide and Ketotifen in Delayed Pressure Urticaria

Sir,

Physical urticarias are disorders of the skin occurring in subjects who are highly sensitive to varying appropriate physical stimuli. Delayed pressure urticaria (DPU) is characterized by the development of a painful/burning swelling at the site of application of pressure. The disease is probably underdiagnosed because of the varying interval (2–12 h) intercurring between stimulation and disease development. Antihistamines are usually of no practical benefit in the routine management of the disease (1). Large and prolonged administration of systemic corticosteroids have to be used to achieve a significant control of the disease. Obviously, in these circumstances, side effects are likely to be worse than the disease being treated. An alternative therapeutical approach with non-steroidal anti-inflammatory drugs (NSAIDs) might thus be expected to be useful. We selected nimesulide, a sulphonamide-derived agent, because it exhibits some interesting antiallergic properties: downregulation of immunologic and non-immunologic release of histamine from mast cells and basophils (2) and direct inhibition of H1-receptor (3). In an open-label trial carried out on 52 patients with varied forms of physical urticarias we have provided some support for the feasibility of a sequential approach with nimesulide and ketotifen (4). In the study presented here the efficacy and tolerability of this treatment regimen have been evaluated versus a taper of oral prednisone.

MATERIALS AND METHODS

Forty subjects with DPU (22 males and 18 females, aged 19–46 years) entered a randomized, double-blind trial. Chronic urticaria and/or dermatographism coexisted in 26 cases (65%). Criteria for selection included: good general health without evidence of peptic ulcer disease, blood hypertension, congestive heart failure, diabetes mellitus, or hepatocellular disease; no administration of systemic corticosteroids for at least 2 months prior to study onset; negative pregnancy test in women of childbearing age and agreement to the use of contraceptive measures throughout the trial course. A careful physical examination, complete blood cell count, blood chemistry and electrolyte analyses, and urinalysis were carried out at baseline and at study completion. All subjects had diagnosis confirmed through appropriate challenge testings performed by hanging a 7 kg weight across the forearm for 15 min. Readings were done at hourly intervals for a maximum of 12 h.

After giving informed consent, patients were randomly assigned to one of the following study groups. Group N+K received oral sequential therapy with nimesulide and ketotifen as follows: nimesulide 100 mg twice a day for 3 weeks (Phase 1); nimesulide 100 mg once a day (morning) and ketotifen 2 mg once a day (evening) for 2 weeks (Phase 2); ketotifen 2 mg twice a day for 2 weeks (Phase 3). Group P underwent a 7-week taper of prednisone consisting of: 40 mg a day for 3 weeks, 30 mg a day for 2 weeks, and 20 mg a day for 2 weeks. Patients were asked to keep a daily diary sheet recording all recurrences of DPU throughout the study period. All subjects were seen at weekly intervals in our outpatient department and response to treatment was monitored in terms of mean number of relapse episodes per week. The two treatment regimens were compared using a two-tailed, unpaired *t*-test. Pressure testings (as described above) were repeated the day after last assumption of the assigned study medication. The results were then categorized in accordance with the following 4-point scale: 3=no response after 12 h; 2 to 0=mild, moderate and severe response, respectively, within the same interval. Finally, Fisher's exact test for

2 × 2 contingency tables was used for statistical comparison of dichotomous variables (no response, score 3: yes/no) in the two study groups.

RESULTS

Of the forty subjects enrolled initially, 11 terminated the study early. Five dropouts occurred in the nimesulide + ketotifen group for the onset of mild gastrointestinal complaints during phase 1 (three cases) and mild to moderate sedation during phase 3 (two cases). In group P, treatment was discontinued during the first 4 weeks in 6 cases as a result of the following side effects: weight gain (>10%) (6 cases), moderate (<40%) blood hypertension (5 cases), headaches (2 cases), moderate (<65%) hyperglycemia (2 cases), and gastrointestinal complaints (1 case). In the other cases the sporadic occurrence of similar side effects neither precluded finishing treatment nor required other medications.

The clinical response obtained in the two study groups was overall homogeneous (Fig. 1). After therapy completion an average disease activity reduction from baseline of 93.1% was achieved in the nimesulide + ketotifen group and of 85.1% in the P group ($p=0.09$, Student's *t*-test). In addition, in both groups the effects on DPU activity paralleled overall those on possible concurrent forms of chronic urticaria and dermatographism, with complete resolution of symptoms in 23 out of 26 cases and significant improvement in the remainder. Finally, as for challenge testings carried out at the end of phase 3, no statistically significant difference was observed between pressure-suppressing response of the two regimens tested ($p=0.54$, Fisher's exact test), with full abolition of response in 11 out of 15 patients (73.3%) completing nimesulide + ketotifen treatment and 11 out of 14 patients (78.5%) completing P treatment. By contrast, mild to moderate (score 2 and 1, as specified in Methods) persistence of skin responsiveness was observed in the other cases.

DISCUSSION

High doses of corticosteroids very often remain the sole option eligible to obtain a significant control of DPU. Unfortunately, the occurrence of unacceptable side effects make these agents infeasible for long-term courses. To our knowledge, no controlled studies have so far been carried out to evaluate the potential ben-

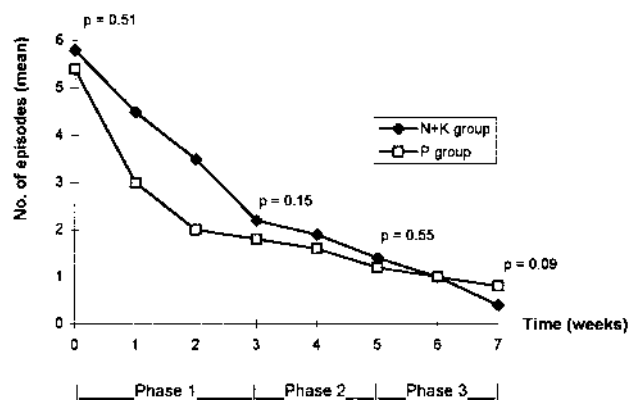


Fig. 1. Disease recurrences throughout the study period.

efits deriving from the use of safer, non-steroidal anti-inflammatory agents. In this double-blind controlled trial the outcome of sequential therapy with the NSAID nimesulide and the H1-antagonist ketotifen was substantially equivalent to that obtained with a 7-week taper of prednisone, with almost complete resolution of the disease at the end of both treatments. The response to the steroid was more prompt, with a sharp decrease of mean number of recurrences within the first 2 weeks; on the contrary, nimesulide + ketotifen therapy led to a slower but more continuous decline of disease activity. Unfortunately, because of the high number of patients lost to follow-up, too few data were available for proper statistical analyses of post-treatment outcome. Nevertheless, we believe that the results obtained support the possibility that the preliminary administration of a non-steroidal agent is able to lower the response threshold of DPU to antihistamines. Future follow-up studies will verify this hypothesis.

REFERENCES

1. Dover JS, Kobza-Black A, Milford Ward A, Greaves MW. DPU.

- Clinical features, laboratory investigations, and response to therapy of 44 patients. *J Am Acad Dermatol* 1988; 18: 1289–1298.
2. Rossoni G, Berti F, Buschi A, Villa LM, Della Bella D. New data concerning the antianaphylactic and antihistaminic activity of nimesulide. *Drugs* 1993; 46: 22–28.
3. Astarita C, Franzese A, Sproviero S, Scala G, Ferrara AM, Raucci G. La nimesulide è una valida alternativa terapeutica nei pazienti con reazioni avverse da farmaci antinfiammatori non steroidei e modula nell'uomo la risposta cutanea alla istamina e alla codeina. Personal communication at the Workshop: "Il controllo farmacologico dei mediatori dell'infiammazione: prospettive per gli anni 2000", Pomerio d'Erba, Italy 1991.
4. D'Argento V, Vena GA, Fiordalisi F, Panebianco R, Cassano N, Foti C. La nimesulide nel trattamento dell'orticaria fisica. *Boll Dermatol Allergol Profess* 1996; 11: 105–111.

Accepted December 22, 1997.

G. A. Vena, V. D'Argento, N. Cassano and M. Mastrodonardo
Scuola di Specializzazione in Dermatologia, Università di Bari, Policlinico, piazza Giulio Cesare, IT-70124 Bari, Italy.

Lichen Planus and Hepatitis C Virus Infection: A Clinical and Virologic Study

Sir,

The possible link between hepatitis C virus (HCV) infection and lichen planus (LP) has been raised in some series which have shown a high prevalence of HCV markers in patients with lichen planus (1–4). Some evidence shows that the HCV genotype may be one of the factors influencing the severity and outcome of liver disease (5). In a French study, it has been found that all of the HCV genotypes common in patients with chronic HCV of this country could be detected in HCV-infected LP patients (6). We have evaluated here whether some clinical features and humoral immunologic abnormalities of LP patients are associated with specific HCV genotypes.

MATERIAL AND METHODS

The study included 13 consecutive patients (9 females, 4 males; mean age 63.9, range 29–78 years) with LP and HCV infection diagnosed at the Department of Dermatology of Hospital Universitario de la Princesa, Madrid, between December 1991 and March 1994. The diagnosis of LP was assessed by (i) clinical changes typical of LP and (ii) histopathologic examination of cutaneous and/or mucosal lesions. A group of 130 patients diagnosed as chronic hepatitis associated with HCV infection were selected as controls. The results were analysed using the chi-square test. Routine liver profile, immunoglobulins G, A and M, the antinuclear, smooth muscle, antimitochondrial, antiparietal cell, liver-kidney microsome, antithyroid autoantibodies and HCV antibodies were performed as described in our previous report (1). Nested polymerase chain reaction (PCR) was performed to detect HCV RNA using primers from the highly conserved 5' non-coding region of the HCV genome (7). Titrations of positive RNA were performed using semiquantitative PCR, by Amplicor HCV Monitor (Roche Diagnostic Systems, Branchburg, NJ). The method described by Stuyver et al. (8) was used for geno-

typing, which is now available as Inno-Lipa HCV II (Innogenetics N.V., Germany).

RESULTS

The clinical and laboratory features of patients with LP associated with the presence of HCV-RNA are summarized in Table I. Of the 13 patients with LP and HCV infection, 9 (69%) were infected with HCV genotype 1b, 3 (23%) with genotype 1a and 1 (8%) with genotype 2a/2c. The localization and duration of HCV-related LP patients was the same irrespective of the genotype of infecting HCV. In eight cases, LP was diagnosed at the same time as HCV infection and in five patients the diagnosis of LP was made 7 to 22 years after evidence of liver disease had been detected.

No significant differences existed between patients of both groups as to HCV-1 and HCV-2 types and subtypes, whilst HCV-3a was found in 10 and HCV 4c/4d in 5 patients with chronic C hepatitis. Patients with LP and HCV infection had abnormal transaminase levels and increased polyclonal gammaglobulin levels were observed in eight patients. Only two patients (15%) had serum antinuclear antibodies at a significant titer (>1/40) and antithyroid antibodies were found in two (15%), both being antithyroglobulin. These immunologic abnormalities were observed in patients infected with the serotypes 1 and 2.

DISCUSSION

In this series of 13 HCV-positive consecutive patients with LP, HCV RNA has been detected, reflecting an active replication of the virus. The HCV RNA levels in serum were high in 12 of these patients and the HCV genotype associated to LP was