

## LETTERS TO THE EDITOR

### Juvenile Generalized Pustular Psoriasis

Sir,

Generalized pustular psoriasis refers to a group of disorders characterized by a widespread eruption of sterile pustules. In 1910 von Zumbusch described a patient who had had psoriasis vulgaris from childhood and who later developed generalized pustulation (1). He observed the patient through nine episodes of generalized pustulation, spanning 10 years. Generalized pustular psoriasis is extremely rare in childhood; only 100 cases are reported in the literature (2, 3). In their series of 104 cases of generalized pustular psoriasis, Baker & Ryan observed only 5 children (4).

#### CASE REPORT

An 11-year-old boy presented with an 8-year history of a recurrent generalized pustular eruption. He suffered from fever, malaise and pain. On examination there were pustules on an erythematous basis, spreading all over the body. The pustules in some areas coalesced to form lakes (Fig. 1). Additionally, we found scattered erythematous plaques arranged in an annular pattern on the upper limbs and the trunk. The plaques were covered with superficial pustules. Laboratory evaluation revealed an increased leukocyte count of  $28 \times 10^9/l$ .

Treatment with acitretine (Neotigason®), 30 mg/day, was given, and an improvement occurred in the next 5 weeks. A massive desquamation of the whole skin preceded the healing.

#### DISCUSSION

Psoriasis vulgaris occurs in more than 59% of patients with generalized pustular psoriasis, and 25% have a positive family history (2). In a report of 27 children, Beylot et al. divided juvenile generalized psoriasis into 3 groups: Zumbusch pattern, annular pattern and mixed type (2). The Zumbusch pattern is characterized by waves of widespread eruption of sterile pustules, associated with constitutional symptoms such as high fever, malaise, anorexia and pain. Most patients with this pattern tend to develop psoriasis vulgaris. The annular pattern is a more frequent, subacute eruption and is characterized by erythema and pustules in a circinate pattern. This form can follow or precede the generalized form of pustular psoriasis.

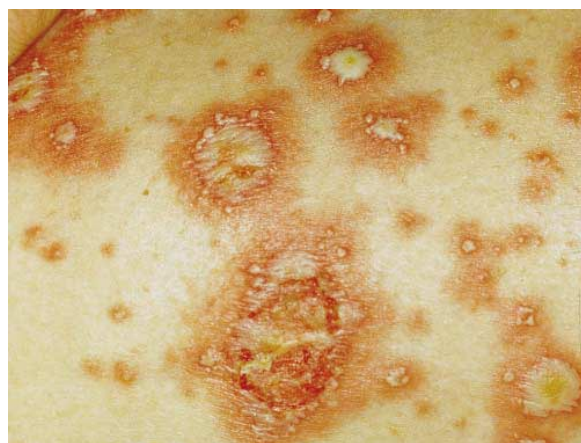


Fig. 1. Confluent pustulosis.

The mixed type has both Zumbusch and annular patterns. The case presented fits best into the mixed type of generalized pustular psoriasis. Various triggering factors have been identified, including infection, vaccination and steroids (5). Juvenile generalized pustular psoriasis can occur at any age, but the onset of the disease is often during the first year of life (2, 3). Unlike other forms of psoriasis, males are more affected than females (sex ratio 3:2) (2, 6).

The differential diagnosis of childhood generalized pustular psoriasis includes staphylococcal scalded skin syndrome, pityriasis rubra pilaris, toxic epidermal necrolysis, erythrodermic psoriasis, Reiter's disease, generalized candidiasis and generalized atopic dermatitis or seborrhoeic dermatitis (7).

The treatment of generalized pustular psoriasis in childhood is difficult. Regarding the benign course of the disease in most of the cases, initial treatment should be topical, e.g. topical steroids are useful.

In cases associated with severe systemic symptoms, oral etretinate is the treatment of choice (8, 9). Systemic steroids were not helpful (7). Methotrexate should only be used in children in very exceptional cases like universal pustular psoriasis (6). Hydroxyurea, PUVA and cyclosporin A are usually not recommended in children.

#### REFERENCES

1. Zumbusch L. Psoriasis und pustulöses Exanthem. Arch Dermatol Syph 1910; 99: 335–346.
2. Beylot C, Bioulac P, Grupper C, Desmons F, Larregue M, Maleville J. Generalized pustular psoriasis in infants and children. Report of 27 cases. In: Farber EM, Cox AJ, Jacobs PH, Nall L, eds. Psoriasis: Proceedings of the 2nd International Symposium. New York: Yorke Medical Books; 1977. p. 171–179.
3. Beylot C, Puissant A, Bioulac P, Saurat JH, Pringuet R, Doutre MS. Particular clinical features of psoriasis in infants and children. Acta Derm Venereol (Stockh) 1979; Suppl 87: 95–97.
4. Baker H, Ryan TJ. Generalized pustular psoriasis: a clinical and epidemiological study of 104 cases. Br J Dermatol 1968; 80: 771–793.
5. Barta U, Wollina U. Psoriasis pustulosa. In: Wollina U, Hein G, Knopf B, eds. Psoriasis und Gelenkerkrankungen. Jena, Stuttgart: Gustav Fischer Verlag; 1996. p. 43–47.
6. Nyfors A. Psoriasis in children: characteristics, prognosis and therapy. A review. Acta Derm Venereol (Stockh) 1981; Suppl 95: 47–53.
7. Zelickson BD, Muller SA. Generalized pustular psoriasis in childhood. Report of thirteen cases. J Am Acad Dermatol 1991; 24: 186–194.
8. Rosinska D, Wolska H, Jablonska S, Konca I. Etretinate in severe psoriasis in children. Pediatr Dermatol 1988; 5: 266–272.
9. Shelnitz LS, Esterly NB, Honig PJ. Etretinate therapy for generalized pustular psoriasis in children. Arch Dermatol 1987; 123: 230–233.

Accepted October 20, 1997.

Theodor Karamfilov, M.D. and Uwe Wollina, M.D.\*  
Department of Dermatology, Friedrich Schiller University of Jena,  
Erfurterstr. 35, D-07740 Jena, Germany.

\* Address for offprints.