

## LETTERS TO THE EDITOR

### Unusual Suction-like Contact Dermatitis due to ECG Electrodes

Sir,

Small haemorrhagic lesions at the sites of application of ECG electrodes are frequently noticed. These signs are mainly due to physical factors, such as suction. We report an unusual case of allergic contact dermatitis from para-phenylenediamine (PPD) on the thorax of an elderly man after ECG monitoring.

#### CASE REPORT

A non-atopic 74-year-old man complained of itching vesicular dermatitis on the left side of his thorax, which had flared up 8 days earlier, after a prolonged ECG monitoring.

On inspection, many tense erythematous vesicular lesions, strictly arranged in a ring-shape, were observed at every site of application of the electrodes (Fig. 1). Due to the particular shape of the dermatitis a suction reaction was hypothesized. In spite of this, patch tests with GIRDCA series, emulsifiers and fragrance series were performed. Patch tests were also carried out with the ECG gels (as is) used in the out-patient clinic that the patient had visited and with the various excipients of the gels used, as well as with the allergens related to ECG monitoring deduced by a review of the literature (1, 2): polyvinylpyrrolidone as is, tartrazine 1% pet., methylparaben 3% pet., ethylparaben 3% pet., propylparaben 3% pet., buthylparaben 3% pet., hydroxyethylcellulosa 50% alc. and aq. ·

Patch tests were all negative except for PPD, which showed a strong positive reaction (+ at 48 h/+++ at 72 h).

Inspection of the electrodes revealed that the part which had come into contact with the skin was made of black rubber (Fig. 2).

#### DISCUSSION

The allergic reactions that appear after ECG monitoring may be caused by ECG gels or pastes, alcohols found on

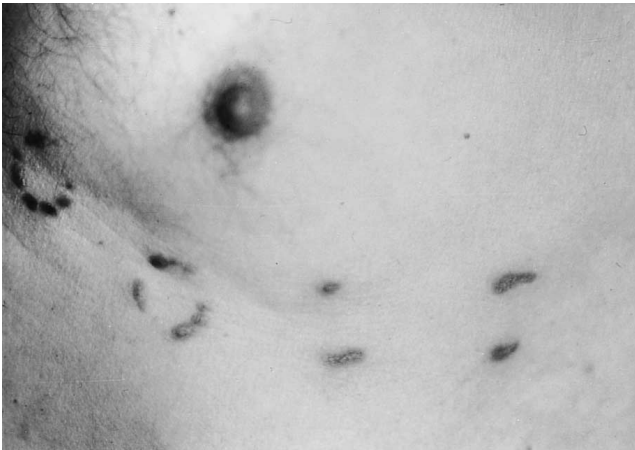

Fig. 1. Vesicular lesions, arranged in a ring-shape, at every site of application of the electrodes.




Fig. 2. The electrode made of black rubber.

pre-packaged gauzes, metal electrodes and pads used as a substitute for ECG paste.

Parabens (1, 2), propyleneglycol, parachlorometaxylenol, dyes or pine oil (2) are the allergens most frequently involved in contact hypersensitivity to ECG gels or pastes. Allergy to various types of topically applied alcohols, such as isopropyl-alcohol and ethylalcohol, has also been described (3). Dermatitis may be due also to nickel-plated ECG electrodes or to rubber straps, which are sometimes used to fasten the ECG electrodes.

Our patient showed a unique sensitization to PPD, a component of black rubber. To our knowledge, allergy to PPD, after ECG monitoring, has never been reported in the literature. This unusual contact dermatitis, apparently not connected with ECG devices, occurred due to the particular composition of the electrodes made of rubber.

#### REFERENCES

1. Uter W, Schwanitz HJ. Contact dermatitis from propylene glycol in ECG electrode gel. *Contact Dermatitis* 1996; 34: 230–231.
2. Rietschel RL, Fowler GF jr. *Fisher's Contact dermatitis*. 4th edn. Baltimore: Williams & Wilkins; 1995. p. 429–432.
3. Lewes D. Electrode jelly in electrocardiography. *Heart J* 1965; 27: 105.

Accepted August 15, 1997.

M. Corazza, C. Maranini, W. La Malfa and A. Virgili  
Department of Dermatology, University of Ferrara, V. Savonarola 9,  
I-44100 Ferrara, Italy.