

## Pemphigus Vulgaris Induced by Honeybee Sting?

Ülker Gül, Müzeyyen Gönül\*, Seray Külcü Çakmak and Arzu Kılıç

Ankara Numune Education and Research Hospital, 2nd Dermatology Clinic, Sıhhiye, Barış Mah. Güzelyaka Cad. Demetkent sit. B-2 Blok, No. 44 Yenimahalle, Ankara, Turkey. \*E-mail: muzeyyengonul@yahoo.com

Accepted April 20, 2006.

Sir,

Pemphigus is an autoimmune disease characterized by blistering on the skin and mucosas. The blisters develop due to loss of epidermal cell-to-cell adhesion (acantholysis) triggered by auto-antibodies developing against cell surface antigens of keratinocytes. Pemphigus has a chronic progress, with 10% mortality and high morbidity also due to the treatment (1–5).

The aetiology of pemphigus is not known exactly. Wide variations in incidence rates, clinical features, and demographic characteristics among countries lead to a suspicion of different risk factors (1).

### CASE REPORT

A 63-year-old male attended beekeeper our clinic with blistering on his whole body. He said he had been stung by hundreds of honeybees on his legs 2 months previously. He had not previously been stung by so many honeybees. He did not have history of allergy to bee venom. The lesions started one month after the bee stings on his legs (on the area of the bee sting) and then spread to his whole body (Fig. 1). On dermatological examination a few erosive lesions were observed on the buccal mucosa and soft palate, and 0.3–3 cm sized, flask blisters and erosive lesions on his extremities and trunk. Some of the blisters had erythematous bases. Laboratory examination did not reveal any pathological findings except an iron deficiency anaemia. No microorganism was isolated from the blister fluids with bacterial culture. Intra-epidermal acantholysis on direct histopathological examination and positive staining with

honeycomb-shaped IgG in the intercellular area were observed on direct immunofluorescence examination (Fig. 2). He was therefore diagnosed with pemphigus vulgaris. Corticosteroid (120 mg/day) and azathioprin (150 mg/day) therapies were started orally. His lesions regressed significantly after treatment for 20 days.

### DISCUSSION

The aetiology of pemphigus is still not exactly known. A strong association of pemphigus with Class II genes has been demonstrated (4, 6). Some drugs such as D-penicillamine have been reported to induce pemphigus. Because there were several reports of pemphigus occurring during pregnancy or with the use of oral contraceptives, hormonal factors have been suggested (7). The potential role of sunlight in the pathogenesis had also been hypothesized, but the mechanism is not clear (1, 4). Environmental factors were thought to be responsible in the aetiopathogenesis of the disease because of its epidemiological features in Brazil and a significant association between pemphigus and frequent exposure to black fly was found in a case-control study (8). Bastuji-Garin et al. (1) investigated patients with pemphigus regarding socioeconomic status, medical history, drug intake, lifestyle, and environment in a multi-centre case-control study in Tunisia. They identified a dose-dependent relationship between pemphigus and traditional cosmetics. In this study, while any association between exposure to black fly and pemphigus was not found, a significant correlation between wasp, bee and spider stings and pemphigus was also found (1)

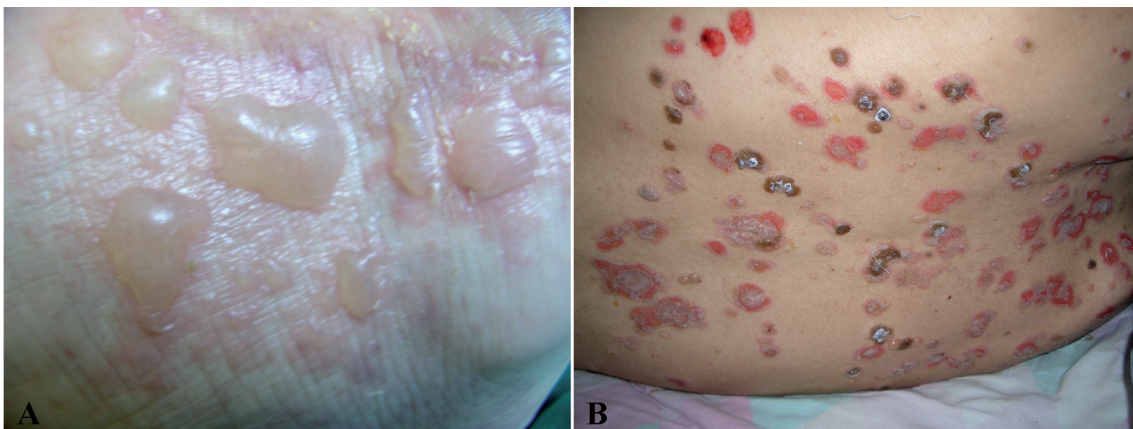

Fig. 1. Bullae (A) on the patient's foot, and (B) subsequently spread to the whole body.

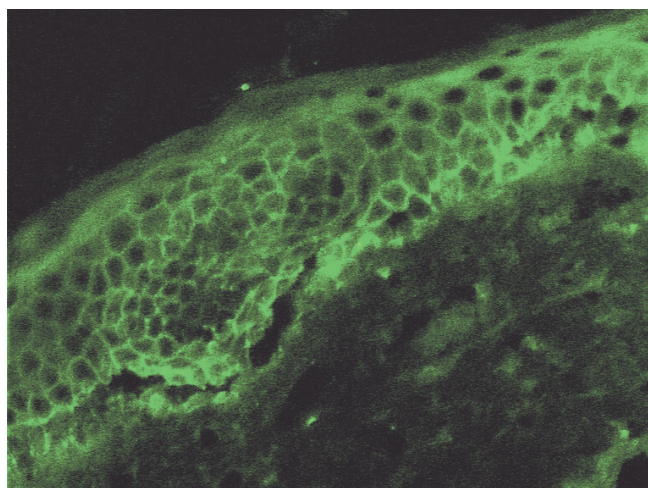


Fig. 2. Positive staining with honeycomb-shaped IgG in the intercellular area on direct immunofluorescence examination. The histology also shows acantholysis.

We think that bee stings are a possible trigger factor for pemphigus because our patient's lesions started on the sting localization and one month after hundreds of bee stings.

How the bee sting triggers pemphigus is unknown. Venom is a complex mixture of many substances, such as toxins, enzymes, growth factor activators and inhibitors. These constituents interact in the body with a large number of proteins and receptors, and this interaction determines the eventual inflammatory effect of the compounds. Venom is known to trigger the release of some cytokines and nitric oxide (9, 10). These cytokines play important roles in mediating cell recruitment and activation necessary for inflammation (10). It was reported that Th2-like cytokines were shown in the lesional skin of the patients with pemphigus and Th2 cells might be responsible for early stage of autoimmune response (11).

Koebner phenomenon in pemphigus vulgaris has been reported previously (12). As the lesions appeared at the sting site we think that this may represent a Koebner phenomenon.

We do not know how the bee sting triggered pemphigus in our case. Either antigenic stimulation was triggered by the bee sting or a microorganism transported by the bee, or another unknown mechanism may have triggered the autoimmune response. We believe that detailed studies may shed light on this relationship in the future.

## REFERENCES

1. Bastuji-Garin S, Turki H, Mokhtar I, Nouira R, Fazaa B, Jomaa B, et al. Possible relation of Tunisian pemphigus with traditional cosmetics: a multicenter case-control study. *Am J Epidemiol* 2002; 155: 249–256.
2. Oostingh GJ, Sitaru C, Kromminga A, Dormann D, Zillikens D. Autoreactive T-cell responses in pemphigus and pemphigoid. *Autoimmun Rev* 2002; 1: 267–272.
3. Anhalt GJ, Díaz LA. Pemphigus vulgaris – a model for cutaneous autoimmunity. *J Am Acad Dermatol* 2004; 51: 20–21.
4. Martel P, Joly P. Pemphigus: Autoimmune diseases of keratinocyte's adhesion molecules. *Clin Dermatol* 2001; 19: 662–674.
5. Payne AS, Hanakawa Y, Amagai M, Stanley JR. Desmosomes and disease: pemphigus and bullous impetigo. *Curr Opin Cell Biol* 2004; 16: 536–543.
6. Gazit E, Loewenthal R. The immunogenetics of pemphigus vulgaris. *Autoimmunity Reviews* 2005; 4: 16–20.
7. Goldberg NS, DeFeo C, Kirshenbaum N. Pemphigus vulgaris and pregnancy: risk factors and recommendations. *J Am Acad Dermatol* 1993; 28: 877–879.
8. Lombardi C, Borges PC, Chaul A, Sampaio SA, Rivitti EA, Friedman H, et al. Environmental risk factors in endemic pemphigus foliaceus (Fogo selvagem). "The cooperative group on Fogo Selvagem research". *J Invest Dermatol* 1992; 98: 847–850.
9. Cuence E, Fraguas J, Peña JE, Peña F, García JC, González M. Beekeepers' arthropathy. *J Rheumatol* 1999; 26: 2684–2688.
10. Petricevich VL. Cytokine and nitric oxide production following severe envenomation. *Curr Drug Targets Inflamm Allergy* 2004; 3: 325–332.
11. Caproni M, Giomi B, Cardinali C, Salvatore E, Pestelli E, D'Agata A, et al. Further support for a role for Th2-like cytokines in blister formation of pemphigus. *Clin Immunol* 2001; 98: 264–271.
12. Hameed A, Khan AA. Koebner phenomenon in pemphigus vulgaris. *Br J Dermatol* 1996; 135: 152–153.