

## 4. Treatment of Non-Melanoma Skin Cancer: Immunotherapy as a Viable Option

STEPHEN SHUMACK and DARRELL RIGEL

### INTRODUCTION

Non-melanoma skin cancer (NMSC) is generally considered to be a worldwide epidemic. Current estimates predict that between 0.9 and 1.2 million new cases will be diagnosed each year in the United States of America (USA), which is one-third of all cancers diagnosed (1). In Australia, the incidence of NMSC continues to rise and it now affects at least 1% to 2% of the population annually (1, 2). NMSC tends to affect Caucasians particularly in areas exposed to sunlight, such as the head, neck and back of the hands. There is an increased risk with fair skin, blue eyes and a history of repeated sunburns (1).

There are two main forms of NMSC, basal cell carcinoma (BCC) and squamous cell carcinoma (SCC), which account for 80% and 16% respectively (1). The majority of BCCs present as two varieties. Nodular BCC (nBCC) appears mostly on the head and neck and accounts for approximately 60% of all BCCs (3). Most of the remainder are superficial BCC (sBCC), which occur on the trunk and extremities (4, 5). Standard treatments for BCCs include excision, curettage and electrodesiccation, and cryosurgery (6). Other forms of treatment such as Mohs micrographic surgery, intralesional interferon (7) and radiotherapy, may be used depending on the nature, site and size of the tumor (6). Actinic keratosis (AK) is considered by some to be the earliest clinically recognizable manifestation of SCC *in situ* (8, 9). The risk of progression of AK to invasive SCC has been reported as ranging from 0.25 to 20% within 10–25 years (8, 10, 11). Sun avoidance measures and sunscreen protection are the first steps in the therapy of AK. The conventional approaches for treating AKs include cryotherapy, electrodesiccation and curettage, excision, CO<sub>2</sub> laser therapy, 5-fluorouracil (5-FU), chemical peels and photodynamic therapy (12).

Recently, topical immunotherapy in the form of imiquimod 5% cream has demonstrated efficacy for the treatment of BCC and AK. Imiquimod, an immune response modifier, has demonstrated in pre-clinical studies to have both antiviral and antitumor activity *in vivo* (13). It is currently recommended for the treatment of external genital warts induced by human papillomavirus (14–16). This paper reviews the evidence of the safety and efficacy of imiquimod for the treatment of BCC and AK.

### IMIQUIMOD FOR THE TREATMENT OF BASAL CELL CARCINOMA

A series of phase II dose-response trials have been undertaken to study the safety and efficacy of imiquimod 5% cream for the treatment of BCC (17–20). Beutner et al. (17) conducted a pilot study to demonstrate the effectiveness of imiquimod for the treatment of BCCs. Thirty-five patients were randomized 2:1 to receive imiquimod or vehicle cream in four dosage regimens, twice daily, daily, three times a week, and twice a week for up to a maximum of 16 weeks. Complete histological clearance was observed in patients in the twice daily, once daily and three times a week groups and partial clearance was noted in the other dosage groups. The majority of patients experienced local skin reactions, mainly erythema, which increased as the imiquimod dosage increased.

Subsequently, a multi-center, randomized, open-label, dose response study was performed (18), with a total of 99 patients who applied imiquimod 5% cream to their sBCC lesions for six weeks. Patients were randomized to one of four dosing regimens, twice daily, once daily, twice a day three times a week, and once a day three times a week. The twice daily dosing was discontinued, as this frequency was not well tolerated due to the severity of the local skin reactions. In the intent-to-treat analysis, a complete response rate of 78% (77/99) was reported for all patients enrolled in the study (18). The complete clearance rates, as assessed histologically six weeks post treatment, were highest in the twice daily (100%, 3/3) and once daily treatment groups (88%, 29/33), reducing to 70% (23/33) in the three times a week regimen (Fig. 1) (18). Fig. 2 shows the typical response of sBCC to imiquimod therapy applied daily for six weeks. As with all patients the cosmetic result was excellent at the six week post-treatment visit. The findings of this study suggest that there is a direct correlation between effectiveness and dosing frequency for imiquimod. Similarly, the reported application site reactions and local skin reactions also decreased with lower dosing frequency (Fig. 3). Future studies are needed to better assess the frequency of local skin reactions in relation to the dosing of imiquimod.

A multi-center, randomized, double-blind, vehicle-controlled trial of imiquimod for sBCC has also been reported (19). A total of 128 patients were enrolled and randomized to 12 weeks of treatment with imiquimod

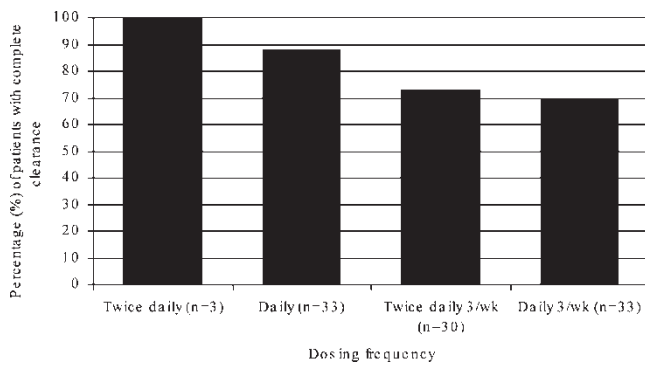


Fig. 1. Results of a six week multi-center dose response trial for the treatment of sBCC with imiquimod 5% cream (adapted from Marks *et al*<sup>18</sup>). The graph shows complete clearance increases as dosing regimen increases, based on intention-to-treat analysis.

5% cream ( $n=92$ ) or vehicle cream ( $n=32$ ), in one of four dosing regimens, twice daily, once daily, five times a week and three times a week. The efficacy was similar to the previous study, with an intent-to-treat clearance rate of 87% for the once daily regimen, even though the treatment period was longer (12 weeks versus 6 weeks) (19). This study concluded that imiquimod was effective in clinical and histological clearance. Patient compliance was excellent and again, local adverse reactions were dose dependent.

In order to establish a safe and efficacious dosing regimen for the treatment of primary nBCC with imiquimod 5% cream, two phase II open-label, randomized, dose-response trials evaluating four dosing regimens have recently been reported (21). The studies enrolled

99 patients in the six-week study and 93 patients in the 12-week study. In the six-week study patients applied imiquimod once a day for 3 or 7 days to twice a day for 3 or 7 days. In the 12-week study, imiquimod or vehicle cream was applied once a day for 3, 5 or 7 days, or twice a day for 7 days. The findings suggest that dosing once a day for 7 days a week results in the highest clearance rate, with 71% of the patients in the six-week study and 76% in the 12-week study showing complete clearance of their tumor (25/35 and 16/21, respectively). These studies have indicated that imiquimod 5% cream represents another treatment option for nBCC (21).

The effects of occlusion on the efficacy and safety of imiquimod treatment for BCC were investigated in an open-label study (20). Ninety-three patients with sBCC and 90 patients with nBCC were randomized to four different treatment groups, twice a week and three times a week, with and without occlusion for a period of six weeks. The clearance rate for patients treated three times a week for six weeks was 76% without occlusion and 87% with occlusion (65% with occlusion, 50% without occlusion for nBCC) (20). Occlusion moderately increased the efficacy of imiquimod; however, a higher frequency of local skin reactions, such as erythema and edema was also observed in this group.

The successful treatment of a large sBCC with imiquimod 5% cream has been illustrated recently in a case study (22). Chen *et al.* (22) reported the total clearance of a large sBCC on the right dorsal arm of a 52-year-old female. The lesion had been present for 28 years and measured 5cm x 6cm. Standard treatment

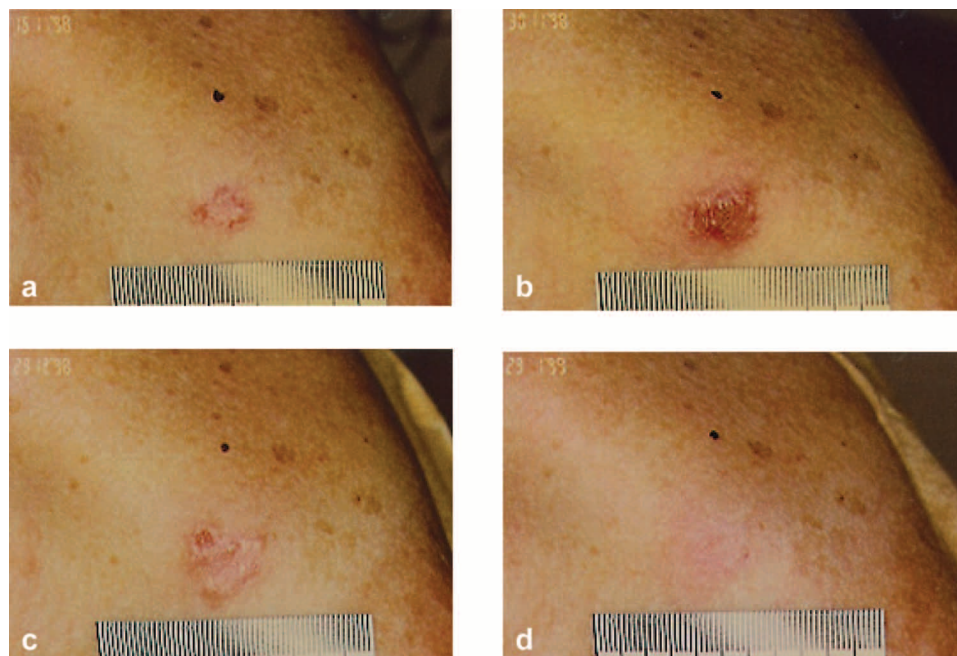


Fig. 2. Patient with sBCC on left shoulder successfully treated with imiquimod 5% cream applied daily; a) pre-treatment, b) after 2 weeks of treatment, c) after 6 weeks of treatment (end of treatment), d) 6 weeks post treatment.

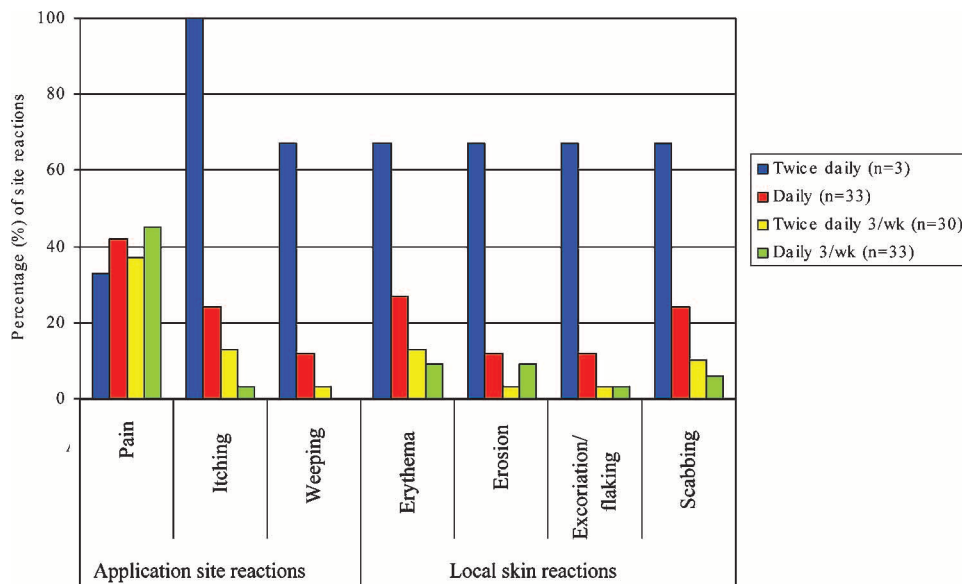


Fig. 3. Frequency of application site reactions reported by patients and the four most frequently reported severe local skin reactions as assessed by the investigators, in a six week multi-center dose response trial (adapted from Marks *et al*<sup>18</sup>). No patients discontinued the study because of local skin reactions.

options were considered, including Mohs micrographic surgery and curettage followed by electrodesiccation. The patient agreed to a non-surgical approach and topical imiquimod 5% cream was applied three times a week for 12 weeks. Local skin reactions of erythema and ulceration were observed, but the patient did not require rest intervals from the therapy. At a follow-up visit, 10 months after the end of treatment, there was no clinical or histological evidence of BCC (22).

Imiquimod may also have potential for the treatment of patients with multiple BCCs. There have been a number of case reports that illustrate the potential of imiquimod 5% cream for the treatment of BCCs presented in patients with Gorlin-Goltz syndrome (23, 24). This syndrome, basal cell nevus syndrome, is an inherited genetic disorder with autosomal dominant pattern, high penetrance and variable expressivity. The definitive treatment option for multiple BCCs in Gorlin-Goltz syndrome is still a matter of debate, with surgical excision being the primary modality used. Cryotherapy, CO<sub>2</sub> laser surgery (25) and electrodesiccation and curettage are also used. Kagy and Amonette (23) reported the successful use of imiquimod 5% cream for the treatment of sBCC in a patient with Gorlin-Goltz syndrome. Three biopsy-proven sBCCs were treated with imiquimod 5% cream daily for 18 weeks. There was no clinical or histological evidence of the lesions after treatment. Local skin reactions were observed in the patient, which were tolerated. Stockfleth *et al.* (24) have also successfully used imiquimod 5% cream in three patients with Gorlin-Goltz syndrome, presenting with multiple recurrent BCCs. The patients were treated two to three times a week, for a period of 6–8 weeks.

There were no histological or clinical signs of BCC reported during the 12 months of follow-up.

These trials (17–20) and other case studies (22–24) have all demonstrated good cosmetic results after imiquimod treatment. The dosing regimen of once daily application appears to show promising efficacy, although the findings need to be confirmed in Phase III studies using larger numbers of patients.

#### IMIQUIMOD FOR THE TREATMENT OF ACTINIC KERATOSIS

There have been a number of trials conducted to study the use of imiquimod 5% cream for the treatment of AK (26–30). A pilot study by Edwards *et al.* (26) was the first to report the potential of imiquimod for the treatment of AK. Patients were enrolled in a double-blind study, with a 2:1 randomization to imiquimod 5% cream or vehicle cream. The patients applied imiquimod until clinical resolution or for up to 16 weeks in four dosing regimens, twice daily, once daily, three times a week and once a week. The AK lesions were located on the head and neck, upper extremities and hands, and to a lesser degree on the upper anterior trunk. Of the 41 patients enrolled in the study, 27 received imiquimod therapy and of these 14 showed complete clearance, with partial response achieved in most of the remaining patients. This study demonstrated the clinical efficacy of imiquimod for the treatment of AK when compared to vehicle. Subsequently, Stockfleth *et al.* (27) reported the efficacy of imiquimod in six male patients with multiple AKs. Imiquimod 5% cream was applied to the AK lesions three times a week



for 6 to 8 weeks. However, at week 3 the application of imiquimod was reduced to twice a week in all patients, due to the presence of local skin reactions. There was no additional treatment required for the adverse events. The lesions were clinically and histologically clear in all patients and none of the patients experienced recurrence during the follow-up period, ranging from 2 to 12 months after treatment. Stockfleth et al. (28) have also conducted a randomized, double-blind, vehicle-controlled trial of patients with biopsy-proven AK. A total of 37 patients applied imiquimod 5% cream or vehicle cream to the lesions, initially for three times a week until the lesions had clinically resolved or for up to 12 weeks. For approximately half of the patients the frequency of application was decreased, due to local adverse reactions, from three times a week to twice a week or once a week. In over 80% of patients, lesions treated with imiquimod clinically and histologically cleared. Patient compliance was good, with all patients tolerating the 12-week course. Adverse events included erythema, edema, induration, erosion, ulceration and scabbing.

A trial in the USA has also investigated the safety and efficacy of imiquimod for the treatment of AK (29). Twenty-two, predominantly male, patients with AKs were treated with imiquimod 5% cream, initially three times a week until total clearance of lesions or up to eight weeks. The patients applied imiquimod to lesions on one side of the body and vehicle cream to the other side. Approximately half the patients required one rest period due to local skin reactions, after which the frequency of treatment was decreased from three times a week to twice a week. Of the 22 patients, 17 (77%) completed treatment and were evaluated at weeks 0, 2, 4, 6 and 8 of the treatment period and 4 and 8 weeks after the last application of imiquimod. A statistically significant reduction ( $p < 0.005$ ) in the average number of lesions was observed in those patients treated with imiquimod. The most frequent local skin reactions were erythema, itching and scabbing, although all adverse events were mild to moderate. In order to investigate alternative dosing regimens of imiquimod for AK, an open-label trial was conducted by Salasche et al. (30). Patients with 5–20 AK lesions per cosmetic unit (for example forehead, cheek) were treated with imiquimod 5% cream three times a week for 4 weeks followed by a rest period for 4 weeks (30). This cycle was repeated if AK lesions had not cleared, for up to a total of three cycles. Almost half of the sites (15/33) were cleared by the end of the first cycle (8 weeks) and a further third cleared by the end of the second cycle. Only a small proportion of patients required treatment for three cycles. In this trial it was also apparent that imiquimod treated both clinical and sub-clinical lesions and was effective in clearing both. These trials demonstrate that further large scale multi-center trials for

the treatment of AK are required to determine the appropriate dosing regimen of imiquimod.

#### *Bowen's disease*

Bowen's disease (BD) is a form of SCC *in situ*, which usually presents as an erythematous plaque. Ultraviolet light is thought to be the main risk factor, although human papillomavirus, radiation therapy, immunosuppression and arsenic ingestion have also been inferred in its pathogenesis (31, 32). Lesions are usually solitary but can be multiple in some patients. The risk of invasive malignancy development in these lesions has been estimated to be about 3% (33). Treatment options vary with body site and include cryotherapy, curettage, 5-fluorouracil (5-FU), excision, laser and photodynamic therapy (34). Large lesions, particularly on anatomical sites such as the shin or face, may be difficult to treat surgically.

Mackenzie-Wood et al. (35) conducted a phase II open-label study to investigate the efficacy of imiquimod for the treatment of BD. Sixteen patients with biopsy-proven BD, applied imiquimod 5% cream once a day for 16 weeks. Lesions were located predominantly on the legs and ranged from 1–5.4 cm in diameter. Biopsies were performed on the treated areas six weeks post-treatment. In 15 of the 16 patients a six-week post-treatment biopsy was obtained and in 14 of these 15 patients there was no residual BD on the post-treatment biopsies. Imiquimod induced local skin reactions in 15 of the 16 patients and in several patients with severe pre-existing sun damage, satellite areas of reaction occurred. Further studies are needed to determine the optimal dosing frequency and duration of treatment with imiquimod for Bowen's disease.

## CONCLUSION

In summary, NMSC is the most common form of cancer in the Caucasian population and incidence is rising in most countries worldwide. The interest in non-surgical treatment modalities is increasing, and immune response modifiers represent an exciting new approach for treating one of the main types of NMSC, BCC. Studies have shown the clinical efficacy and patient tolerability of imiquimod for the treatment of BCC, and have also demonstrated efficacy for the treatment of AKs. Initial studies suggest that treatment of AK with immune response modifying agents is well tolerated if the appropriate dosing regimen is used. These findings all highlight that the immune response modifier, imiquimod is a promising treatment for BCC and AK.

## REFERENCES

1. Diepgen TL, Mahler V. The epidemiology of skin cancer. *Br J Dermatol* 2002; 146: 1–6.

2. Marks R. Epidemiology of non-melanoma skin cancer and solar keratoses in Australia: a tale of self-immolation in "Elysian fields". *Aus J Dermatol* 1997; 38: 26–29.
3. Preston DS, Stern RS. Nonmelanoma cancers of the skin. *N Engl J Med* 1992; 327: 1649–62.
4. Goldberg LH. Basal cell carcinoma. *Lancet* 1996; 347: 663–667.
5. McCormack CJ, Kelly JW, Dorevitch AP. Differences in age and body site distribution of the histological subtypes of basal cell carcinoma: a possible indicator of differing causes. *Arch Dermatol* 1997; 133: 593–596.
6. Drake LA, Ceilley RI, Cornelison RL, Dobes WA, Dorner W, Goltz RW, et al. Guidelines for the care of basal cell carcinoma. *J Am Acad Dermatol* 1992; 26: 117–120.
7. Cornell RC, Greenway HT, Tucker SB, Edwards L, Ashworth S, Peets EA, et al. Intralesional interferon therapy for basal cell carcinoma. *J Am Acad Dermatol* 1990; 23: 694–700.
8. Marks R, McCarthy WH. Malignant transformation of solar keratoses to squamous cell carcinoma. *Lancet* 1988; I: 296–297.
9. Moy RL. Clinical presentation of actinic keratosis and squamous cell carcinoma. *J Am Acad Dermatol* 2000; 42: 8–10.
10. Marks R, Rennie G, Selwood TS. Malignant transformation of solar keratoses to squamous cell carcinoma. *Lancet* 1988; I: 795–797.
11. Salasche SJ. Epidemiology of actinic keratoses and squamous cell carcinoma. *J Am Acad Dermatol* 2000; 42: S4–S7.
12. Dinehart SM. The treatment of actinic keratoses. *J Am Acad Dermatol* 2000; 42: S25–8.
13. Miller RL, Gerster JF, Owens ML, Slade HB, Tomai MA. Imiquimod applied topically: a novel immune response modifier and new class of drug. *Int J Immunopharmacol* 1999; 21: 1–14.
14. Centers for Disease Control & Prevention (CDC). 2002 Sexually transmitted diseases treatment guidelines. *Morbidity & Mortality weekly report (MMWR)* 2002; 51(RR 6): 53–56.
15. von Krogh G, Lacey CJ, Gross G, Barrasso R, Schneider A. European course on HPV-associated pathology: guidelines for the diagnosis and management of anogenital warts. *Sex Trans Infect* 2000; 76: 162–168.
16. Tatti SA, Belardi G, Marini MA, Eiriz A, Chase LA, Ojeda J, et al. Consenso en la metodologia diagnostica y terapeutica para las verrugas anogenitales. *Rev Obs & Ginecol Latio-Am* 2001; 59: 3–16.
17. Beutner KR, Geisse JR, Helman D, Fox TL, Ginkel A, Owens ML. Therapeutic response of basal cell carcinoma to the immune response modifier imiquimod 5% cream. *J Am Acad Dermatol* 1999; 41: 1002–1007.
18. Marks R, Gebauer K, Shumack S, Amies M, Bryden J, Fox TL, et al. Imiquimod 5% cream in the treatment of superficial basal cell carcinoma: results of a multi-center six-week dose response trial. *J Am Acad Dermatol* 2001; 44: 807–813.
19. Geisse JK, Rich P, Pandya A, Gross K, Andres K, Ginkel A, Owens M. Imiquimod 5% cream for the treatment of superficial basal cell carcinoma: a double-blind, randomized, vehicle-controlled study. *J Am Acad Dermatol* 2002; 47: 390–398.
20. Sterry W, Ruzicka T, Herrera E, Takwale A, Bichel J, Andres K, Ding L. Imiquimod 5% cream for the treatment of superficial and nodular basal cell carcinoma: randomised studies comparing low-frequency dosing with and without occlusion. *Br J Dermatol* 2002; 147: 1227–1236.
21. Shumack S, Robinson J, Kossard S, Golitz L, Greenway H, Schroeter A, et al. Efficacy of topical 5% imiquimod cream for the treatment of nodular basal cell carcinoma. *Arch Dermatol* 2002; 138: 1165–1171.
22. Chen TM, Rosen T, Orengo I. Treatment of a large superficial basal cell carcinoma with 5% imiquimod cream: a case report and review of the literature. *Dermatol Surg* 2002; 28: 344–346.
23. Kagy MK, Amonette R. The use of imiquimod 5% cream for the treatment of superficial basal cell carcinomas in a basal cell nevus syndrome patient. *Dermatol Surg* 2000; 26: 577–579.
24. Stockfleth E, Hauschild A, Lischner S, Christophers E, Meyer T. Successful treatment of basal cell carcinomas in Gorlin-Goltz syndrome with topical 5% imiquimod: a report of three cases. *Eur J Dermatol* 2002; 12: 569–572.
25. Nouri K, Chang A, Trent JT, Jimenez GP. Ultrapulse CO2 used for the successful treatment of basal cell carcinomas found in patients with basal cell nevus syndrome. *Dermatol Surg* 2002; 28: 287–290.
26. Edwards L, Ferenczy A, Eron L, Baker D, Owens ML, Fox TL, et al. Therapeutic response of actinic keratoses to the immune response modifier, imiquimod 5% cream. In: 58th Annual American Academy of Dermatology. San Francisco, USA, March 2000.
27. Stockfleth E, Meyer T, Benninghoff B, Christophers E. Successful treatment of actinic keratosis with imiquimod cream 5%: a report of six cases. *Br J Dermatol* 2001; 144: 1050–1053.
28. Stockfleth E, Ulrich C, Salasche SJ, Christophers E. A randomized, double-blind, vehicle-controlled study to assess imiquimod 5% cream for the treatment of actinic keratosis. *Arch Dermatol* 2002; 138: 1498–1502.
29. Persaud AN, Shamelova E, Lou W, Lebowitz M. Clinical effect of imiquimod 5% cream in the treatment of actinic keratosis. *J Am Acad Dermatol* 2002; 47: 553–556.
30. Salasche SJ, Levine N, Morrison L. Cycle therapy of actinic keratoses of the face and scalp with 5% topical imiquimod cream: an open label trial. *J Am Acad Dermatol* 2002; 47: 571–577.
31. Kossard S, Rosen R. Cutaneous Bowen's Disease. An analysis of 1001 cases according to age, sex and site. *J Am Acad Dermatol* 1992; 27: 406–410.
32. Kovacs A, Yonemoto K, Katsuoka K, Nishiyama S, Harhai I. Bowen's disease: statistical study of a 10 year period. *J Dermatol* 1996; 23: 267–274.
33. Kao GF. Carcinoma arising in Bowen's Disease. *Arch Dermatol* 1986; 122: 1124–1126.
34. Cox NH, Eedy DJ, Morton CA. Guidelines for the management of Bowen's Disease. *Br J Dermatol* 1999; 141: 633–641.
35. Mackenzie-Wood A, Kossard S, de Launey J, Wilkinson B, Owens ML. Imiquimod 5% cream in the treatment of Bowen's disease. *J Am Acad Dermatol* 2001; 44: 462–470.