

Successful Treatment of Azole-resistant Chronic Mucocutaneous Candidosis with Caspofungin

Melany Jayasinghe, Sibylle Schmidt, Birgit Walker, Martin Röcken and Martin Schaller

Department of Dermatology, University of Tübingen, Liebermeisterstrasse 25, DE-72076 Tübingen, Germany.

E-mail: Melany.Jayasinghe@med.uni-tuebingen.de

Accepted July 25, 2006.

Sir,

Candida albicans becomes a pathogen when it multiplies markedly, depending on its virulence and the state of the host's immune system, and converts from the saprophytic to the parasitic variant. Predisposing risk factors for oral candidosis are: severe nutritional deficiencies; diabetes mellitus; autoimmune diseases; leukaemia; and immunodeficiency, especially HIV- or transplant-related immunodeficiency (1). In severely immunosuppressed patients, oral infection can spread to the upper intestinal tract, leading to systemic candidosis with high morbidity and mortality.

Early onset of persistent or recurrent infections of the mucous membranes, skin and nails can be a clinical sign of chronic mucocutaneous candidosis (CMC), which is always associated with immunological defects (2). In some instances a familial occurrence has been reported, suggesting a genetic predisposition. Patients usually have or develop other disorders, including other infectious diseases, enamel dysplasia, alopecia, vitiligo, malabsorption, haemolytic anaemia and autoimmune polyendocrinopathy. These disorders are especially common in patients with autoimmune polyendocrinopathy-candidosis-ectodermal dystrophy (APECED) syndrome with hypoparathyroidism, CMC and adrenal insufficiency as the main symptoms (3).

Topical therapies are not usually effective in CMC patients, while systemic antifungal drugs, such as the azole derivatives can improve quality of life. Effects are often transient and recurrences are inevitable because of the development of resistance (4).

It has been shown that caspofungin exhibits *in vitro* activity even against *Candida* strains resistant to azoles

(5). Caspofungin is well-tolerated and represents a substantial improvement over existing therapeutic options for patients with azole-resistant *Candida* infections.

CASE REPORT

An 18-year-old woman was referred to our clinic because of persistent oral candidosis and onychomycosis that had failed to respond to varying doses of oral fluconazole used intermittently in the past. Intractable oral candidosis developed in childhood and persisted. Onychomycosis occurred later, at the age of 16 years.

The patient's mother also suffered from CMC from 4 months of age and showed a marked spontaneous improvement in symptoms at 20 years of age.

The clinical diagnosis of CMC was made in 1997 because of persistent and recurrent *C. albicans* infections of the skin, nails and oral mucosa. She had no history of immunological or endocrine diseases except an isolated decreased level of parathormone, which was first detected in 2002. Serum calcium and phosphate levels were normal, while no autoantibodies against insulin, thyroid, parathyroid or adrenal gland were found, so hypoparathyroidism could be excluded. APECED syndrome could definitely be excluded by genetic analysis, which did not detect mutations of the *autoimmune regulator* (AIRE) gene.

At the age of 10 years systemic treatment was started with 4 mg/kg fluconazole daily and, after improvement, a prophylactic dosage of 2 mg/kg daily was given. Since 2000, the dosage of fluconazole therapy had been 100 mg daily, with increases to 200 mg daily with worsening problems. In 2002 a fungal culture from an oropharyngeal swab first revealed azole-resistant strains of *C. albicans*; however it did not lead to a change of therapy. When the candidosis involved the finger nails, she received itraconazole for 2 months in 2003 without improvement.

On admission she presented with perioral erythematous erosive lesions (Fig. 1A) and white plaques on the buccal mucosa, palate and tongue. Her finger nails showed brownish discolouration, swelling, dystrophy and periungual erythema (Fig. 2A). Apart from this, she was in good general health. Physical examination and laboratory evaluations including complete blood count, routine blood chemistry, C-reactive protein and immunoglobulin A, M and G did not show any abnormalities. An immune status showed a normal lympho-

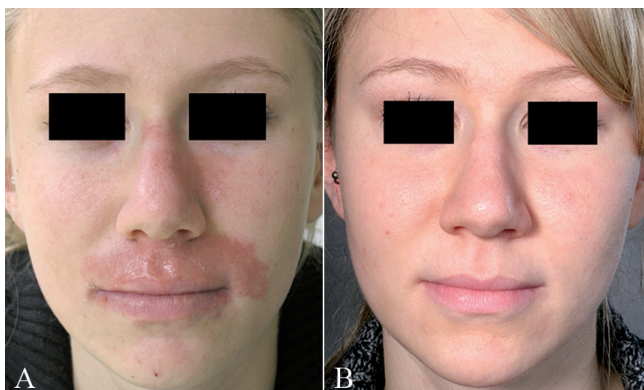


Fig. 1. (A) Perioral/paranasal erythematous and erosive lesions of the face before therapy. (B) Normal appearance of the face during caspofungin therapy.

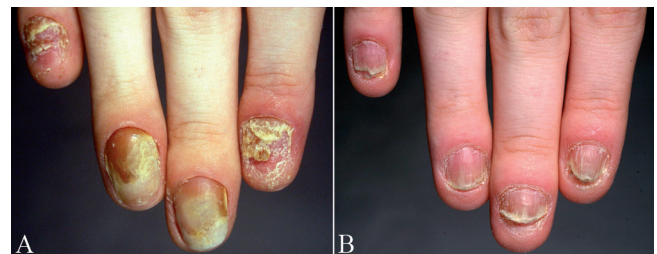

Fig. 2. (A) Finger nails showing brown discolouration, swelling and dystrophy. Periungual erythema. (B) Normal appearance of the distal nail plate after 6 months of caspofungin treatment.

cyte count with regular distribution of B cells (CD 19/CD20), T cells (CD3/CD4/CD8), natural killer cells (CD16/CD56) and a normal CD4/CD8 ratio.

KOH preparations of the skin, mucosa and nail scrapings revealed fungus pseudohyphae, and culture on Sabouraud agar produced fast-growing, smooth, white, dome-shaped colonies. The yeast was identified as *C. albicans* with the API 20 bioMerieux identification system. Microdilution assay and agar diffusion tests were performed to investigate antimycotic susceptibility. The isolated *C. albicans* strain was resistant to fluconazole, itraconazole and voriconazole, but sensitive to nystatin and amphotericin B.

The patient was given a 70 mg loading dose of caspofungin (Cancidas®, MSD Sharp & Dohme GmbH, Haar, Germany) intravenously on the first day of treatment, followed by 50 mg 4–7 times per week for almost 12 months. Treatment was performed by the patient's family doctor near her home. Caspofungin, given initially 7 times per week, resulted in an immediate healing of clinical symptoms. Already after 3 weeks of caspofungin treatment 5–7 times per week the white patches on her buccal mucosa, tongue and palate and the perioral erosive erythematous lesions had almost disappeared (Fig. 1B) while onychomycosis improved slowly (Fig. 2B). After 3 more weeks the number of infusions was reduced to 3 times per week. However, this reduction led to a relapse of clinical symptoms. With caspofungin therapy 4–5 times per week good skin condition could be achieved in our patient over almost 12 months of therapy. We conclude that long-term therapy might be necessary to control the disease. At present we are testing the susceptibility of the patient's strains to the new azole posaconazole, which might be a cheaper oral treatment option.

During therapy routine blood chemistry was normal except for a temporary elevation of hepatic enzyme levels, which did not necessitate discontinuation of therapy.

DISCUSSION

APECED, also called APS-1, is a rare autosomal recessive disorder that is associated with mutations of the AIRE gene (6) and predominantly affects juvenile patients with a family background from Sardinia, Finland (3) and Iranian Jews.

Our patient had no mutations in the AIRE gene so the presumptive diagnosis of APECED could not be confirmed. Because both the mother and daughter had CMC, an autosomal dominant inheritance might still be considered.

Recent studies suggested that the immune defects in patients with CMC could be the result of altering patterns of cytokine production, resulting in inadequate interleukin-2 and interferon-gamma production in response to *Candida* infections (7). Furthermore, association between natural killer cells (8) and humoral deficiency (9) with CMC have been described.

Our patient had only oral mucosa, nail and skin infection with *C. albicans* without any other accompanying endocrine or immune disorder. It is important to bear in mind that the endocrinopathies may develop at any time from childhood through adulthood and that patients may have sequential loss of function of various endocrine organs.

Our patient experienced clinical improvement of her oral and cutaneous candidosis after treatment with caspofungin. The treatment was well-tolerated and no drug-related toxicity was noticed.

Caspofungin belongs to the echinocandins, a novel class of parenterally administered antifungal agents that have a different mode of action from that of azoles and polyenes. Echinocandins inhibit β -D-1, 3-glucan synthesis in the fungal cell wall, while other agents act on ergosterol (10). As β -D-1, 3-glucans are not present in mammalian cells, and echinocandins such as caspofungin do not interact with the cytochrome p450 isoenzyme system, they have low potential for toxic side-effects and drug interactions.

As treatment with caspofungin is very expensive, it should be reserved for patients who do not respond to standard therapy.

ACKNOWLEDGEMENTS

The authors thank Professor Walter Burgdorf (Department of Dermatology and Allergology, University of Munich) for critical reading of the manuscript.

REFERENCES

1. Akpan A, Morgan R. Oral candidiasis. *Postgrad Med J* 2002; 78: 455–459.
2. Kirkpatrick DH. Chronic mucocutaneous candidiasis. *Pediatr Infect Dis J* 2001; 20: 197–206.
3. Ahonen P, Myllarniemi S, Sipila I, Perheentupa J. Clinical variation of autoimmune polyendocrinopathy-candidiasis-ectodermal dystrophy (APECED) in a series of 68 patients. *N Engl J Med* 1990; 28: 1829–1836.
4. Redding SJ, Smith J, Farinacci G, Rinaldi M, Fothergill A, Rhine-Chalberg J, et al. Resistance of *Candida albicans* to fluconazole during treatment of oropharyngeal candidiasis in a patient with AIDS: documentation by in vitro susceptibility testing and DNA subtype analysis. *Clin Infect Dis* 1994; 18: 240–247.
5. Martinez-Suarez JV, Rodriguez-Tudel JL. In vitro activities of semisynthetic pneumocandin L-733,560 against fluconazole-resistant and -susceptible *Candida albicans* isolates. *Antimicrob Agents Chemother* 1996; 40: 1277–1279.
6. Finnish-German APECED Consortium. An autoimmune disease, APECED, caused by mutations in a novel gene featuring two PHD-type zinc-finger domains. *Autoimmune Polyendocrinopathy-Candidiasis-Ectodermal Dystrophy*. *Nat Genet* 1997; 17: 399–403.
7. De Moraes-Vasconcelos D, Orii NM, Romano CC, Iqueoka RY, Duarte AJ. Characterization of the cellular immune function of patients with chronic mucocutaneous candidiasis. *Clin Exp Immunol* 2001; 123: 247–253.
8. Palma-Carlos AG, Palma-Carlos ML. Chronic mucocutaneous candidiasis revisited. *Allergy Immunol* 2001; 33: 229–232.
9. Gill FF, Portnoy JM. An unusual combination of immunologic abnormalities in a patient with chronic mucocutaneous candidiasis. *Ann Allergy* 1989; 63: 98–148.
10. Denning DW. Echinocandins: a new class of antifungal. *J Antimicrob Chemother* 2002; 49: 889–891.