

Epidermolysis Bullosa Pruriginosa due to a Glycine Substitution Mutation in the *COL7A1*-gene

Sigrid M.C. Broekaert¹, Evelin Knauss-Scherwitz¹, Tilo Biedermann¹, Gisela Metzler¹, Cristina Has², Jürgen Kohlhas³, Martin Röcken¹ and Martin Schaller¹

¹Department of Dermatology, University of Tübingen, Liebermeisterstrasse 25, D-72076 Tübingen, ²Department of Dermatology, and ³Institute for Human Genetics and Anthropology, University of Freiburg, Freiburg, Germany. E-mail: Sigrid.Broekaert@med.uni-tuebingen.de

Accepted June 8, 2006.

Sir,

Dystrophic epidermolysis bullosa (DEB) is a clinically heterogeneous genodermatosis with characteristic trauma-induced blistering associated with scarring and nail dystrophy. It results from mutations in *COL7A1*, the gene encoding type VII collagen. The site and specific nature of the underlying mutation determine the clinical phenotype, which ranges widely from a generalized severe mutilating condition to a relatively mild localized disorder (1). DEB pruriginosa is a distinct clinical subtype of DEB, characterized by prurigo-like or lichenified lesions associated with scarring (2). Scarring is most evident on the limbs, particularly on the shins, with relative sparing of other body areas (2). Disease onset may occur in early childhood, but in some individuals it is delayed until the second or third decade of life (3). Autosomal dominant, autosomal recessive, and sporadic inheritance patterns have been described (2). Due to its possible late onset and its striking similarity to other dermatoses, such as hypertrophic lichen planus, lichen simplex chronicus and cutaneous amyloidosis, this subtype presents a considerable clinical challenge.

CASE REPORT

A 29-year-old Turkish woman presented to our clinic with a 2-year history of pruritic papules on the extensor sides of her feet and lower extremities and similar manifestations on her elbows. Apart from these clinical signs and symptoms and mild nail dystrophy she was in good general health, with no problems with swallowing, bowel functions, nutrition, eyes or teeth. There was no family history of similar skin or nail diseases. There was neither personal history of eczema or atopy nor evidence for other causes of itching, such as internal diseases. Clinical examination revealed multiple lichenified violaceous papules, linear scarring and crusts on the dorsal side of her feet, ankles and distal lower extremities (Fig. 1). On closer inspection, milia were visible between the papules. Her elbows showed similar lesions that were in addition excoriated. Her toe nails showed mild dystrophy, while her mucous membranes were normal. Treatment with unknown topical corticosteroids for several weeks failed to provide relief.

A biopsy from a lichenoid papule showed orthohyperkeratosis, acanthosis and multiple subepidermal splits and no typical criteria for lichen planus. Bullous autoimmune dermatoses, such as epidermolysis bullosa acquisita and pemphigoid were excluded by negative direct and indirect immunofluorescence. Immunohistochemical staining with antibodies against type IV collagen labelled the blister roof. This finding corresponds to blister formation below the lamina densa. Electron microscopy (EM) revealed areas of few or even absent anchoring fibrils (Fig. 2a and b). Confocal laser microscopy supported the diagnosis by verifying the absence or reduction of collagen VII, a main

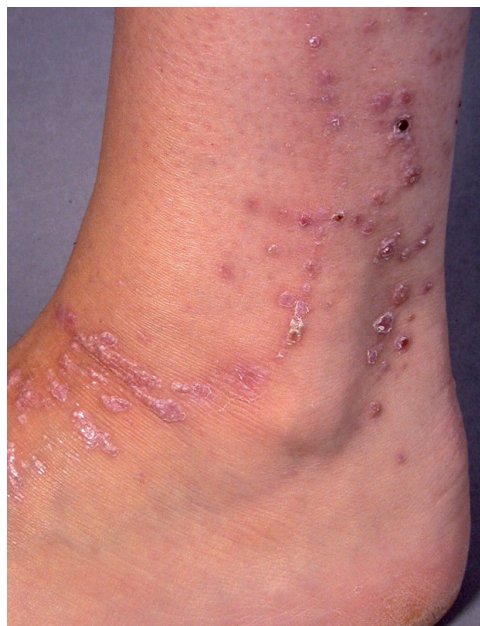

Fig. 1. Multiple livid lichenified papules, linear scarring, crusts and milia on the dorsal side of the patient's feet, ankles and distal lower extremities.

component of the anchoring fibrils (Fig. 2c and d). Mutation analysis of the *COL7A1*-gene (chromosome 3p21.3) was performed. In the patient's DNA sample, in exon 110 of *COL7A1*, the heterozygous mutation c.8137G >C was disclosed. This base substitution leads to a previously reported missense mutation, consisting of an amino acid conversion from glycine to arginine residue at position 2713, designated p.G2713R. This mutation was not present in the DNA of the patient's son.

Based on these findings we diagnosed DEB pruriginosa. We recommended occlusive tacrolimus therapy, that the patient withdrew from treatment after understanding the genetic origin of her disease.

DISCUSSION

In our patient the diagnosis of DEB pruriginosa was based on both clinical findings and analysis of biopsy specimens by immunofluorescence mapping and EM, confirmed by mutation analysis. Confocal laser microscopy showed abnormal collagen VII staining, which supports the diagnosis of DEB. We employed this technique to demonstrate that, in addition to mutation analysis and immunofluorescence antigenic mapping, it is a useful alternative when EM is not available. This rare localized subtype of DEB was first published by McGrath et al. (2). Clinical features are not usually

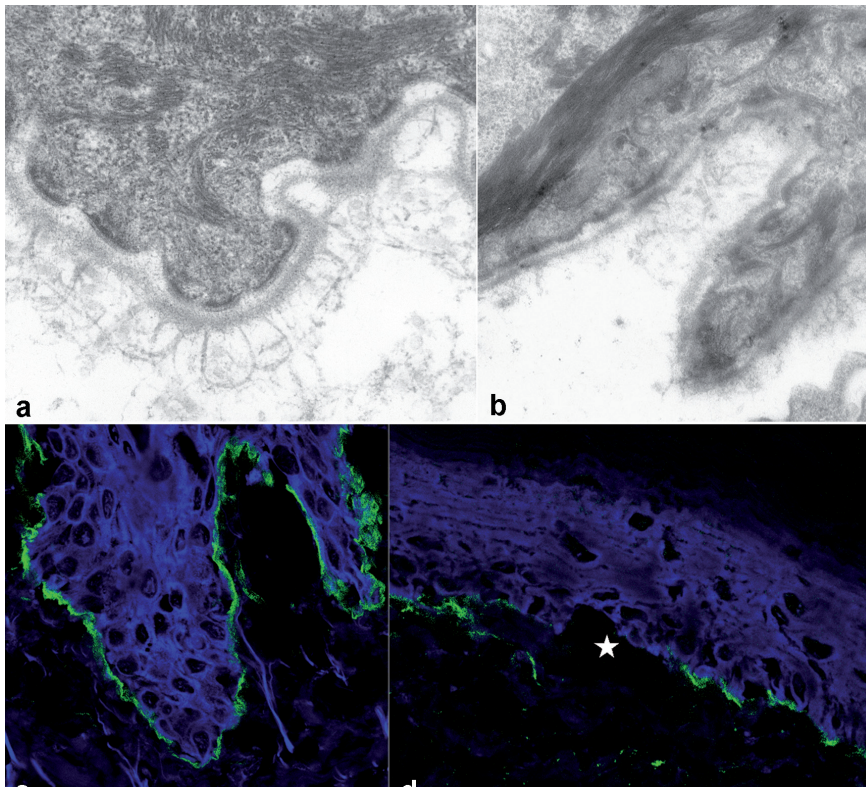


Fig. 2. Microscopic analysis of healthy skin in comparison with affected skin of our patient with reduced or absent collagen VII. (a) Healthy skin with loop-like anchoring fibrils, mainly consisting of collagen VII, originate from the lamina densa, as seen by electron microscopical analysis compared with (b) areas of few or even absent anchoring fibrils in the skin of our patient. In confocal laser microscopic analysis (c) healthy skin shows normal staining with anti-type VII collagen (green) compared with (d) reduced green labelling of collagen VII at the blister (blister cavity is indicated by a star) in the skin of our patient.

present at birth. Typically, as in our patient, disease onset can be delayed until the second or third decade, making clinical diagnosis difficult, especially in cases such as this, with no family history. Clinical findings include lichen planus- or prurigo-like nodules with pruritus as the most prominent and severe symptom. Nail dystrophy is described in the majority of patients, but is not obligatory for diagnosis. Various mutations in the *COL7A1*-gene have been reported, almost always implicating glycine substitutions in the collagenous triple helical domain of type VII collagen causing disruption of anchoring fibril assembly (3–5). Autosomal dominant, autosomal recessive and sporadic inheritance patterns have been described in this disease (1). In our patient, the heterozygous mutation c.8137G > C, leading to the glycine substitution p.G2713R could be detected. This mutation has been described before in a female patient with dominant DEB pruriginosa aged 29 years at disease onset (3). Interestingly, she inherited the mutation from her father, who had only mild toe nail dystrophy, while a nephew had localized trauma-induced blistering with scarring on his knees (3).

Treatment is very disappointing and mostly symptomatic. However, successful results have been achieved with topical tacrolimus and thalidomide as well as cyclosporine (6–8). Since we were concerned about the peripheral neuropathy associated with thalidomide, we recommended our patient to apply tacrolimus under occlusion overnight to the affected areas but she did not consent to this treatment.

ACKNOWLEDGEMENTS

The authors thank Hannelore Bischof, Birgit Fehrenbacher, Helga Möller and Renate Nordin (Department of Dermatology, University of Tübingen, Germany) for excellent technical assistance, and Professor Dr W. Burgdorf (Department of Dermatology and Allergology, University of Munich) for critical reading of the manuscript.

REFERENCES

- Horn HM, Tidman MJ. The clinical spectrum of dystrophic epidermolysis bullosa. *Br J Dermatol* 2002; 146: 267–274.
- McGrath JA, Schofield OMT, Eady RAJ. Epidermolysis bullosa pruriginosa: dystrophic epidermolysis bullosa with distinctive clinicopathological features. *Br J Dermatol* 1994; 130: 617–625.
- Mellerio JE, Ashton GHS, Mohammadi R, Lyon CC, Kirby B, Harman KE, et al. Allelic heterogeneity of dominant and recessive *COL7A1* mutations underlying epidermolysis bullosa pruriginosa. *J Invest Dermatol* 1999; 112: 984–987.
- Mellerio JE. Molecular pathology of the cutaneous basement membrane zone. *Exp Dermatol* 1999; 24: 25–32.
- Terracina M, Posteraro P, Schubert M, Sonego G, Atzori F, Zambruno G, et al. Compound heterozygosity for a recessive glycine substitution and a splice site mutation in the *COL7A1* gene causes an unusually mild form of localized recessive dystrophic epidermolysis bullosa. *J Invest Dermatol* 1998; 111: 744–750.
- Banky JP, Sheridan AT, Storer EL, Marshman G. Successful treatment of epidermolysis bullosa pruriginosa with topical tacrolimus. *Arch Dermatol* 2004; 140: 794–796.
- Ozanic Bulic S, Mellerio JE, McGrath JA, Atherton DJ. Thalidomide in the management of epidermolysis bullosa pruriginosa. *Br J Dermatol* 2005; 152: 1332–1334.
- Yamasaki H, Tada J, Yoshioka T, Arata J. Epidermolysis bullosa pruriginosa (McGrath) successfully controlled by oral cyclosporin. *Br J Dermatol* 1997; 137: 308–310.