

## CLINICAL REPORT

# Pulse Methylprednisolone Therapy for Threatening Periocular Haemangiomas of Infancy

Franck DELESALLE<sup>1</sup>, Delphine STAUMONT<sup>1</sup>, Mohamed Ali HOUMANY<sup>2</sup>, Georges Marie BREVIERE<sup>2</sup> and Frederic PIETTE<sup>1</sup>

<sup>1</sup>Clinique de Dermatologie, Hôpital Claude Huriez, and <sup>2</sup>Service des Maladies Cardiovasculaires Infantiles et Congénitales, Hôpital Cardiologique, Lille, France

**Periocular haemangiomas of infancy can cause severe and rapid ocular damage. Oral corticosteroids remain the front-line treatment to minimize the consequences of these haemangiomas. The aim of this report is to summarize our experience with pulse intravenous methylprednisolone as an alternative therapy for periocular haemangioma when visual prognosis is engaged. Fifteen infants, who presented periocular haemangioma with functional impact on vision, received 2 mg/kg methylprednisolone intravenously twice a day for 2 days. Following pulse therapy, 2 mg/kg/day prednisolone was given orally with gradual tapering. No further visual impact was noticed following pulse therapy. Two patients relapsed, needing new pulses or, in one case, vincristine. No serious side-effects were recorded. Pulse methylprednisolone therapy permitted a particularly rapid shrinkage of haemangiomas and a complete disappearance of their visual impact within 2 days. Apparently more rapid than the usual oral corticosteroids, pulse intravenous methylprednisolone decreases the risk of ocular complications, which correlates with the duration of the influence of haemangiomas. Key words: eyelid haemangioma; orbital haemangioma; corticosteroids.**

(Accepted April 20, 2006.)

Acta Derm Venereol 2006; 86: 429–432.

Franck Delesalle, Clinique de Dermatologie, Hôpital Claude Huriez, 1 rue Polonowski, FR-59037 Lille Cedex, France. E-mail: franckdelesalle@hotmail.com

Infantile haemangiomas are very common benign tumours of infancy. Most haemangiomas appear at birth or by one month of age, and subsequently enlarge, reaching their final size by 6–12 months of age. Spontaneous regression is observed within the first 5 years of life, so that no treatment is required unless these haemangiomas interfere with functional activities or is life threatening. Periocular haemangiomas are particularly dangerous because they can result in various and severe visual damage (1, 2). In this alarming situation, adequate treatment must be given to protect infants from irreversible damage. Oral corticosteroids remain the most common treatment. Four years ago we observed a newborn baby with a large hepatic haemangioma that quickly resulted in asystolia.

Since no oral steroids could be administered, intravenous methylprednisolone was given instead. The decrease in volume of this haemangioma was particularly marked and extremely fast compared with what was usually observed with oral corticosteroids (F. Delesalle et al., unpublished observation). In light of this experience, the question of efficacy of intravenous pulses of methylprednisolone for other threatening haemangiomas was raised. The purpose of this report is to discuss the efficacy of intravenous pulse methylprednisolone when visual prognosis is engaged. This paper reviews the management and outcome of 15 threatening periocular haemangiomas.

## MATERIALS AND METHODS

Diagnosis of 15 cases of haemangioma of infancy was made by history and physical examination (Table I). No systematic ultrasonography, tomodensitometry or biopsy was carried out. All of these haemangiomas concerned the orbital region or eyelids with a functional impact on vision, confirmed by an ophthalmological examination. Cases 1–7 also induced a complete eye closure. Cases 1, 2, 6, 7, 8, 12 and 14 presented particularly large haemangiomas, involving not only the periocular region, but also the frontal, temporal or nasal areas. Case 15 presented an infantile haemangioma of the right orbit, which induced exophthalmia. The volume and impact of this haemangioma on the eye components was evaluated by a computed tomography (CT) scan of the orbit.

Cases 8, 10 and 12 were first treated with oral corticosteroids, but the efficacy of this treatment was insufficient. In cases 8 and 12, oral prednisolone not only failed to decrease the volume of the haemangiomas but also failed to stop their growth. In case 10, oral corticosteroids were initially successful since they stopped the growth of the haemangioma and decreased its size. The interruption of oral prednisolone for 15 days unfortunately resulted in a dramatic expansion of the volume of the haemangioma, endangering the visual prognosis.

The average age when pulse intravenous corticosteroids were commenced was 2.5 months. Patients were hospitalized for 2 days for monitoring while they received intravenous corticosteroids. Methylprednisolone, 2 mg/kg, was injected during a period of 30 minutes, twice a day for 2 days (methylprednisolone was diluted in an infusion of 50 ml isotonic glucose 5%). The patients were monitored at regular intervals for blood pressure, pulse and consciousness. Metabolic disorders were checked through daily blood analysis (glucose, electrolytes, renal function).

Efficacy of pulse intravenous methylprednisolone was determined on the third day through the measurement of the size of the haemangioma, clinical evaluation of eye opening, and ophthalmological analysis of visual impact.

Following the methylprednisolone pulses, 2 mg/kg/day of prednisolone or equivalents was administered orally. Gradual

Table I. Clinical characteristic and treatment results in 15 cases of periocular haemangioma of infancy

Case/age (months)	Localization of haemangioma	Eye impact	Initial treatment	Efficacy after 2 days of i.v. pulse methylprednisolone	Total length of oral P (months)
1/2	Left half face and upper eyelid	Complete closing	None	Eye opening. No further visual impact	6
2/1	Left frontal zone and right upper eyelid	Complete closing	None	Eye opening. No further visual impact	4
3/2	Right lower eyelid	Complete closing	None	Eye opening. No further visual impact	3
4/3	Right upper eyelid	Complete closing	None	Eye opening after the first pulses. No further visual impact	7.5
5/1.5	Left upper eyelid	Complete closing	None	Eye opening after the first pulses. No further visual impact	?
6/1	Temporal and left lower eyelid	Complete closing	None	Eye opening after the first pulses. No further visual impact	12
7/3	Right frontal zone and upper eyelid	Complete closing	None	Eye opening. No further visual impact.	3
8/2	Frontal, sternal, right internal canthus	Visual impact. Superficial necrosis	7 days P	Volume decrease. No further visual impact	8
9/1.5	Left upper eyelid	Visual impact	None	Volume decrease. No further visual impact	6
10/4	Right lower eyelid	Visual impact	1 mo. P	Volume decrease. No further visual impact	6
11/5	Right external canthus	Visual impact	None	Volume decrease. No further visual impact	3
12/4.5	Nasal and right upper eyelid	Visual impact	15 days P	Volume decrease. No further visual impact	6
13/3	Left upper eyelid	Visual impact	None	Volume decrease. No further visual impact	2.5
14/2	Lower and upper eyelid and temporal area	Visual impact	None	Volume decrease. No further visual impact	6.5
15/1.5	Right orbit	Proptosis	None	Volume decrease. No further proptosis	3

P: prednisolone orally 2 mg/kg/day.

tapering of oral corticosteroids was initiated one month after stability or when involution of the haemangiomas was obtained. Tapering was specific to each haemangioma, ranging from 15% to 30% of dosage, every 1 or 2 weeks. When relapse was noticed while tapering, the dosage was increased to the previous dosage. A 15-day course was then re-initiated until stabilization or involution. If relapse under oral corticosteroid was dramatic, threatening visual prognosis once again, new intravenous methylprednisolone pulses were performed. Follow-up was made regularly by physical examination, with blood pressure, weight and height measurement. Gastric stress was evaluated through interviewing the mother and asking about feeding difficulties. Anti-acids were then given. If blood pressure was abnormal, chest X-ray and cardiac ultrasound were performed, to detect any cardiomyopathy.

## RESULTS

Responses to intravenous methylprednisolone pulses were considered to be good or even excellent every time. The decrease in the volume of the haemangiomas was obvious as early as the first day. The complete opening of the eye was obtained rapidly, as early as the first day of intravenous corticosteroids for cases 1, 4, 5 and 6, and on the third day for cases 2, 3 and 7. Ophthalmologists did not find any visual impact after pulse therapy in any of the patients (Fig. 1).

Case 8 and 12, who first received oral prednisolone without sufficient efficacy, responded as well as the others to intravenous methylprednisolone, with complete recovery of the visual field.

Concerning case 15, exophthalmia caused by the orbital haemangioma also decreased quickly within 2 days. This improvement was confirmed by a new CT scan of the orbit performed 2 weeks later.

Nevertheless, for cases 5 and 6, a single pulse therapy was insufficient. Case 5 was able to open his

eye after the first methylprednisolone pulses. Despite a 2 mg/kg/day oral prednisolone treatment, he relapsed one week later, with complete obstruction of the eye. He thus received intravenous methylprednisolone pulses following the same protocol. The second treatment was successful and no relapse was registered later.

The response to treatment of case 6 was considered good, since visual function was no longer threatened. However, growth of this huge haemangioma continued to be observed on several occasions despite oral prednisolone; 4 additional intravenous methylprednisolone pulses were administered in case of total obstruction of visual field. At 2.5 months of age, pulse methylprednisolone therapy permitted a mild but incomplete improvement with a persistent visual impact. Then, in addition to oral prednisolone (1.5 mg/kg/day), vincristine (1 mg/m<sup>2</sup> per injection, once a week) was also administered for 6 weeks with quite good results (no further visual impact). At 5 and 6 months of age, pulse methylprednisolone therapy was sufficient to recover normal visual field. At 9 months of age, a new severe relapse occurred. Once again, pulse methylprednisolone therapy was unable to completely decrease the volume of the haemangioma. A single injection of vincristine (1 mg/m<sup>2</sup>) combined with oral prednisolone (1 mg/kg/day) was successful. Oral prednisolone was then administered until 13 months of age with gradual tapering.

No serious side-effects were observed in hospital. Sleep disturbance was frequent, concerning nearly all the infants.

The average duration of oral corticosteroids following intravenous methylprednisolone pulses was 5.65 months. The main side-effects were reversible growth and weight stagnation, concerning children 6 and 9. Half of the infants had symptoms of gastric stress.

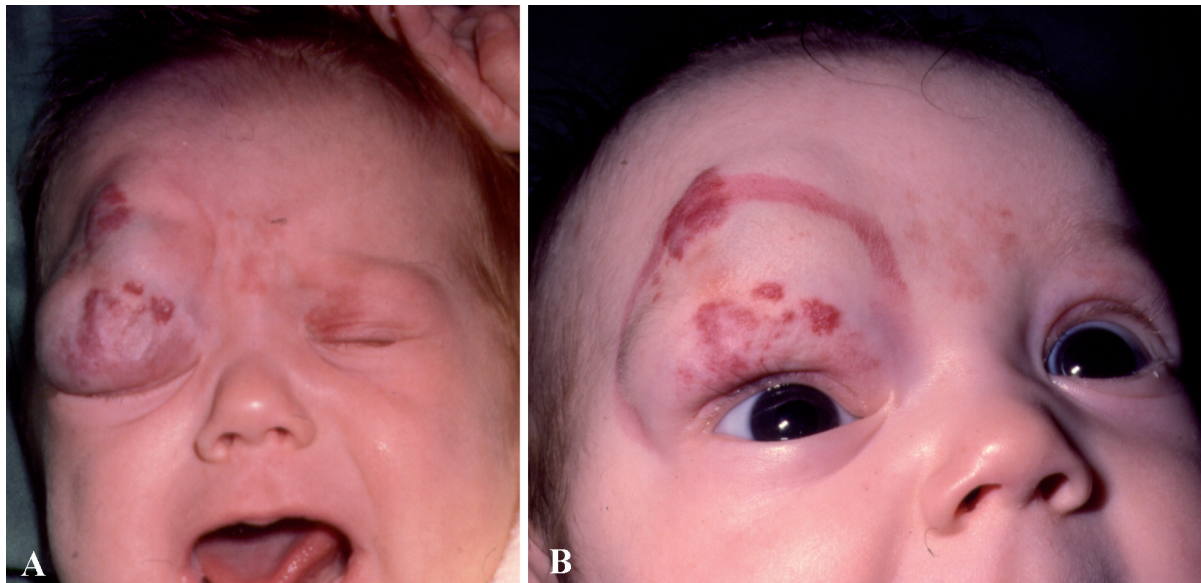


Fig. 1. (A) A 3-month-old infant (case 7) presenting with a frontal and right upper eyelid haemangioma. The eye was completely closed. Pulse intravenous methylprednisolone (2 mg/kg twice a day for 2 days) was chosen to treat this haemangioma. (B) Three days later, the volume of the haemangioma was dramatically lower. The infant could open his right eye again. No further visual impact was noticed by ophthalmologists.

Fussiness, irritability and insomnia were also reported. Neither hypertension nor cardiomyopathy was noted. No child suffered from adrenal suppression at the end of the treatment.

## DISCUSSION

Periocular haemangiomas represent a considerable risk to vision through occlusion of the pupil, compression of the globe, and expansion in the retrobulbar space. Ocular complications occur in 80% of patients. These include amblyopia, strabismus, astigmatism, refractive errors and optic nerve atrophy (1, 2). Amblyopia is reported in up to 60% of patients and is a major cause of loss of visual acuity in the affected eye (2). Severe amblyopia has been closely correlated with the duration of eyelid closure and stimulus deprivation (2). Such amblyopia can develop within one week (3). Astigmatism and refractive errors result from bulky lesions and are a frequent cause of mild to average amblyopia. Therefore, haemangiomas that obstruct the visual axis or exert pressure on the globe should be treated immediately in order to preserve binocular vision.

Gold standard treatment for alarming infantile haemangiomas is usually oral corticosteroids (4–6). The meta-analysis by Benett et al. (5) clearly showed that most infants with growing cutaneous haemangiomas respond to systemic corticosteroid administration. The initial dosing of corticosteroids probably arose from existing treatment regimens for conditions such as nephrotic syndrome and asthma in infants, ranging from 1 to 5 mg/kg/day of prednisone. An average daily dose of 2.9 mg/kg of prednisone given over an average time of 1.8 months before tapering

had a response rate of 84%. More than 3 mg/kg/day resulted in a 94% response, but greater side-effects were observed. Sadan & Wolach (6) reported their results in 20 cases of infantile haemangiomas treated with high doses of oral prednisone (3 or 5 mg/kg/day). A decrease in haemangioma volume was observed within 24 hours and improvement in vision occurred within 1–2 weeks.

Intravenous methylprednisolone pulses (2 mg/kg twice a day), on the other hand, resulted not only in the shrinkage of haemangiomas, but also in the complete resolution of visual impact induced within 2 days. As ocular damage is correlated with duration of the impact of the haemangiomas (2), time is very precious. Therefore, rapidity of action is a major advantage of intravenous pulse methylprednisolone therapy.

We did not find a corticosteroid-sparing effect of intravenous pulse methylprednisolone therapy in haemangioma therapy as reported for other dermatological diseases (7). In our study, the average duration of oral corticoid treatments (5.65 months) following pulses was similar to that observed by Enjolras et al. (4) for alarming haemangiomas (5.3 months). Sadan & Wolach (6) administered high doses of prednisone orally (3–5 mg/kg/day with gradual tapering) for only 6–12 weeks. In addition to the fact that fewer relapses were recorded in our study, the oral prednisolone doses (2 mg/kg/day) we used after methylprednisolone pulses were dramatically lower. We assume that higher doses of prednisolone would result in more serious side-effects. In our experiment, we recorded mainly reversible growth or weight stagnation. Neither hypertension nor cardiomyopathy was noted. Transient decreased growth of case 6 was certainly encouraged by the particularly long intake of oral corticosteroids (8–11).

The main paediatric dermatological indication for intravenous pulse of corticosteroid is alopecia areata. In one study (12) 5 mg/kg twice a day was administered for 3 days to children ranging from 4 to 15 years of age. No serious side-effects were reported in this particular indication. When used in other paediatric immunological diseases, the side-effects were mild, even if the dosages were far higher (13–16). In the light of this data, corticosteroid pulses for haemangiomas appear quite safe, but careful monitoring must be performed.

Alas, some infantile haemangiomas remain out of control despite systemic corticosteroids administration. Surgery could be performed for such haemangiomas (17, 18), but this requires experienced surgeons. There have been some interesting results following the use of an ultrasound dissector, which provides easy dissection, easy haemostasis and leaves only tiny scars (19). For case 6, the haemangioma was so huge that surgery could not be performed. Therefore, vincristine was used twice and this decreased the volume of this threatening haemangioma significantly, without any side-effects. From this result and the literature (20, 21), we can assume that vincristine may be considered as a major treatment of function or life-threatening haemangiomas when corticosteroids are inefficient. Safer than interferon, vincristine needs, however, 3 weeks for its effect, thus complications of haemangiomas could occur during this time.

In conclusion, corticosteroids remain the front-line treatment for functional and life-threatening haemangiomas. Our experience has shown that intravenous pulses of methylprednisolone (2 mg/kg twice a day for 2 days) represent a rapid and effective treatment of alarming periocular haemangiomas, and therefore improve visual prognosis. Moreover, intravenous pulse methylprednisolone therapy can also be effective when oral corticosteroids are insufficient.

## REFERENCES

1. Thomson HG, Ward CM, Crawford JS, Stigmar G. Hemangiomas of the eyelid: visual complications and prophylactic concepts. *Plast Reconstr Surg* 1979; 63: 641–647.
2. Goldberg NS, Rosanova MA. Periorbital hemangiomas. *Dermatol Clin* 1979; 10: 653–661.
3. Milot J, Saurel P. Hémangiome périoculaire de l'enfant. *Chir Pédiatr* 1989; 30: 43–46.
4. Enjolras O, Riche MC, Merland JJ, Escande JP. Management of alarming hemangiomas in infancy: a review of 25 cases. *Pediatrics* 1990; 85: 491–498.
5. Bennett M, Fleischer A, Chamlin S, Frieden I. Oral corticosteroid use is effective for cutaneous hemangiomas. *Arch Dermatol* 2001; 137: 1208–1213.
6. Sadan N, Wolach B. Treatment of hemangiomas of infants with high doses of prednisone. *J Pediatr* 1996; 128: 141–146.
7. Sami N, Qureshi A, Ruocco E, Ahmed AR. Corticosteroid-sparing effect of intravenous immunoglobulin therapy in patients with pemphigus vulgaris. *Arch Dermatol* 2002; 138: 1158–1162.
8. Boon LM, MacDonald DM, Mulliken JB. Complications of systemic corticosteroid therapy for problematic hemangioma. *Plast Reconstr Surg* 1999; 104: 1616–1623.
9. Thedenat B, Leaute-Labreze C, Boralevi F, Roul S, Labbe L, Marliere V, Taieb A. Surveillance tensionnelle des nourrissons traités par corticothérapie générale pour un hémangiome. *Ann Dermatol Venereol* 2002; 129: 183–185.
10. Some Nina K, Lorette G, Chantepie A, Villerette C, Machel L. Cardiomyopathie hypertrophique compliquant une corticothérapie orale pour hémangiome palpébrale. *Ann Dermatol Venereol* 2004; 131: 263–265.
11. George ME, Sharma V, Jacobson J, Simon S, Nopper AJ. Adverse effects of systemic glucocorticosteroid therapy in infants with hemangiomas. *Arch Dermatol* 2004; 140: 963–969.
12. Kiesch N, Stene JJ, Goens J, Vanhooetghem O, Song M. Pulse steroid therapy for children's severe alopecia areata? *Dermatology* 1997; 194: 395–397.
13. Miller JJ 3rd. Prolonged use of large intravenous steroid pulses in the rheumatic diseases of children. *Pediatrics* 1980; 65: 989–994.
14. Adebajo AO, Hall MA. The use of intravenous pulsed methylprednisolone in the treatment of systemic-onset juvenile chronic arthritis. *Br J Rheumatol* 1998; 37: 1240–1242.
15. Barron KS, Person DA, Brewer EJ Jr, Beale MG, Robson AM. Pulse methylprednisolone therapy in diffuse proliferative lupus nephritis. *J Pediatr* 1982; 101: 137–141.
16. Niaudet P, Habib R. Methylprednisolone pulse therapy in the treatment of severe forms of Schonlein-Henoch purpura nephritis. *Pediatr Nephrol* 1998; 12: 238–243.
17. Walker RS, Custer PL, Nerad JA. Surgical excision of periorbital capillary hemangiomas. *Ophthalmology* 1994; 101: 1333–1340.
18. Plager DA, Snyder SK. Resolution of astigmatism after surgical resection of capillary hemangiomas in infants. *Ophthalmology* 1997; 104: 1102–1106.
19. Picard A, Soupre V, Diner PA, Buis J, Goga D, Vazquez MP. Chirurgie précoce des hémangiomes immatures à l'aide d'un dissecteur à ultrasons. Etude à propos de 81 cas. *Rev Stomatol Chir Maxillofac* 2002; 103: 10–21.
20. Perez Payarols J, Pardo Masferrer J, Gomez Bellvert C. Treatment of life-threatening infantile hemangiomas with vincristine. *N Engl J Med* 1999; 333: 69.
21. Enjolras O, Breviere GM, Roger G, Tovi M, Pellegrino B, Varotti E, et al. Traitement par vincristine des hémangiomes graves du nourrisson. *Arch Pédiatr*. 2004; 11: 99–107.