

CLINICAL REPORT

Penicillin-induced Anti-p200 Pemphigoid: An Unusual Morphology

Katarzyna WOZNIAK¹, Cezary KOWALEWSKI¹, Takashi HASHIMOTO², Norito ISHII², Maria GLINSKA-WIELOCHOWSKA¹ and Robert A. SCHWARTZ³

¹Department of Dermatology, Medical University of Warsaw, Warszawa, Poland, ²Department of Dermatology, Kurume University School of Medicine, Kurume, Japan, and ³Department of Dermatology, New Jersey Medical School, Newark NJ, USA

We report here a case of a 52-year-old woman with erythema gyratum repens-like lesions appearing during anti-p200 pemphigoid, probably induced by oral penicillin. The diagnosis of anti-p200 pemphigoid was made by the presence of *in vivo* bound and circulating IgG anti-basement membrane zone auto-antibody reactive with the dermal side of salt-split skin and with 200 kDa protein in dermal extract on Western immunoblot. Laser scanning confocal microscopic study disclosed the localization of IgG at the lamina lucida-lamina densa border. Skin lesions responded poorly to high dose of prednisone and the combination of prednisone and dapsone. When methotrexate was added, skin lesions healed within 3 weeks. To our knowledge, erythema gyratum repens-like lesions have not been described previously in this disorder. Thus, we have expanded the clinical morphological spectrum of patients with anti-p200 pemphigoid and first described a patient whose disorder was probably drug-induced. Key words: pemphigoid; anti-p200 pemphigoid; erythema multiforme bullosum; erythema gyratum repens; laser scanning confocal microscopy.

(Accepted April 4, 2006.)

Acta Derm Venereol 2006; 86: 443–446.

Katarzyna Wozniak, MD, Department of Dermatology, Medical University of Warsaw, PL-02008 Warszawa, Poland. E-mail: kwoznia@amwaw.edu.pl

In 1996, Zillikens et al. (1) described a novel, autoimmune subepidermal bullous disease: anti-p200 pemphigoid. It is clinically characterized by the presence of bullous eruptions resembling erythema multiforme, bullous pemphigoid (BP), dermatitis herpetiformis, or the inflammatory type of epidermolysis bullosa acquisita (2–4).

Histology shows subepidermal blister and inflammatory infiltrations in the dermis, consisting mostly of neutrophils (1, 3). Immunopathologically, it is defined by anti-basement membrane zone antibodies directed against the dermal side of salt-split skin and reacted with 200 kDa antigen in dermal extract on Western immunoblot (1). This antigen is not completely characterized, as it differs from collagen type VII and laminin-5 (5). Until now, several cases of anti-p200 pemphigoid have been reported. A number of cases have been seen in association with psoriasis, especially among people of Japanese origin (6–8).

In most of the reported cases, treatment with corticosteroids was not sufficient and the addition of dapsone was needed (9).

We describe here a patient with unusual morphological findings and anti-p200 pemphigoid; the first one reported as apparently induced by medication, in this case penicillin. The skin and mucosal lesions showed a good response to combined treatment with methotrexate and prednisone.

CASE REPORT

A 52-year-old woman developed painful oral erosions and skin lesions 5 days after the beginning of penicillin therapy, which was given for prolonged cough. Skin lesions consisted of tense blisters on an erythematous base symmetrically distributed on the distal parts of the extremities. A diagnosis of Stevens-Johnson syndrome was made and treatment with dexamethasone was initiated. Skin and mucosal lesions cleared after 2 weeks and treatment was discontinued. One week later the patient developed tense blisters localized on the flexural surfaces of the upper limbs, inner thighs and wrists with coexisting few oral erosions (Fig 1a). This time a direct immunofluorescence study was performed showing the presence of IgG and C3 linear deposits along the basement membrane zone (BMZ). Indirect immunofluorescence revealed the presence of circulating IgG anti-BMZ antibody at a titre of 1:640. A diagnosis of BP was made and combined therapy of prednisone 60 mg/day (1 mg/kg) and dapsone 100 mg/day was initiated. There was no improvement in the skin lesions during the ensuing 2 weeks. Dapsone had to be discontinued because of increasing methaemoglobinaemia.

After 2 months' treatment with prednisone 60 mg/day the patient developed generalized superficial spreading erythematous lesions forming concentric rings clinically resembling erythema gyratum repens (Fig. 1b). In some areas concentric plaques were covered by vesicles and erosions. Laboratory investigations (X-ray of the chest and the upper part of gastrointestinal tract, ultrasonography of the abdomen and of the mammary glands, ultrasonography, scintigraphy and biopsy of the thyroid glands, gynaecological study, markers of neoplasia – CEA, AFP, CA125, CA19-9, and colonoscopy) did not reveal internal malignancy.

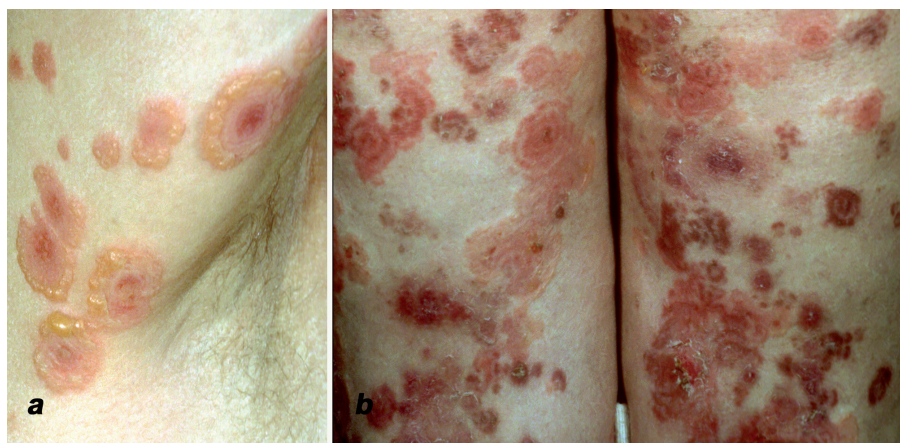

Fig. 1. Peripherally spreading tense serous blisters: (a) on the axillary fold, and (b) erythema gyratum repens-like lesions on the posterior aspect of the thighs.

Because of the atypical clinical presentation and its poor response to a high dose of systemic corticosteroids, additional studies were performed. Using laser scanning confocal microscopic (LSCM) study we compared the localization of *in vivo* bound IgG to the localization of various BMZ markers: monoclonal antibody directed against β 4-integrin (upper part of lamina lucida marker), laminin-5 (lamina lucida-lamina densa border marker) and collagen IV (lamina densa marker). Immunoglobulins were visualized by labelling with fluorescein isothiocyanate (FITC)-conjugated goat anti-human IgG antibody, whereas BMZ markers were labelled with Cy5-conjugated anti-mouse antibodies. Immunofluorescence images were overlaid by an image processing system integrated in the LSCM and photographed (10). LSCM study disclosed the presence of *in vivo* bound IgG below the localization of β 4-integrin, above the localization of collagen IV and co-distributed with laminin-5 (Fig. 2). Indirect immunofluorescence showed reactivity of circulating IgG anti-BMZ antibody with the dermal side of the salt-split skin (Fig. 3). Western immunoblot analysis performed on the dermal extract showed serum reactivity with 200 kDa protein (Fig. 4). Histology showed subepidermal blisters and the inflammatory infiltrations in the dermis consisted mostly of neutrophils (not shown).

A final diagnosis of anti-p200 pemphigoid was made and the treatment was modified. After adding methotrexate 12.5 mg/week to corticosteroids 40 mg/day, the

skin lesions healed in 3 weeks. At this time there was post-inflammatory hyperpigmentation but no scarring on the skin. During the next 3 months prednisone was tapered and withdrawn. During the ensuing 4 months' treatment with methotrexate 5 mg a week, the patient was in remission, following which the treatment was discontinued. The skin lesions did not reappear in 3 months' follow-up and repeated serum study for the presence of anti-BMZ antibody was negative.

DISCUSSION

Several cases of drug-induced autoimmune bullous diseases, especially pemphigus foliaceus and BP have been described (11–14). The development of bullae 1–3 months after the introduction of an offending drug strongly suggests the diagnosis of drug-induced BP (13). In most of the patients, stopping the suspected medication improved the eruption, but in some with severe disease this was not the case (13). We report here the first patient with anti-p200 pemphigoid probably provoked by oral intake of penicillin given because of prolonged cough. Oral and skin lesions started 5 days after the beginning of therapy and were initially diagnosed as bullous erythema multiforme. Skin lesions disappeared in 2 weeks on corticosteroid treatment, but reappeared one week after steroid was tapered, this time resistant to corticosteroids.

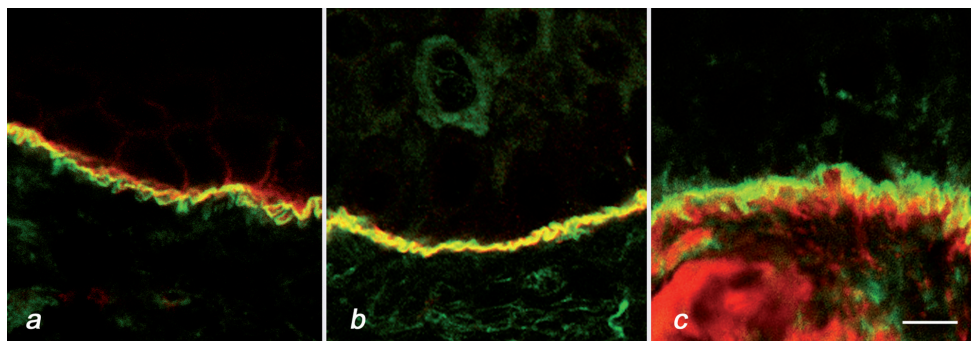


Fig. 2. Overlay antigen mapping study on patient's skin biopsy using laser scanning confocal microscopy showed the presence of linear IgG deposits (green): (a) below the localization of β 4-integrin (red), (b) on the level of laminin-5 (yellow staining due to overlapping of green and red fluorescence), and (c) above the localization of collagen IV (red). Bar 15 μ m.

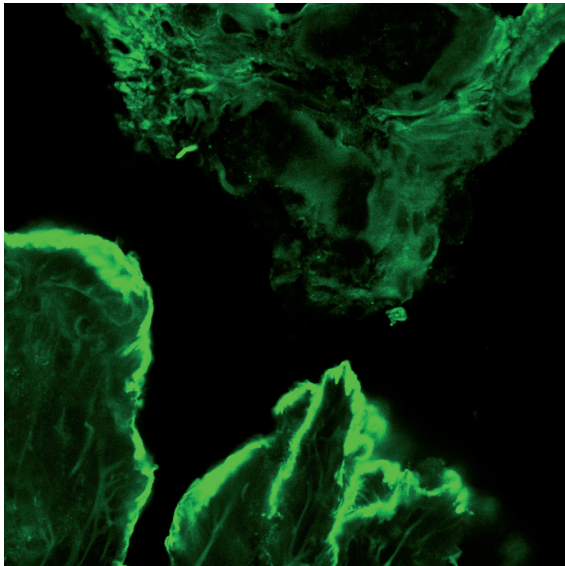


Fig. 3. Indirect immunofluorescence on salt-split skin: reactivity of patient's serum with the floor of the artificial bulla.

Immunopathological studies showed the presence of *in vivo* bound and circulating IgG anti-BMZ antibody reactive with the dermal side of salt-split skin and 200 kDa protein on dermal extract by immunoblot. The bullous erythema multiforme preceded the onset of drug induced anti-p200 pemphigoid, which started 5 days after drug intake. During hospitalization the skin eruptions evolved into lesions clinically resembling erythema gyratum repens, which has not been previously reported in anti-p200 pemphigoid. Laboratory investigations did not reveal internal malignancy.

The majority of published cases with anti-p200 pemphigoid were younger than our patient's 52 years, while BP normally affects older patients. Differential diagnosis are inflammatory types of epidermolysis bullosa acquisita (EBA) (15), bullous systemic lupus erythematosus (15), anti-laminin-5 cicatricial pemphigoid (16) and anti-p200 pemphigoid (1).

A precise diagnosis of autoimmune, subepidermal bullous diseases has significant implications for both prognosis and treatment. In patients with anti-laminin-5 cicatricial pemphigoid it is necessary to exclude the presence of internal cancer, in EBA – the presence of inflammatory bowel diseases or/and endocrinopathies or lymphoma/leukaemia, whereas anti-p200 pemphigoid has no recognized systemic associations and seems to be linked only with psoriasis vulgaris (8). In our case of anti-p200 pemphigoid there was no evidence or history of either internal malignancy or other skin diseases.

This is the first study on the localization of *in vivo* bound IgG in anti-p200 pemphigoid established by overlay antigen mapping using the LSCM technique. This method allows the differentiation of autoimmune subepidermal bullous diseases based on comparison of

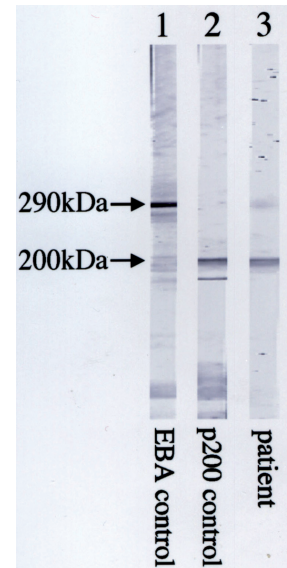


Fig. 4. Western blot on the dermal extract showed the reactivity of the patient's serum with protein 200 kDa (lane 3), which was exactly the same mobility with the 200 kDa protein in control anti-p200 pemphigoid (lane 2). Control epidermolysis bullosa acquisita (EBA) serum reacted with the 290 kDa type VII collagen (lane 1).

localization of *in vivo* bound IgG to the localization of different BMZ markers. It is of special value in diagnosing cases not detectable via circulating antibody (10).

Interestingly, there is a discrepancy between the localization of 200 kDa antigen and *in vivo* bound IgG determined by direct immunoperoxidase electron microscopy, which shows the presence of immunodeposits throughout the entire lamina lucida and lamina densa (1). In our patient *in vivo* bound IgG was localized below β 4-integrin, above collagen IV and co-distributed with laminin-5, which corresponds with their ultrastructural localization at the border of lamina lucida-lamina densa. This finding reflects the ultrastructural localization of the target antigen (6). The lack of co-localization of *in vivo* bound IgG and β 4-integrin indicates the absence of immunodeposits in the upper part of lamina lucida. This suggests the diffusion of peroxidase marker from site of reaction to the upper part of lamina lucida observed in immuno-electron microscopic study.

It has been postulated recently that combined therapy consisting of corticosteroids and sulfones might give a sustained response in patients with anti-p200 pemphigoid (9). Our patient was treated for 2 weeks with prednisone and dapsone without success. When methotrexate was added, there was an improvement. Thus, one might consider low-dose methotrexate in those patients who respond poorly or cannot tolerate dapsone.

To our knowledge, this is the first description of a patient with anti-p200 pemphigoid who presented erythema gyratum repens-like lesions. In addition, we believe this to be the first report of a patient in whom this disorder was probably drug induced.

ACKNOWLEDGEMENT

This work was supported by a grant from the Polish Scientific Research Committee (KBN No. 2 PO5B 176 29 and KBN No. 2 PO5B 065 30).

REFERENCES

- Zillikens D, Kawahara Y, Ishiko A, Shimizu H, Mayer J, Rank C, et al. A novel subepidermal blistering disease with autoantibodies to a 200-kDa antigen of the basement membrane zone. *J Invest Dermatol* 1996; 106: 1333–1338.
- Kawahara Y, Zillikens D, Yancey KB, Marinkovich MP, Nie Z, Hashimoto T, et al. Subepidermal blistering disease with autoantibodies against a novel dermal 200-kDa antigen. *J Dermatol Sci* 2000; 23: 93–102.
- Salmhofer W, Kawahara Y, Soyer HP, Kerl H, Nishikawa T, Hashimoto T. A subepidermal blistering disease with histological features of dermatitis herpetiformis and immunofluorescence characteristics of bullous pemphigoid: a novel subepidermal blistering disease or a variant of bullous pemphigoid? *Br J Dermatol* 1997; 137: 599–604.
- Umemoto N, Demitsu T, Toda S, Noguchi T, Suzuki SI, Kakurai M, et al. A case of anti-p200 pemphigoid clinically mimicking inflammatory epidermolysis bullosa acquisita. *Br J Dermatol* 2003; 148: 1058–1060.
- Shimanovich I, Hirako Y, Sitaru C, Hashimoto T, Brocker EB, Butt E, et al. The autoantigen of anti-p200 pemphigoid is an acidic noncollagenous N-linked glycoprotein of the cutaneous basement membrane. *J Invest Dermatol* 2003; 121: 1402–1408.
- Morris SD, Mallipeddi R, Oyama N, Gratian MJ, Harman KE, Bhogal BS, et al. Psoriasis bullosa acquisita. *Clin Exp Dermatol* 2002; 27: 665–669.
- Chen KR, Shimizu S, Miyakawa S, Ishiko A, Shimizu H, Hashimoto T. Co-existence of psoriasis and an unusual IgG-mediated subepidermal bullous dermatosis; identification of a novel 200-kDa lower lamina lucida target antigen. *Br J Dermatol* 1996; 134: 340–346.
- Yasuda H, Tomita Y, Shibaki A, Hashimoto T. Two cases of subepidermal blistering disease with anti-p200 or 180-kD bullous pemphigoid antigen associated with psoriasis. *Dermatology* 2004; 209: 149–155.
- Conleth A, Egan MD, Carole Yee, Zillikens D, Yancey KB. Anti-p200 pemphigoid: Diagnosis and treatment of a case presenting as an inflammatory subepidermal blistering disease. *J Am Acad Dermatol* 2002; 46: 786–789.
- Wozniak K, Kazama T, Kowalewski C. A practical technique for differentiation of subepidermal bullous diseases: localization of in vivo bound IgG by laser scanning confocal microscopy. *Arch Dermatol* 2003; 139: 1007–1011.
- Brenner S, Bialy-Golan A, Ruocco V. Drug-induced pemphigus. *Clin Dermatol* 1998; 16: 393–397.
- Aksakal BA, Ozsoy E, Arnavut O, Ali Gurer M. Oral terbinafine-induced bullous pemphigoid. *Ann Pharmacother* 2003; 37: 1625–1627.
- Millard TP, Smith HR, Black MM, Barker JN. Bullous pemphigoid developing during systemic therapy with chloroquine. *Clin Exp Dermatol* 1999; 24: 263–265.
- Mehravaran M, Gyulai R, Husz S, Dobozy A. Drug-induced erythema multiforme-like bullous pemphigoid. *Acta Derm Venereol* 1999; 79: 233.
- Gammon WR, Briggaman RA. Epidermolysis bullosa acquisita and bullous systemic lupus erythematosus. Diseases of autoimmunity to type VII collagen. *Dermatol Clin* 1993; 11: 535–547.
- Yancey KB, Kirtschig G, Yee C, Lazarowa Z. Studies of patients with anti-epiligrin cicatricial pemphigoid. *J Dermatol* 1995; 22: 829–835.