

Depot Leuprorelin Acetate-induced Granulomas Manifested as Persistent Suppurative Nodules

Marta Ferran¹, Ana Giménez-Arnau¹, Augustí Toll¹, Mireia Yébenes¹, Verónica Baena², Josep Lloreta² and Ramon M. Pujol¹

Departments of ¹Dermatology and ²Pathology, Hospital del Mar, IMAS, Passeig Marítim 25–29, ES-08003 Barcelona, Spain. E-mail: mferran@imas.imim.es

Accepted May 8, 2006.

Sir,

Leuprorelin acetate (Procrin[®]) is a synthetic agonist analogue of gonadotrophin-releasing hormone (Gn-RH or luteinizing hormone-releasing hormone), administered as intramuscular or subcutaneous injections, and indicated for the treatment of advanced prostate cancer.

In the last decade, sustained release parenteral depot formulations have been developed, by entrapping the hydrophilic leuprorelin in biodegradable highly lipophilic synthetic polymer microspheres. Depending on the type of polymer being used, the peptide drug is released from these depot formulations at different constant rates. Polylactic and glycolic acids (PLGA) are used for a one-month depot injections, and polylactic acid (PLA) for depot injections longer than 2 months.

Cutaneous adverse events to leuprorelin acetate are rare, but several cases of local reactions at the injection sites have been reported in urology or paediatric journals (1–5). These reactions have been described as erythematous macules, infiltrated plaques, subcutaneous nodules and sterile abscesses. A possible role of either leuprorelin acetate itself or lipophilic synthetic polymer used in depot injections has been postulated as responsible for such reactions (6).

CASE REPORT

A 78-year-old man was referred to our department for evaluation of a persistent inflammatory suppurative subcutaneous nodule on his right arm. Past medical history disclosed a familial protein C deficiency (treated with acenocoumarol and without any vascular complication) and advanced prostate cancer diagnosed in 1988. During the last months, the patient was receiving injections with 3-month depot formulation of leuprorelin acetate. Since he was receiving treatment with oral anticoagulants, the injections were administered subcutaneously instead of intramuscularly (the recommended route).

Four months before consultation, the patient noticed a painful erythematous subcutaneous papule-nodule developing at the injection site of the third dose of leuprorelin acetate. The lesion had appeared a few days after the injection, and had enlarged progressively, developing a central ulcer. Treatment with oral antibiotics (amoxicillin/clavulanic acid) was prescribed without any clinical improvement.

Physical examination disclosed an apparently healthy man presenting a fistulated subcutaneous nodule, 3 cm in diameter, on the lateral aspect of his right arm. It was a painful lesion that drained a dense serous material. No fever, malaise, regional enlarged lymph nodes or hepatosplenomegaly were noted.

Several bacteriological, mycobacteriological and fungal cultures from swabs obtained from the exudate yielded negative results. Treatment with oral tetracycline and clarithromycin, as well as topical cures with mupirocin, was prescribed and the lesion resolved in 2 months.

During the following months, the patient developed two additional similar lesions on the left buttock (Fig. 1) and on

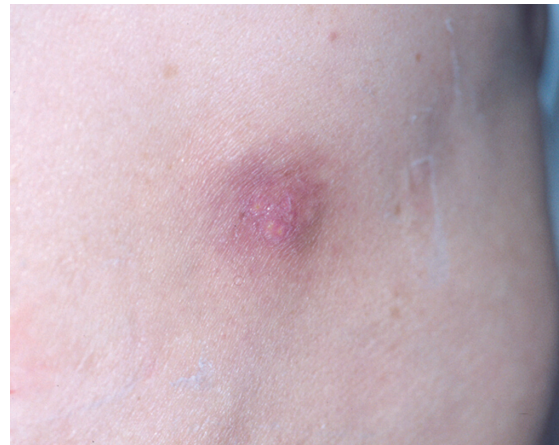

Fig. 1. Inflammatory nodule at the sites of subcutaneous leuprorelin depot injections on the lateral aspect of the left buttock.

the lateral aspect of the left arm, corresponding to the injection sites of the fifth and sixth doses of leuprorelin acetate. Clinically both lesions corresponded to subcutaneous nodules that developed several days after injections and persisted several months, presenting a central suppurative ulcer.

Several skin biopsy specimens were obtained. A biopsy specimen from a fully developed lesion obtained from the nodule on the right arm disclosed an acanthotic, focally eroded epidermis with a marked dermal oedema, as well as a vascular proliferation, in the superficial dermis. In the mid-dermis, a granulomatous infiltrate with numerous vacuolated foreign body giant cells and scattered eosinophils was also present (Fig. 2A). In the deep dermis, a moderate infiltrate composed mainly of vacuolated histiocytes, with scattered lymphocytes and eosinophils was found, and occasional irregular empty spaces were noted. Special stains for micro-organisms were performed (PAS-diastase and Zhiel-Neelsen) but they were negative. Cultures from the biopsy specimen for bacteria, fungi and mycobacteria were also negative.

The ultrastructural study from the first biopsy revealed the presence of multinucleated cells, occasionally engulfing elastic fibres, and epithelioid cells. Some irregular spaces were noted within the interstitial space, as well as empty vacuoles (probably delipidated) in the cytoplasm of multinucleated cells (results not shown).

After obtaining informed consent from the patient, patch tests, prick tests and intradermal tests with 3-month depot Procrin[®] (Abbott Laboratories, S.A., Madrid, Spain) were performed. The patch test, as well as the prick test yielded negative results. However, the intradermal test resulted in the development of an inflammatory papule that appeared 30 min after injection and persisted for more than 4 months. Conversely, an intradermal test with daily formulation of Procrin[®] (without synthetic polymers) did not reproduce the inflammatory lesion.

Histopathological studies from an intradermal test punch biopsy disclosed the presence of small, round, apparently empty, cyst-like spaces of different sizes, non-birefringent, in deep dermis and subcutaneous tissue, mixed with an inflammatory infiltrate, mainly composed of histiocytes and neutrophils (Fig. 2B).

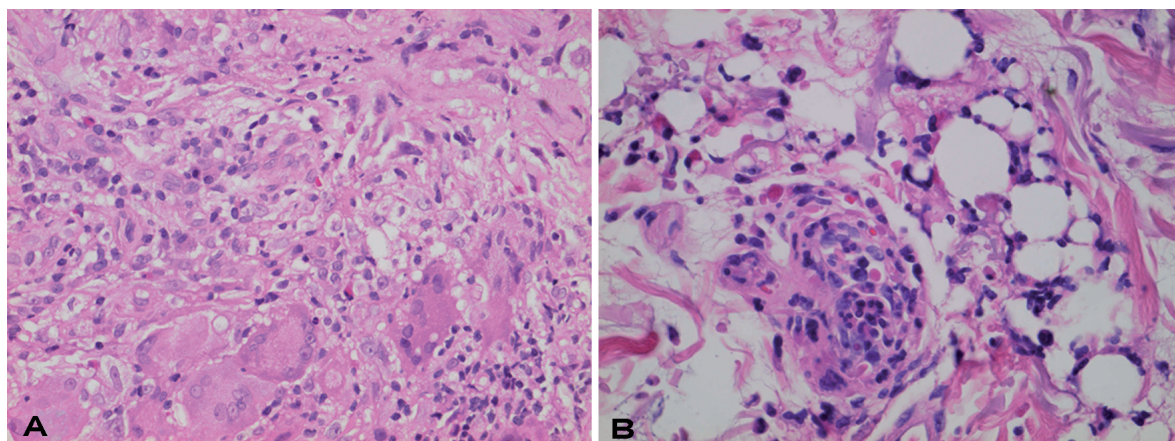


Fig. 2. (A) Skin biopsy of lesion in Fig. 1 showing dense granulomatous infiltrate with numerous vacuolated foreign body giant cells and scattered eosinophils in mid-dermis (HE×200). (B) Histopathological features from a 30-min intradermal test punch biopsy showing a perivascular inflammatory infiltrate in the superficial dermis, mainly composed of neutrophils, and focal apparently empty cyst-like spaces (HE×400).

DISCUSSION

Several adverse effects secondary to leuporelin acetate injections have been reported, the most frequent of which are secondary to the hormonal imbalance and are usually well tolerated. Rarely, severe allergic reactions have been reported (1). During post-marketing surveillance, non-specific rashes, urticaria and photosensitivity were also observed, and Grimwood & Guevara (2) have recently reported a case of dermatitis herpetiformis triggered by intramuscular injections of leuporelin acetate. However, the most frequent cutaneous adverse effects (ranging from 3% to 13% of paediatric patients treated for central precocious puberty) (3–5) are local reactions at the injection sites. Erythematous macules (5), infiltrated plaques (4), subcutaneous nodules (6–8) with occasional ulceration (9) and sterile abscesses (3) have been described.

Nodular lesions developed at sites of injection have been exceptionally reported in western countries. The vast majority of cases have been described in Japanese patients (6) who are injecting leuporelin acetate subcutaneously. Since in Europe leuporelin is injected intramuscularly, it has been postulated that the granuloma formation may depend on the route of administration: the more superficial is the injection, the earlier the granuloma develops (6). Nodules tend to develop after both 1-month and 3-month depot formulation and seem to be associated with a lower absorption of leuporelin acetate (5, 6). Histopathological studies from such reactions disclosed a granulomatous reaction with foreign body giant cells containing round translucent microspheres in the subcutaneous tissue (6).

A possible role of either leuporelin acetate itself, or lipophilic synthetic polymer used in depot injections, has been incriminated as responsible for post-injection reactions. Manasco et al. (3) studied an urticarial reaction secondary to depot leuporelin therapy in a paediatric

patient, observing a positive skin test to the daily form of leuporelin (without polymers) at a 1:10 dilution. In addition, Mizoguchi et al. (10) reported that the intradermal test with leuporelin acetate alone could induce a granulomatous reaction, which would support leuporelin acetate as a responsible for these granulomatous lesions. Nevertheless, some authors have postulated that PLA polymers used in depot injections could be responsible for nodules and/or sterile abscesses formation (6).

PLGA and PLA polymers have also been used safely in suture materials, in resorbable plates and screws, in guided bone regeneration, in orbital implants, etc, but foreign body giant cell granuloma have also been described (11–13).

PLA has been recently used for soft-tissue augmentation (New-Fill®), suspended in a mannitol and carboxymethoxycellulose solution with the purpose of creating a permanent bulking effect through an intended foreign body reaction (14). Some cases of late-onset foreign body granulomatous reaction, have been reported, with giant cells containing birefringent translucent particles of irregular shape and size (15).

Our patient developed sterile abscesses and nodules at the injection sites of 3-month depot leuporelin acetate subcutaneous administration. Intradermal test with the responsible drug reproduced the clinical, histopathological (foreign-body granulomatous tissue reaction) and evolutive features (an early acute neutrophilic inflammatory infiltrate followed by a histiocytic cellular reaction) of such reaction. Conversely, intradermal tests with a non-depot leuporelin formulation, not containing lipophilic synthetic polymer microspheres, failed to reproduce the inflammatory response, suggesting a direct responsibility of PLA for this reaction.

REFERENCES

1. Taylor JD. Anaphylactic reaction to LHRH analogue, leuporelin. *Med J Aust* 1994; 161: 455.

2. Grimwood RE, Guevara A. Leuprolide acetate-induced dermatitis herpetiformis. *Cutis* 2005; 75: 49–52.
3. Manasco PK, Pescovitz OH, Blizzard RM. Local reactions to depot leuprolide therapy for central precocious puberty. *J Pediatr* 1993; 123: 334–335.
4. Tonini G, Lazzarini M. Side effects of GnRH analogue treatment in childhood. *J Pediatr Endocrinol Metab* 2000; 13: 795–803.
5. Neely EK, Hintz RL, Parker B, Bachrach LK, Cohen P, Olney R, Wilson DM. Two-year results of treatment with depot leuprolide acetate for central precocious puberty. *J Pediatr* 1992; 121: 634–640.
6. Yasukawa K, Sawamura D, Sugawara H, Kato N. Leuprorelin acetate granulomas: case reports and review of the literature. *Br J Dermatol* 2005; 152: 1045–1047.
7. Whitaker IS, Fazel MZ, Joshi HB, Moseley RP, Turner WH. Leuprorelin acetate granulomas: recurrent subcutaneous nodules mimicking metastatic deposits at injection sites. *BJU Int* 2002; 90: 350.
8. Saxby M. Leuprorelin acetate granulomas: recurrent subcutaneous nodules mimicking metastatic deposits at injections sites. *BJU Int* 2003; 91: 125.
9. Tachibana M, Yamano Z, Kusuda Y, Hara S, Shimogaki H, Hamami G. Cutaneous epithelioid granulomas caused by subcutaneous infusion of leuprorelin acetate: a case report. *Hinyokika Kyo* 2004; 50: 199–202.
10. Mizoguchi K, Hamasaki Y, Katayama I, Igawa T. A case of drug induced granulomatous reaction by leuprorelin acetate for prostate cancer. *Jpn J Dermatol* 2004; 114: 163–167.
11. Pavlovich R Jr, Caminear D. Granuloma formation after chevron osteotomy fixation with absorbable copolymer pin: a case report. *J Foot Ankle Surg* 2003; 42: 226–229.
12. Moore JW, Brekke JH. Foreign body giant cell reaction related to placement of tetracycline-treated polylactic acid: report of 18 cases. *J Oral Maxillofac Surg* 1990; 48: 808–812.
13. Mosier-Laclair S, Pike H, Pomeroy G. Intraosseous bioabsorbable poly-L-lactic acid screw presenting as a late foreign-body reaction: a case report. *Foot Ankle Int* 2001; 22: 247–251.
14. Christensen L, Breiting V, Janssen M, Vuust J, Hogdall E. Adverse reactions to injectable soft tissue permanent fillers. *Aesthetic Plast Surg* 2005; 29: 34–48.
15. Dijkema SJ, van der Lei B, Kibbelaar RE. New-fill injections may induce late-onset foreign body granulomatous reaction. *Plast Reconstr Surg* 2005; 115: 76–78.