

## Multiple Keratoacanthomas as an Untoward Response to Imiquimod Therapy for Actinic Keratoses

Stephen D'Addario<sup>1,2</sup> and Patrick R. Carrington<sup>1,2</sup>

<sup>1</sup>University of Arkansas for Medical Sciences and <sup>2</sup>Dermatology Service 111/LR, Department of Medicine, Central Arkansas Veterans Healthcare System, 4300 W 7th Street, Little Rock, Arkansas 72205, USA. E-mail: Patrick.carrington@med.va.gov

Accepted March 21, 2006.

Sir,

Imiquimod treatment of actinic keratoses (AK), usually highly effective, may yield squamous cell carcinoma of the keratoacanthoma type (SCC-KA), histopathologically reminiscent of the multiple self-healing squamous carcinomas of Ferguson-Smith.

In this regard, *dermatosis locus minoris resistentiae* (DLMR), meaning dermatosis in "place of less resistance", connotes the formation of a primary dermatological condition in a site of altered or compromised skin, and, although SCC-KA may occasionally be abortive and "reactive", with a tendency towards spontaneous regression, it may progress to frank invasive SCC even with metastasis (1, 2). The "reactive" subset of SCC-KA may appear in areas of scar formation, psoriasis, discoid lupus erythematosus, laser resurfacing, radiation therapy, donor skin graft sites and Mohs' surgical site scars, as an unusual event representing DLMR (3–6). Herein, we report a case of secondary reactive and multiple (> 17) SCC-KA that occurred during an exuberant inflammatory response to imiquimod therapy utilized for extensive and confluent AK of the left forearm.

### CASE REPORT

A 60-year-old man with extensive photodamage and confluent AK of the forearms, worse on the left, was prescribed imiquimod 5% cream thrice weekly for 6 weeks, but returned 8 weeks later with a generalized eruption and a peculiar markedly well-localized, exuberant, exudative reaction affecting the left forearm treatment site. He had used imiquimod nightly and was experiencing systemic symptoms including fever, chills, arthralgias and myalgias. A diffuse erythematous maculopapular eruption was noted across the chest, back, and abdomen with excoriations, consistent with autosensitization (id). On the left forearm was an extensively eroded markedly indurated plaque on an erythematous base containing greater than 17 foci of well-delineated crusted inspissated discoid and exudative nodules, dome-shaped and hyperkeratotic, up to 1–1.5 cm in size (Fig. 1). The right forearm showed the typical imiquimod treatment response with eczematization and crusting. Treatment with 60 mg triamcinolone acetonide intramuscular and topical triamcinolone 0.1% ointment for the id reaction was instituted, and cephalexin for possible clinical infection of the forearm was begun after an incisional shave biopsy was performed of the largest dome-shaped hyperkeratotic nodule. Imiquimod was discontinued and local wound care to the forearm with petrolatum and loose bandages was instituted.

On histopathological examination the first biopsy revealed absence of the typical crateriform morphology usually associated with solitary SCC-KA, but a nodular proliferation of cytologically malignant keratinocytes was seen invading the

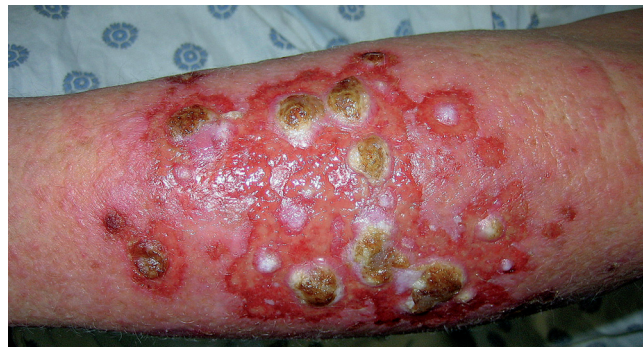

Fig. 1. Patient's left forearm revealing an extensively eroded markedly indurated plaque on an erythematous base containing more than 17 foci of well-delineated crusted inspissated exudative discoid nodules, dome-shaped and hyperkeratotic, up to 1–1.5 cm in size.

dermis with mitotic figures present, consistent with SCC-KA reminiscent of the Ferguson-Smith type of multiple self-healing squamous carcinomas (Fig. 2). Two weeks later all but one of the discoid exudative nodules had resolved so that a second biopsy of the persistent remaining nodule (the original nodule had resolved) was performed and frozen section interpretation revealed hyperplastic epidermis, with no evidence of carcinoma. This was disparate with the original biopsy results. As a definitive diagnosis of SCC could not be made (or excluded) with certainty during this clinic visit utilizing frozen section interpretation, it was decided to utilize Mohs' excision of the remaining persistent nodule due to rapidity of growth of these lesions coupled with the atypical and unpredictable clinical course never before seen during imiquimod treatment. One Mohs' layer of the remaining affected area was examined reveal-

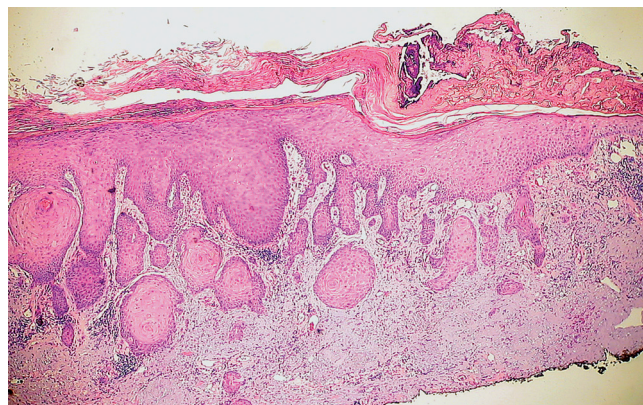


Fig. 2. Histopathology reveals absence of crateriform morphology usually associated with squamous cell carcinoma of the keratoacanthoma type (SCC-KA), but a proliferation of cytologically malignant keratinocytes invading the underlying dermis associated with mitotic figures is consistent with the Ferguson-Smith variant of SCC-KA.

ing hyperplastic epidermis but no residual carcinoma suggesting self-resolution of these reactive secondary keratoacanthomas. Two months status post Mohs' excision showed a well-healed scar with no evidence of recurrence (Fig. 3). Improvement of the surrounding skin texture, dyschromia and actinic damage were also evident.

## DISCUSSION

Herein, we present a case of SCC-KA occurring as DLMM, after application of a topical immune-response modifier. Development of therapeutic alternatives for treatment of ultraviolet damage and AK has led to the immune response modifier imiquimod, an imidazoquinolone molecule that interacts with toll-like receptor 7 on antigen-presenting dendritic cells. Subsequent activation of the innate and acquired immune systems stimulates and augments the production of interferon, interleukins and tumour necrosis factor. The downstream effects of such up-regulation include enhancement of the inflammatory response and immune recognition and destruction of tumour cells. Case reports of therapeutic efficacy or failure of imiquimod in the treatment of lentigo maligna and Bowen's disease are noted (7–9), but our case may represent the first in which atypical eruptive and "reactive" SCC-KAs have developed in response to treatment with an immune response modifier, representing an immunologically and chemically-induced DLMM. An analogous report of carcinoma occurring after 5-fluorouracil treatment of KA reiterates the diagnostic pitfalls in histopathology for determination of SCC-KA as some cases may represent pseudoepitheliomatous hyperplasia alone and not true carcinoma, however, we feel the atypical histopathological features of our secondary or reactive keratoacanthomas are more reminiscent of the Ferguson-Smith variant of keratoacanthoma (10). Although imiquimod's efficacy to promote KA regression

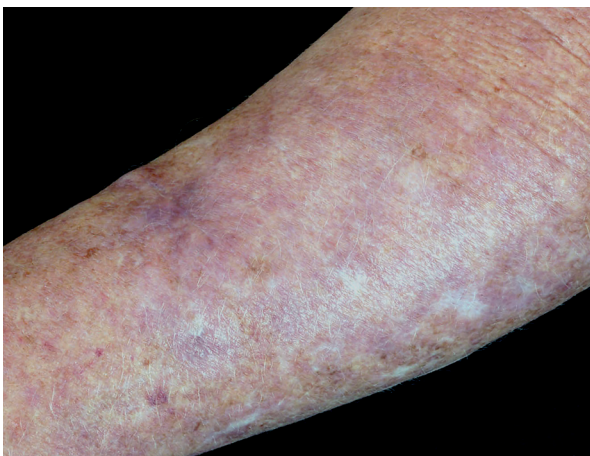


Fig. 3. Two months after Mohs' procedure reveals a well-healed scar with no evidence of recurrence. Improvement of the surrounding skin texture, dyschromia and actinic damage were also evident.

is well documented, the clinical regression of five of six KA within 7 weeks of intralesional interferon  $\alpha$ -2a administration makes it difficult to understand the mechanism of tumour development in our patient (11–15).

## ACKNOWLEDGEMENTS

There are no applicable funding sources to disclose regarding this manuscript. Dr Carrington is a consultant for 3M Pharmaceuticals, Inc., maker of imiquimod (Aldara).

## REFERENCES

- Hodak E, Jones RE, Ackerman AB. Controversies in dermatology. Solitary keratoacanthoma is a squamous-cell carcinoma: three examples with metastases. With responses by Grant-Kels JM, From L, Reed RJ, et al. *Am J Dermatopathol* 1993; 15: 332–352.
- Poleksic S, Yeung K-Y. Rapid development of keratoacanthoma and accelerated transformation into squamous cell carcinoma of the skin. *Cancer* 1970; 41: 12–16.
- Haider S. Keratoacanthoma in a smallpox vaccination site. *Br J Dermatol* 1974; 90: 689–690.
- Fanti PA, Tosti A, Peluso AM, Bonelli U. Multiple keratoacanthoma in discoid lupus erythematosus. *J Am Acad Dermatol* 1989; 21: 809–810.
- Tamir G, Morgenstern S, Ben-Amitay D, Okon E, Hauben DJ. Synchronous appearance of keratoacanthomas in burn scar and skin graft donor site shortly after injury. *J Am Acad Dermatol* 1999; 40: 870–871.
- Goldberg LH, Silapunt S, Beyrau KK, Peterson SR, Friedman PM, Alam M. Keratoacanthoma as a postoperative complication of skin cancer excision. *J Am Acad Dermatol* 2004; 50: 753–758.
- Salsche S, Levine N, Morrison L. Cycle therapy of actinic keratoses of the face and scalp with 5% topical imiquimod cream: an open-label trial. *J Am Acad Dermatol* 2002; 47: 571–577.
- Geisse J, Caro I, Lindholm J, Golitz L, Stampone P, Owen M. Imiquimod 5% cream for the treatment of superficial basal cell carcinoma: results from two phase III, randomized, vehicle-controlled studies. *J Am Acad Dermatol* 2004; 50: 722–733.
- Lebwohl M, Dinehart S, Whiting D, Lee PK, Tawfik N, Jorizzo J, et al. Imiquimod 5% cream for the treatment of actinic keratosis: results from two phase III, randomized, double-blind, parallel group, vehicle-controlled trials. *J Am Acad Dermatol* 2004; 50: 714–721.
- Cobb MW, Pellegrini AE. Squamous cell carcinoma following fluorouracil-responsive keratoacanthoma. *Arch Dermatol* 1987; 123: 987–988.
- Di Lernia V, Ricci C, Albertini G. Spontaneous regression of keratoacanthoma can be promoted by topical treatment with imiquimod cream. *J Eur Acad Dermatol Venereol* 2004; 18: 626–629.
- Bhatia N. Imiquimod as a possible treatment for keratoacanthoma. *J Drugs Dermatol* 2004; 3: 71–74.
- Dendorfer M, Opiel T, Wollenberg A, Prinz JC. Topical treatment with imiquimod may induce regression of facial keratoacanthoma. *Eur J Dermatol* 2003; 13: 80–82.
- Wee SA. Multiple eruptive keratoacanthomas, de novo. *Dermatol Online J* 2004; 10: 19.
- Grob JJ, Suzini F, Richard MA, Weiller M, Zarour H, Noe C, et al. Large keratoacanthomas treated with intralesional interferon alfa-2a. *J Am Acad Dermatol* 1993; 29: 237–241.