

CLINICAL REPORT

Progressive Nodular Histiocytoma Associated with Thrombocytopenia with Absent Radii (TAR Syndrome) and Angiofibromas

Elena ROSÓN, Ángeles FLÓREZ, Carlos FEAL, Carlos DE LA TORRE, Ignacio GARCÍA-DOVAL, Teresa ABALDE and Manuel CRUCES

Department of Dermatology, Hospital Provincial, Complejo Hospitalario de Pontevedra, Pontevedra, Spain

A 50-year-old woman was admitted due to a long-standing history of cutaneous lesions, which were gradually increasing in number and size, located on the trunk and extremities. Histological studies confirmed the initial clinical diagnosis of histiocytomas. Moreover, the patient had numerous smooth erythematous papules on her chin and around her nose, which were diagnosed histologically as angiofibromas. The patient had congenital phocomelia. Analytical and imaging studies revealed the presence of bilateral phocomelia due to absent radii and thrombocytopenia (TAR syndrome). Multiple histiocytomas in a normolipaemic patient bring up several differential diagnoses. Slow progressive evolution without spontaneous resolution and a scattered distribution on the trunk and extremities suggest the diagnosis of progressive nodular histiocytoma. To our knowledge progressive nodular histiocytoma has not been reported previously associated either with TAR syndrome or with angiofibromas. These entities are uncommon, thus their association may not be due to chance. Key words: progressive nodular histiocytoma; thrombocytopenia; absent radii; phocomelia; TAR syndrome; angiofibromas.

(Accepted January 4, 2006.)

Acta Derm Venereol 2006; 86: 348–350.

Elena Rosón, Servicio de Dermatología, Hospital Provincial, C/ Loureiro Crespo no. 2, ES-36001 Pontevedra, Spain. E-mail: erosen64@yahoo.es

Progressive nodular histiocytoma was first coined as an entity by Tauton et al. in 1978 (1). The disease is characterized by the progressive appearance of cutaneous and mucosal histiocytomas without spontaneous resolution in a normolipaemic state. Flexural folds and joints are not predominantly involved. Two clinically distinct lesions have been reported: superficial, firm, round or pedunculate, yellowish-brown tumours and deep purplish nodules with overlying telangiectasia. They often grow to a large size (0.4–5 cm). Histologically, the lesions consist of a fibrohistiocytic infiltrate with multinucleated and foamy cells. Characteristically specific stains for lipids (oil red O stain) and iron (Gomori's stain) are positive.

Angiofibromas are benign tumours frequently seen as isolated fibrous nasal papules. Multiple angiofibromas can form part of complex syndromes such as tuberous sclerosis and multiple endocrine neoplasia type 1 (MEN 1) which must be ruled out (2).

Thrombocytopenia with absent radii (TAR) syndrome (OMIM 274000) is a poly-malformative syndrome first described by Gross et al. in 1956 (3). In the majority of cases there is an autosomal recessive inheritance. It is characterized by the association of thrombocytopenia, usually more intense during the neonatal period, and bilateral radial aplasia or hypoplasia. A great variability of associated abnormalities involving the skin, the eyes and skeletal, gastrointestinal, renal and cardiac systems have been reported (4–6). In addition some of the patients reported so far developed haematological and solid organ tumours (6–7).

CASE REPORT

A 50-year-old woman presented with a 20-year history of cutaneous lesions located on the trunk and extremities, which were gradually increasing in number and size. Physical examination showed a cervical, peduncular, soft, 3 cm tumour (Fig. 1a), two other firm, yellow-brown lesions, measuring 3 and 4 cm in the left abdominal wall (Fig. 1b) and multiple, scattered, violaceous tumours with overlying telangiectasia, 1–4 cm in diameter on the lower limbs (Fig. 1c). Biopsies of the lesions showed a fibrohistiocytic infiltrate with multinucleated and foamy cells (Fig. 2). Immunohistochemical studies were positive for CD68. They were labelled as histiocytomas. Moreover, the patient showed on her face, mainly on her chin and around her nose, multiple smooth erythematous 2–3 mm papules (Fig. 3). Histological studies revealed vascular dilatation and proliferation and fibrosis in dermis confirming the initial diagnosis of angiofibromas (Fig. 4). The patient showed phocomelia (Fig. 5), a congenital malformation that had not been previously labelled. In addition, we observed the appearance of large haematomas in areas of surgical trauma. Her medical history included the excision of several cutaneous tumours of unknown diagnosis and a

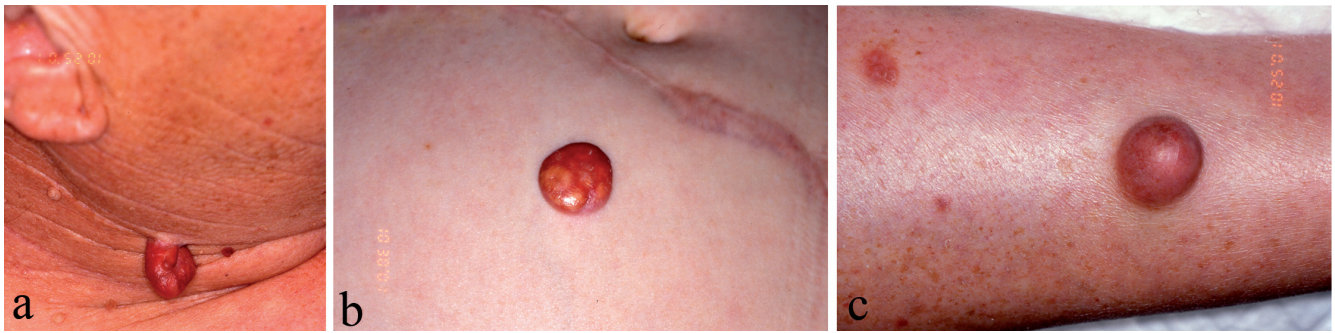

Fig. 1. Cervical, soft, pedunculate tumour (a). Firm, yellow-brown, smooth, abdominal lesion (b). Violaceous, soft tumour with overlying telangiectasia on the lower limbs (c).

hysterectomy due to uterine fibromas. One of her sisters had phocomelia and had died at the age of 6 weeks. There was no consanguinity between parents.

Laboratory studies, including blood lipid levels, were all normal except from thrombopenia $61 \times 10^9/l$ (normal: $130-400 \times 10^9/l$). The karyotype was normal. Image studies showed bilateral absent radii, hands and feet syndactylia, lower limbs shortening, femoro-tibial subluxation, costo-clavicular ossification and hypertelorism. An ultrasound study of the abdomen revealed only hepatic steatosis. An echocardiogram did not show any relevant finding. An upper gastrointestinal endoscopy demonstrated the presence of a clinically benign submucous tumour in the right piriform sinus.

The patient was diagnosed with progressive nodular histiocytoma associated with TAR syndrome and angiofibromas.

DISCUSSION

Multiple histiocytomas in a normolipaemic state give rise to differential diagnoses, chiefly including multiple juvenile xanthogranulomas, eruptive histiocytoma, reticulohistiocytosis, xanthoma disseminatum and lipogranulomatosis of Faber. The appearance after childhood, progressive nature without spontaneous resolution, no predilection for the flexural folds and joints and the absence of associated systemic involvement are characteristic of progressive nodular histiocytoma. Other unusual proliferative histiocytic syndromes, such as progressive nodular histiocytosis (8) and hereditary progressive mucinous histiocytosis (9), are more difficult to define and classify as independent entities. Progressive nodular histiocytosis is characterized by an intense involvement of the face where the lesions tend to group resulting in the typical morphology of leonine facies. Hereditary progressive mucinous histiocytosis is an inherited disease. Typically the lesions are smaller and histological studies demonstrate the presence of mucine.

Multiple angiofibromas initially suggest the diagnosis of tuberous sclerosis. This disease can be ruled out in our patient since she did not show any other clinical finding characteristic of this syndrome. The diagnosis of MEN 1 can also be ruled out in the absence of any endocrinological disorder.

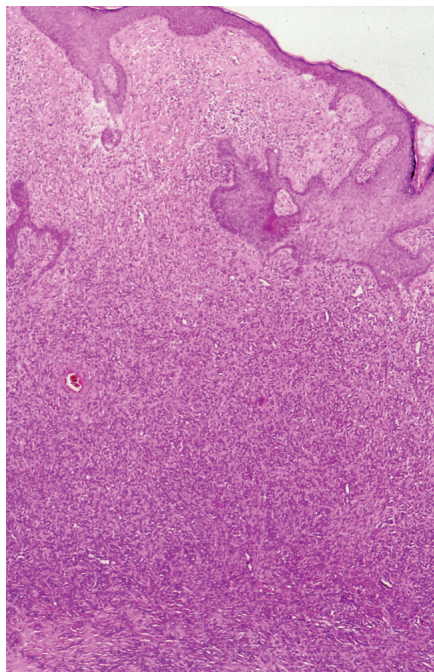


Fig. 2. Biopsies of lesions located on the trunk and limbs demonstrate their fibrohistiocytic nature. (H&E $\times 20$).

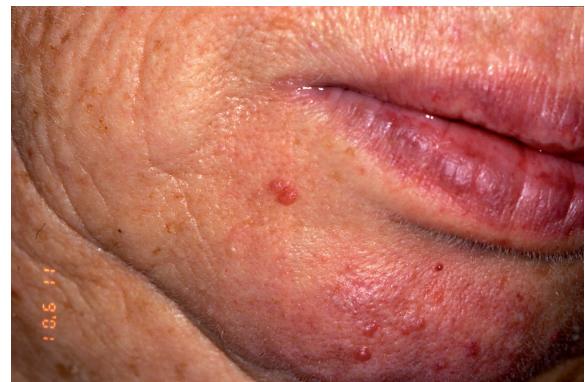

Fig. 3. Small papules on the patient's chin.

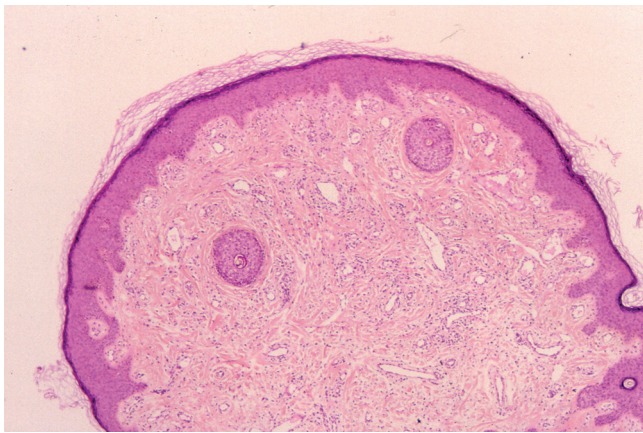


Fig. 4. Histological studies of facial lesions revealed dermal fibrosis and vascular dilatation and proliferation. (H&E×10).

TAR syndrome is characterized by the association of bilateral radial aplasia and thrombocytopenia. Other disorders that show phocomelia, such as exposure during pregnancy to teratogenic agents such as thalidomide and valproic acid, must be considered in the differential diagnosis. Clinical data allow us to rule out these disorders: thumbs are present bilaterally in TAR syndrome, but they are absent in cases provoked by thalidomide ingestion. Phocomelia is bilateral and distal in TAR syndrome and unilateral and proximal in cases secondary to valproic acid ingestion. Chromosome analyses put aside other syndromes that can associate phocomelia and thrombocytopenia, such as Roberts'-SC-phocomelia syndrome, DK-phocomelia syndrome, 18 trisomy and X-linked amelia. In addition, all these syndromes show specific clinical findings that differ from TAR syndrome (5). Our case, and previously reported ones, suggest an autosomal recessive inheritance of TAR syndrome.

Cutaneous lesions reported in association with TAR syndrome include vascular lesions (haemangiomas, naevus flammeus), spotty alopecia, redundant nuchal skin folds and hyperhidrosis (4). To our knowledge, the association of TAR syndrome with progressive nodular histiocytoma or angiofibromas has not been reported previously.

Our insufficient understanding of the aetiology and pathogenesis of these disorders does not allow us to interpret the association either as casual or as a sign of a common defect. In any case, the fact that these entities are very infrequent suggests that their coincidence is not

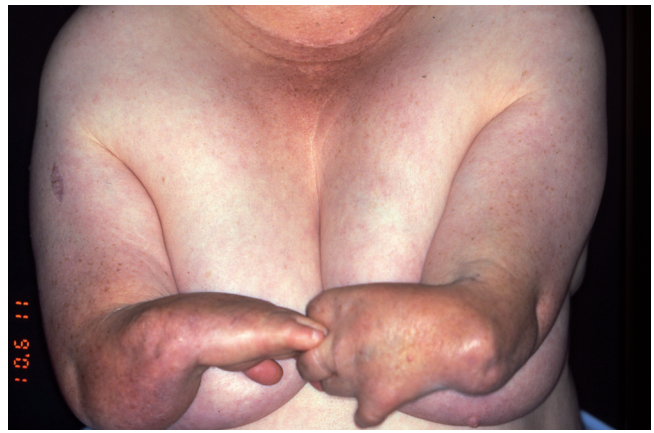


Fig. 5. Congenital phocomelia.

due to chance. The association of TAR syndrome with different types of cancer has been reported previously (5–6) supporting the idea that there is an increased risk of neoplasia in this condition.

REFERENCES

1. Tauton D, Yeshurun D, Jarratt M. Progressive nodular histiocytoma. *Arch Dermatol* 1978; 114: 1505–1508.
2. Darling TN, Skarulis MC, Steinberg SM, Marx SJ, Spiegel AM, Turner M. Multiple facial angiofibromas and collagenomas in patients with multiple endocrine neoplasia type 1. *Arch Dermatol* 1997; 133: 853–857.
3. Gross H, Groh C, Weippl G. Kongenitale hypoplastische thrombopenie mit radius-aplasia, ein syndrome multipler abartungen. *Neue Osterr Z Kinderheilkd* 1956; 1: 574–582.
4. Hedberg VA, Lipton JM. Thrombocytopenia with absent radii. A review of 100 cases. *Am J Pediatr Hematol Oncol* 1988; 10: 51–64.
5. Sanchis A, Beltran M Valverde C, Escriva A, Urioste M. Síndrome TAR (trombocitopenia y aplasia radial). *An Esp Pediatr* 1994; 41: 415–418.
6. Symonds RP, Clark BJ, George WD, Bryant PE, Lin N, Connor JM. Thrombocytopenia with absent radii (TAR) syndrome: a new increased cellular radiosensitivity syndrome. *Clin Oncol (R Coll Radiol)* 1995; 7: 56–58.
7. Camitta BM, Rock A. Acute lymphoidic leukaemia in a patient with thrombocytopenia/absent radii (TAR) syndrome. *Am J Pediatr Hematol Oncol* 1993; 15: 335–337.
8. Gianotti F, Caputo R. Histiocytic syndromes: a review. *J Am Acad Dermatol* 1985; 13: 383–404.
9. Bork K, Hoede N. Hereditary progressive mucinous histiocytosis in women: report of three members in a family. *Arch Dermatol* 1988; 124: 1225–1229.