

Vegetating Darier's Disease During Pregnancy

Daniel de la Rosa Carrillo

Department of Dermatology, Ullevaal University Hospital, Oslo, Norway. E-mail: Daniel.de.la.Rosa-Carrillo@rikshospitalet.no

Accepted December 12, 2005

Sir,

Darier's disease is an autosomal dominant disorder characterized by hyperkeratotic, crusted papules. Nails and mucous membranes may also be involved. Histological examination shows suprabasal acantholysis and overlying dyskeratosis (1, 2). Both exacerbation and improvement of the disease during pregnancy have been described previously, as have bacterial and viral secondary infections. We present here a patient with exacerbation of Darier's disease during pregnancy in a pattern that has not been described previously.

CASE REPORT

A 37-year-old woman, para 1, gravida 2, 5 months pregnant, with a known history of Darier's disease since childhood, with intertriginous involvement, had been treated several times for pyoderma. She had been receiving oral acitretin treatment for many years, but this was discontinued 10 years previously, because she wanted children.

The patient presented with a rapidly spreading eruption with rubor and exudative crusted swelling on her left cheek and left thumb that had commenced 3 days earlier. She also presented slightly hyperkeratotic and maculous skin lesions on her neck, abdomen and legs. She gradually developed retroauricular swelling and adenopathy. There was no fever, but the patient was nauseous. She was not taking any medication at that time.

The case was first diagnosed as Darier's disease with secondary bacterial or herpes simplex infection. She was admitted to our department, where blood tests showed leukocytosis $13.5 \times 10^9/l$ and neutrophilia $9.5 \times 10\%$, with slightly raised C-reactive protein (9.5 mg/l). Treatment with oral cloxacillin 500 mg 4 times daily was started. She was also treated with topical acyclovir on her cheek and thumb and fusidic acid on the rest of the lesions. Despite this treatment, the left retroauricular area became more swollen and she developed swelling, crusting and exudation from both external ear ducts. Treatment with topical triamcinolone-cloxiquin cream and hydrocortisone-oxytetracycline ear drops was then started.

Bacterial swabs from the left cheek showed white staphylococcus and proteus species. Bacterial swabs from her left thumb showed white staphylococcus and beta-haemolytic streptococcus group B. Viral swabs and polymerase chain reaction (PCR) for herpes simplex and varicella zoster from both locations were negative. Ultrasound of the left retroauricular area showed multiple adenopathies and no abscess formation.

The condition worsened as she developed vesicular lesions on the dorsal aspects of her feet and hands, while the lesions on her abdomen and hands became nodular, hyperkeratotic and exudative, giving a vegetating appearance (Fig. 1).

Biopsy from the abdomen showed chronic lichenified dermatitis with subepithelial vascular proliferation. Biopsy from the foot showed acantholysis but not dyskeratosis. Direct immunofluorescence of the skin was negative.

The patient received treatment with topical hydrocortisone with fusidic acid on her cheek, and potassium permanganate 5% and clobetasol propionate 0.05% cream on the other lesions.

She was discharged after 4 weeks. During that period she experienced improvement in the lesions on her abdomen, thumb, ears and feet. There was complete clearance of the lesion on her cheek after 4 weeks. She continued topical treatment with clobetasol propionate 0.05% cream on the lesions on the abdomen and thumb until clearance one month after discharge.

DISCUSSION

The condition was considered to be an exacerbation of Darier's disease during pregnancy, with concurrent bacterial infection and bilateral external otitis. Repetitive tests for virus, and especially herpes simplex and varicella zoster, were all negative. Clinical differential diagnoses were pemphigus vegetans of Hallopeau or pyogenic granuloma, but the negative direct immunofluorescence with acantholysis on histopathological examination, as well as the presence of multiple vegetating lesions, excluded both (1, 2).

Improvement of Darier's disease during pregnancy or when taking oral contraceptive agents has already been described (3). One case report has also been published about a 58-year-old woman who experienced exacerbation of Darier's disease during each of her six pregnancies (4). There are other publications on exacerbation of Darier's disease due to herpes or vaccinia

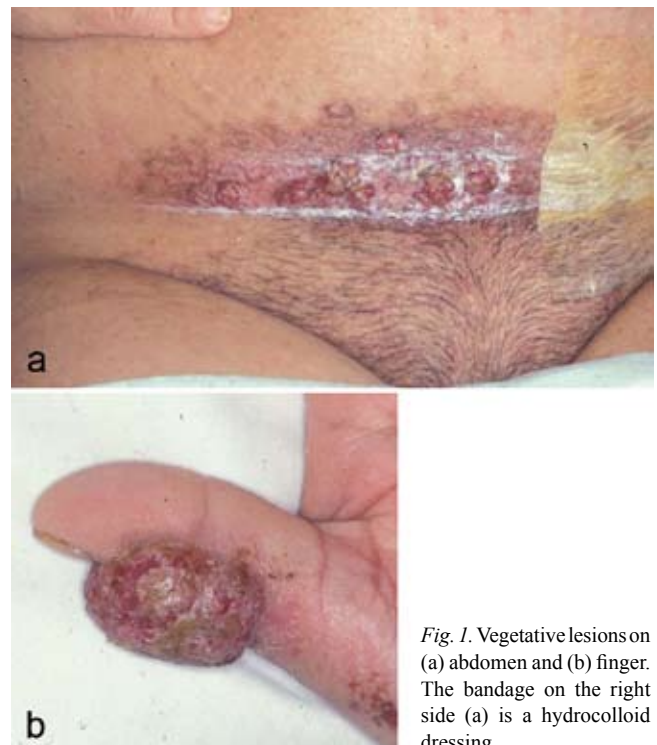


Fig. 1. Vegetative lesions on (a) abdomen and (b) finger. The bandage on the right side (a) is a hydrocolloid dressing.

virus skin infection during pregnancy (5, 6). In one of these patients, some of the lesions had coalesced to give a verrucous appearance (6). However, there are no published cases of exacerbation of Darier's disease with vegetating lesions during pregnancy without any secondary viral infection.

ACKNOWLEDGEMENT

I thank Dr Cato Mørk for his advice and invaluable help in writing this article.

REFERENCES

1. Judge MR, McLean WHI, Munro CS. Darier's disease and related disorders. In: Burns T, Breathnach S, Cox N, Griffiths C, eds. *Rook's textbook of dermatology*, 7th edition, volume two. Massachusetts, Oxford, Victoria: Blackwell Science, 2004: 34.69–34.71.
2. Goldsmith LA, Baden HP. Darier-white disease (Keratosis Follicularis) and acrokeratosis verruciformis. In: Freedberg IM, Eisen AZ, Wolff K, Austen KF, Goldsmith LA, Katz SI, Fitzpatrick TB. *Fitzpatrick's dermatology in general medicine*, 5th edition. USA: McGraw-Hill, 1999: 614–619.
3. Espy PD, Stone S, Jolly HW, Jr. Hormonal dependency in Darier disease. *Cutis* 1976; 17: 315–320.
4. Spouge JD, Trott JR, Chesko G. Darier-White's disease: a cause of white lesions of the mucosa. Report of four cases. *Oral Surg Oral Med Oral Pathol* 1966; 21: 441–457.
5. Toole JWP, Hofstader SL, Ramsay CA. Darier's disease and Kaposi's varicelliform eruption. *J Am Acad Dermatol* 1979; 1: 321–324.
6. Carney JF, Caroline NL, Nankervis GA, Pomeranz JR. Eczema vaccinatum and eczema herpeticum in Darier disease. *Arch Dermatol* 1973; 107: 613–614.