

Enhanced Expression of p53 Protein in Pityriasis Rubra Pilaris

Wojciech Baran, Jacek C. Szepietowski and Grazyna Szybejko-Machaj

Department of Dermatology, Venereology and Allergology, Wrocław Medical University, ul. Chalubinskiego 1, PL-50-368, Wrocław, Poland. E-mail:

jszepiet@derm.am.wroc.pl

Accepted January 18, 2006.

Sir,

p53 is a phosphoprotein, known since 1992 as a “guardian” of the genome (1, 2). A mutation in the p53 gene coding this protein, which activation protects the organism from tumourigenesis, has been found in more than half of all human tumour types (3). DNA damaging agents induce p53 protein activity, which leads to cell cycle arrest in the G1 or G2 phase and, in the case of ineffective DNA repair, apoptosis is initiated (4). p53 immunoreactivity has also been found in non-tumourigenic inflammatory skin diseases, e.g. psoriasis, chronic dermatitis, lupus erythematosus and lichen planus (5), often with controversial results. p53 is also detectable in normal skin, using various methods of antigen retrievals, especially after ultraviolet (UV) exposure, but at very low levels (6).

Pityriasis rubra pilaris (PRP) is a rare hyperkeratotic, papulo-squamous skin disorder with unknown aetiology. Although the first case was described in 1828, until now the pathogenesis of this rare disorder is still a matter for debate. A few possible mechanisms are considered: abnormal vitamin A metabolism in the skin, association with internal malignancies, immune system dysregulation (PRP often appears simultaneously with autoimmune diseases) and associations with infections, particularly human immunodeficiency virus. Hereditary forms of PRP are very rare (7, 8). Experimental studies showed that epidermal cells in PRP lesions have increased labelling index compared with normal skin keratinocytes, similarly to findings in psoriatic skin (9, 10). PRP presents with some histological features simi-

lar to psoriasis, especially hyperkeratosis, parakeratosis and acanthosis (7, 8, 11), which could result from cell cycle disturbances in the keratinocytes.

The present study was undertaken to evaluate expression of p53 protein in the lesional skin of patients with type I classic PRP (confirmed by histological examination).

PATIENTS AND METHODS

Skin biopsies were collected under local anaesthesia from 7 patients (3 women and 4 men). None of the patients had been exposed to UV treatment within at least 6 months. Skin samples were also taken from 10 healthy volunteers (5 women and 5 men) with no personal and family history of skin disorders (control group). The study was approved by the Commission of Bioethics at Wrocław Medical University (KB 245/2004).

The expression of p53 protein was demonstrated using the avidin–biotin complex immunoperoxidase method and monoclonal antibody DO7 (Monoclonal Mouse Anti-Human p53 Protein, Clone DO7, DakoCytomation, Glostrup, Denmark, code M7001) recognizing both wild-type and mutant-type p53 proteins. Negative controls were provided by performing standard procedure excepting incubation with the primary antibody. A sample of oesophageal carcinoma strongly positive for p53 was used as a positive control. The positive keratinocyte nuclei count (10 fields for each slide, $\times 400$) and percentage of keratinocytes with stained nuclei (5 fields for each slide, 1 field ≈ 100 cells) was estimated using a Nikon Eclipse E600 light microscope. The examiner was not informed to which group the specimen belonged. Only cells with nuclear staining were taken into consideration. Statistical analysis of the results was done using the Mann-Whitney U test, $p < 0.05$ was considered statistically significant.

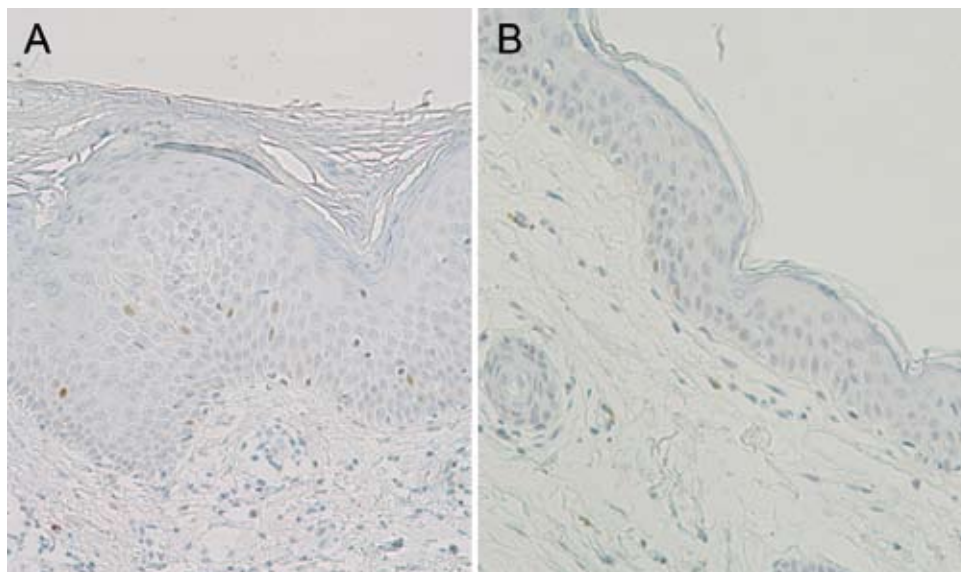


Fig. 1. p53 immunoreactivity in (A) pityriasis rubra pilaris lesional skin and (B) healthy control (original magnification $\times 200$).

RESULTS

Immunoreactivity for p53 was seen only in the nuclei of the epidermal cells, no stained cells were observed in the dermis. p53 reactivity was observed almost in all samples, only two normal skin specimens were negative. p53-positive cells showed various staining intensity, but negative ones were easily distinguishable from them (Fig. 1). Mean count of p53 positive cells in PRP skin (14.7 ± 12.8) was significantly higher ($p = 0.02$) than in control group (4.0 ± 6.3). Similarly, the average percentage of p53 positive keratinocytes was higher ($p < 0.01$) in lesional skin ($10.11\% \pm 8.62$) compared with biopsy taken from healthy volunteers ($2.44\% \pm 3.55$). The age of the patients, clinical type of PRP and duration of illness related poorly with the number and percentage of p53 positive cells (data not shown).

DISCUSSION

It is likely that increased expression of p53 in PRP skin is a physiological reaction of p53 trying to protect keratinocytes against increased proliferation, which could lead to the development of errors in DNA structure. DO7 monoclonal antibody detects both wild-type and mutated form of the p53 protein and it is obvious that other factors, not only mutation, may account for the accumulation of this protein. Our results, demonstrating for the first time enhanced p53 expression in lesional skin of patients with PRP, may suggest that the cell cycle is disturbed in PRP epidermis. However,

further studies are required to completely determine the molecular basis of the cell cycle regulations in the epidermal cells, which will broaden our knowledge of the pathogenesis of this rare disease.

REFERENCES

1. Lane DP. Cancer. p53, guardian of the genome. *Nature* 1992; 358: 15–16.
2. Ro YS, Cooper PN, Lee JA, Quinn AG, Harrison D, Lane D, et al. P53 protein expression in benign and malignant skin tumours. *Br J Dermatol* 1993; 128: 237–241.
3. Harris CC, Hollstein M. Clinical implications of the p53 tumor-suppressor gene. *N Engl J Med* 1993; 329: 1318–1327.
4. Hainaut P, Hollstein M. p53 and human cancer: the first ten thousand mutations. *Adv Cancer Res* 2000; 77: 81–137.
5. Batinac T, Gruber F, Lipozencic J, Zamolo-Koncar G, Stasic A, Brajac I. Protein p53 – structure, function, and possible therapeutic implications. *Acta Dermatovenerol Croat* 2003; 11: 225–230.
6. Hall PA, McKee PH, Menage H, Dover R, Lane DP. High levels of p53 protein in UV-irradiated normal skin. *Oncogene* 1993; 8: 203–207.
7. Albert MR, Mackool BT. Pityriasis rubra pilaris. *Int J Dermatol* 1999; 38: 1–11.
8. Chan H, Liu FT, Naguwa S. A review of pityriasis rubra pilaris and rheumatologic associations. *Clin Dev Immunol* 2004; 11: 57–60.
9. Ralfs IG, Dawber RPR, Ryan TJ, Wright NA. Pityriasis rubra pilaris – epidermal cell kinetics. *Br J Dermatol* 1981; 104: 249–252.
10. Griffiths WAD, Pieris S. Pityriasis rubra pilaris – an autoradiographic study. *Br J Dermatol* 1982; 107: 665–667.
11. Artik S, Megahed M, Ruzicka T. Pityriasis rubra pilaris. Case reports and review of the literature. *Hautarzt* 2003; 54: 858–863.