

## Persistent Painful Indurated Erythema Secondary to Bosentan

Fernando Gallardo<sup>1</sup>, Ayoze Gil<sup>2</sup>, Josep Comín<sup>2</sup>, Lluís Molina<sup>2</sup>, Mar Iglesias<sup>3</sup> and Ramon M. Pujol<sup>1</sup>

Departments of <sup>1</sup>Dermatology, <sup>2</sup>Cardiology and <sup>3</sup>Pathology, Hospital del Mar, Passeig Marítim 25-29, ES-08003 Barcelona, Spain. E-mail: Fgallargo@imas.imim.es

Accepted October 5, 2005.

Sir,

Bosentan is an orally active antagonist of endothelin-1 (ET-1), an endogenous peptide considered one of the most potent and long-standing endogenous vasoconstrictors (1). Bosentan has been recently approved by the FDA for treatment of pulmonary arterial hypertension (PAH) (2, 3). This drug has been proven to show some clinical benefit for the ET-1 related disorders (1). Cutaneous side-effects secondary to bosentan have rarely been reported (4, 5). We herein describe a case developing an uncommon cutaneous reaction manifested by a generalized persistent painful indurated erythema secondary to bosentan treatment.

### CASE REPORT

A 42-year-old woman with surgically corrected tetralogy of Fallot was admitted to the Department of Cardiology with suspicion of right ventricular failure secondary to PAH. Two months before the admission and 1 month after the onset of treatment with bosentan, (Tracleer<sup>®</sup>, Actelion, Allschwil, Switzerland) 62.5 mg twice a day, she presented with an intense pain mainly involving the proximal aspects of both legs. The patient described it as a stabbing or burning sensation which prevented her from sleeping. One week later, she presented with progressive weight gain associated with a non-evanescent patchy erythema with coalescent non-pitting indurated oedematous plaques involving the trunk, face and extremities (Fig. 1). No fever, malaise or other systemic symptoms were observed. No mucosal involvement was present.

A cutaneous biopsy specimen was performed from an indurated area. Histopathological examination disclosed a barely detectable dilatation of thin-walled vessels in the superficial, mid and deep dermis. A discrete peri-

vascular lymphocytic infiltrate involving the papillary and upper reticular dermis was also present. Neither vascular damage, epidermal changes nor subcutaneous tissue involvement were noted. No increased numbers of eosinophils or neutrophils were observed (Fig. 2).

Physical examination did not show signs of right heart failure and a chest X-ray film and a heart ultrasound ruled out the presence of signs of right ventricular dysfunction. Diuretic treatment was prescribed, but a progression in weight gain and cutaneous oedema was noted. After withdrawal of bosentan treatment, a progressive and spontaneous resolution of pain was noted in the following days. Skin induration slowly resolved within 3–4 weeks and cutaneous erythema progressively subsided during the following 3 months until a total remission. Prick test and patch test with bosentan in petrolatum at different dilutions were performed. Both patch and prick tests gave negative results.

### DISCUSSION

Bosentan, an oral ET-1 antagonist, has shown clinical benefit for patients with PAH with positive impact on pulmonary haemodynamics (reduction of pulmonary vascular resistance and right ventricular hypertrophy) and pulmonary fibrosis (2, 3). In addition, an effect on digital ulcerations in patients with progressive systemic scleroderma complicated with PAH has been reported following treatment with bosentan (6). Recently, the usefulness of this drug in the treatment of aggressive Raynaud's phenomenon has also been reported (7).

In clinical trials, several side-effects secondary to bosentan treatment including headache (15%), flushing (6%), leg oedema (5%), nasal congestion, hypotension, palpitations and worsening of symptoms in chronic

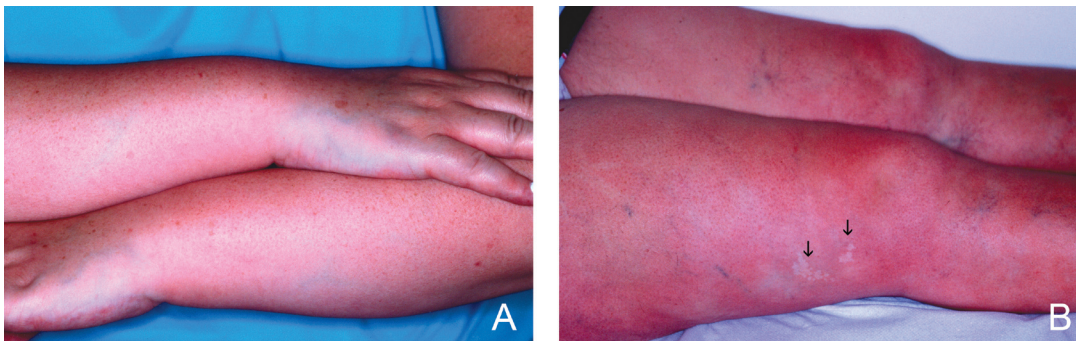


Fig. 1. (A) Generalized erythematous persistent rash on lower arms and hands. (B) A pale, whitish irregular patch consistent with a naevus anemicus can be observed on the thigh (arrows).

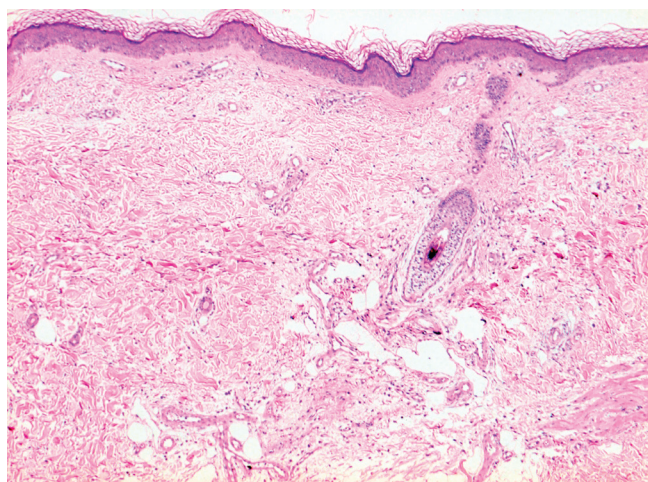


Fig. 2. Vascular ectasia in the superficial, mid and deep dermis (haematoxylin-eosin  $\times 200$ ).

heart failure patients have been described. An increased incidence of fluid retention during the first weeks of treatment (manifested by early weight gain, decrease in haemoglobin and relative haemodilution) has also been noted. These vasodilatory direct effects are dose-limiting and are rather similar to those reported secondary to other potent vasodilators (5).

Cutaneous side-effects secondary to bosentan treatment have rarely been reported. Isolated descriptions of generalized pruritus, urticaria or leukocytoclastic vasculitis have been reported (8). In 2004, Myers et al. (4) published a series of 100 patients receiving long-term prostacyclin and/or bosentan treatment for PAH, and described the cutaneous side-effects observed in 12 patients. Eight patients presented persistent generalized blanching erythema, and intense accompanying pain was reported in 5 of these. Other cutaneous findings reported in that series were palpable purpura or brawny discoloration consistent with leg dermatitis. The authors considered prostacyclin as the unique responsible drug for this peculiar persistent rash different to flushing.

Persistent painful indurated erythema could be a peculiar and uncommon side-effect secondary to potent vasodilatory drugs that has received little attention in the literature. A direct vasodilator effect could be incriminated as the underlying pathogenetic mechanism but it does not explain the presence of accompanying disabling painful symptoms. The differential diagnosis of bosentan-induced indurated erythema should include

generalized oedema, scleredema, localized or systemic scleroderma, scleromyxedema and nephrogenic fibrosing dermopathy. However, in our case, the direct relationship with the onset of bosentan treatment, the absence of systemic associated symptoms and the progressive resolution after withdrawal of the responsible drug permits exclusion of these diagnoses.

In conclusion, the development of a persistent, intensely painful, indurated erythema can be observed in patients following treatment with bosentan. This uncommon, rarely described phenomenon seems to be secondary to a persistent vasodilatation induced by ET-1 antagonist drugs.

## REFERENCES

1. Mayes M. Endothelin and endothelin receptor antagonists in systemic rheumatic disease. *Arthritis Rheum* 2003; 48: 1190–1199.
2. Sitbon O, Badesch D, Channick R, Frost A, Robbins I, Simonneau G, et al. Effects of the dual endothelin receptor antagonist bosentan in patients with pulmonary arterial hypertension. *Chest* 2003; 124: 247–254.
3. Hachulla E, Coghlan JG. A new era in the management of pulmonary arterial hypertension related to scleroderma: endothelin receptor antagonism. *Ann Rheum Dis* 2004; 63: 1009–1014.
4. Myers S, Ahearn G, Selim A, Tapson V. Cutaneous findings in patients with pulmonary arterial hypertension receiving long-term epoprostenol therapy. *J Am Acad Dermatol* 2004; 51: 98–102.
5. Placebo-controlled studies of bosentan: BC-15064 (severe congestive heart failure), BD-14884 (intra-venous study in pulmonary arterial hypertension), NC-15018 (severe congestive heart failure), NC-15020 (essential hypertension), NC-15462 (REACH-1, severe congestive heart failure), NN-15031 (subarachnoid haemorrhage), AC-052-351 (pulmonary arterial hypertension), AC-052-352 (pulmonary arterial hypertension). (Accessed 2004). Available from the manufacturer, Actelion Pharmaceuticals, Allschwil, Switzerland: [www.fda.gov/ohrms/dockets/ac/01/slides/3775s2\\_01\\_actelion.ppt](http://www.fda.gov/ohrms/dockets/ac/01/slides/3775s2_01_actelion.ppt)
6. Korn JH, Mayes M, Matucci Cerinic M, Rainisio M, Pope J, Hachulla E, et al. Digital ulcers in systemic sclerosis: prevention by treatment with bosentan, an oral endothelin receptor antagonist. *Arthritis Rheum* 2004; 50: 3985–3993.
7. Ramon-Casals M, Brito-Zeron P, Nadi N, Claver G, Risco G, Parraga FD, et al. Successful treatment of severe Raynaud's phenomenon with bosentan in four patients with systemic sclerosis. *Rheumatology (Oxford)* 2004; 43: 1454–1456.
8. Gasser S, Kuhn M, Speich R. Severe necrotising leukocytoclastic vasculitis in a patient taking bosentan. *BMJ* 2004; 329: 430.