

## Lymphangiectasias After Penectomy, Inguinal Lymph Node Dissection, Urethrostomy and Radiation

Shyam B. Verma

B3, CS Patel Enclave, 3 Pratapgunj, Baroda. 390 002, India. E-mail: vermaderma@rediffmail.com

Accepted September 26, 2005.

Sir,

Lymphangiectasias on the genitals can frequently mimic condylomas, warts and molluscum contagiosum. They are also reported after various operative procedures and certain other conditions where fibrosis and obstruction of lymphatics has occurred. A case of lymphangiectasias following radical surgery for penile squamous cell carcinoma is reported here.

### CASE REPORT

A 35-year-old man reported to this clinic with small dome-shaped lesions on his scrotum and upper medial thighs that had been present for one year. There was no itching or pain. He complained of an occasional discharge of a clear fluid when the lesions were subjected to friction from excessive walking. The man had undergone a total penectomy with perineal urethrostomy and bilateral ileoinguinal lymphadenectomy with radiation and chemotherapy for carcinoma of the penis 18 months previously.

The patient had visited two local dermatologists who had diagnosed the lesions as warts and molluscum contagiosum. One had applied podophyllin to his lesions, which did not help and resulted in severe irritant dermatitis. The other dermatologist suggested electrocautery of the lesions, which the patient refused.

On examination there were multiple whitish looking excrescences over the base of the scrotum and a few scattered on the left upper medial thigh (Fig. 1). They were not tender and oozed a milky liquid upon pressing between the index finger and thumb. Some appeared warty but upon closer inspection did not resemble verrucae or condyloma acuminata. The skin in that area was macerated due to the opening of the perineal urethrostomy. The oncosurgeon on two occasions thought that the patient had some form of incontinence, but upon close ex-

amination it turned out to be the fluid leaking from the macerated lesions that was mistaken for urine.

A punch biopsy of the lesion showed grouped ectatic lymphatics located in the papillary dermis. The ectatic vessels were thin-walled and showed endothelial lining. They contained eosinophilic proteinaceous lymph (Fig. 2).

Based on the clinical and histopathological findings a diagnosis of multiple lymphangiectasias following total penectomy with perineal urethrostomy and bilateral ileoinguinal lymphadenectomy was made. The patient was given an option of removing them by electrosurgery or cryosurgery, which he refused.

### DISCUSSION

Lymphangiectasias are sustained dilatations of otherwise normal surface lymphatic channels (1). They are not neoplasms or true hamartomas like lymphangiomas. Lymphangiectasias occur due to fibrosis of the surrounding connective tissue, which causes back-pressure and dermal back-flow (1). Lymphangiectasias are reported on vulva and upper thighs in women after major surgery for breast cancer and cervical cancer (2, 5). There are also scattered reports of scrotal lymphangiectasias. Lymphangiectasias have been known to occur after recurrent infections, radiotherapy, scrofuloderma and repeated trauma (1, 6, 7). Cutaneous lymphangiectasias can mimic warts, condyloma acuminata and molluscum contagiosum as they did in this case (1, 3). They can also become a portal of entry for infections. The lymph oozing from these lesions can be mistaken for incontinence, as occurred in this case. Also the perineal

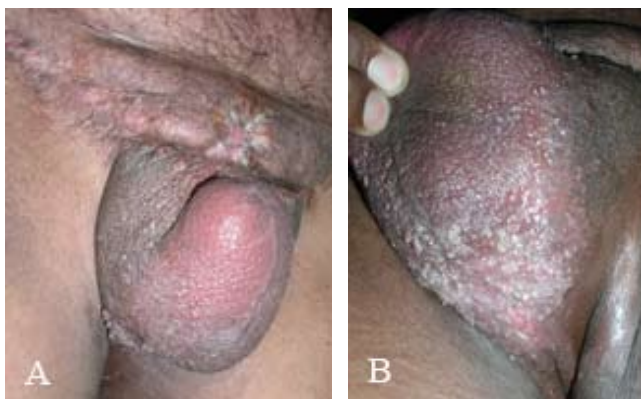

Fig. 1. Total penectomy with scar of ileoinguinal lymphadenectomy and lymphangiectasias on the base and lateral aspect of the scrotum (right side) (A). Close-up of skin with coloured-to-whitish lesions of lymphangiectasias (left side) (B).

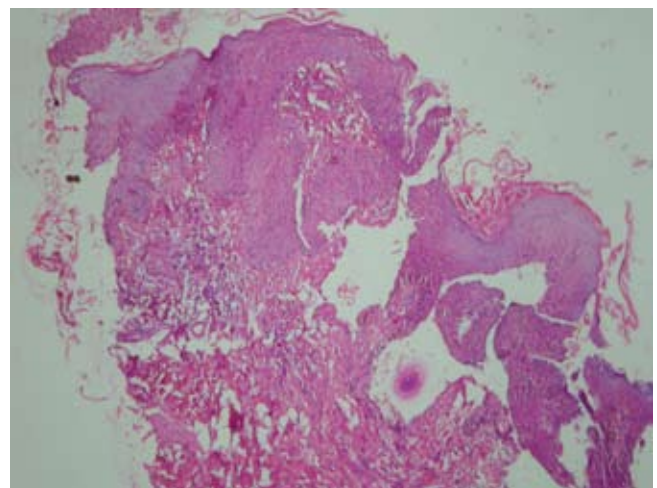


Fig. 2. Ectatic lymph vessels in the upper dermis, with lymph in the centre of the lesion.

urethrostomy and local wetness after micturition may have been an additional cause of maceration in this case. A Medline search reveals this to be the first case of lymphangiectasias reported following total penectomy with bilateral perineal urethrostomy and bilateral ileoinguinal lymphadenectomy. This radical surgery would have lead to a massive fibrosis resulting in obstruction of lymphatics and dermal lymphatic back-flow causing the lymphangiectasias. The radiation therapy would have been another contributing factor. An innocuous but effective treatment, such as a compression bandage, would not be possible in this case due to the location. Other treatment modalities include surgical removal, electrosurgery, laser removal and cryosurgery, all of which the patient refused.

Lymphangiectasias occurring on the genitalia can cause diagnostic confusion and should be included in the list of non-venereal genital lesions.

## REFERENCES

1. Mortimer PS. Disorders of lymphatic vessels. In: Burns T, Breathnach T, Cox N, Griffiths C, eds. *Rook's textbook of dermatology*, 7th edn, vol. 3. Oxford: Blackwell Science, 2004: 51: 25–26.
2. Ambrojo P, Cogolludo EF, Aguilar A, Sanchez Yus E, Sanchez de Paz F. Cutaneous lymphangiectases after therapy for carcinoma of the cervix – a case with unusual clinical and histological findings. *Clin Exp Dermatol* 1990; 15: 57–59.
3. Harwood CA, Mortimer PS. Acquired vulval lymphangiomas mimicking genital warts. *Br J Dermatol* 1993; 129: 334–336.
4. Kaya TI, Kokturk A, Polat A, Tursen U, Ikizoglu G. A case of cutaneous lymphangiectasis secondary to breast cancer treatment. *Int J Dermatol* 2001; 40: 760–762.
5. Bouzit N, Grezard P, Communal PH, Mironneau I, Balme B, Perrot H. Cutaneous lymphangiectasias acquired after surgical and radiotherapy treatment of breast cancer. Two cases. *J Gynecol Obstet Biol Reprod (Paris)* 1999; 28: 384–387.
6. Pena JM, Ford MJ. Cutaneous lymphangiectases associated with severe photoaging and topical corticosteroid application. *J Cutan Pathol* 1996; 23: 175–181
7. DiLeonardo M, Jacoby RA. Acquired cutaneous lymphangiectasias secondary to scarring from scrofuloderma. *J Am Acad Dermatol* 1986; 14: 688–690.