

Cutaneous Cryptococcosis in an Immunocompetent Host

Sayuri Yuge¹, Ivander Bastazini Júnior¹, Maria Carolina Melo Coelho¹ and Cleverson Teixeira Soares²

Departments of ¹Dermatology and ²Pathology, Lauro de Souza Lima, Institute, Rodovia Cte, João Ribeiro de Barros km 225/226, Bairro Aimorés, Bauru, São Paulo, Brazil. E-mail: sayuriyuge@bol.com.br

Accepted September 5, 2005.

Sir,

Cryptococcosis is an opportunistic infection that usually affects immunocompromised hosts (1). It is caused by the opportunistic yeast *Cryptococcus neoformans*, which is present in the environment worldwide (e.g. pigeon droppings, vegetables, soil) (1, 2). Four serotypes have been identified: A (*var. rubii*), D (*var. neoformans*) and B, C (*var. gatii*) (2, 3). We present a case of an immunocompetent patient with cutaneous cryptococcosis without clinical or laboratory evidence of dissemination.

CASE REPORT

A 75-year-old housewife, from an urban area of Brazil, presented with a 7-month history of a non-tender plaque on her right forearm. She received antibiotics for presumed bacterial cellulites without improvement. The patient was otherwise healthy. She denied any history of previous relevant trauma, although she reported daily exposure to soil and wood debris (gardening) and also easy disruption of sun-exposed areas of skin after minor trauma.

Examination revealed erythematous, smooth and firm plaque on her right forearm, size 15×4 cm (Fig. 1). Sun-exposed skin showed solar elastosis, Bateman's purpura and stellate scars particularly of the dorsal forearms and hands. There was no lymphadenopathy. Her entire physical examination was unremarkable. A biopsy specimen from the lesion showed dermal infiltrate organized in a granulomatous pattern. Numerous rounded bodies surrounded by a refractile gelatinous capsule were found scattered throughout the involved skin. Yeast cells stained with mucicarmine, periodic

acid-Schiff and methanamine-silver (Fig. 2). Skin culture grew *C. neoformans*. Complete blood count, biochemical panel, immunoglobulins, CD4/CD8 cell counts and chest radiograph were normal. Culture and antigen latex agglutination test of blood and urine were negative. Lumbar puncture was unnecessary because the patient was without clinical or laboratory findings to suggest dissemination. Human immunodeficiency virus (HIV), hepatitis B and C serologies were negative. She was treated with fluconazole 400 mg/day for 3 months with minimal improvement. After a 3-month cycle of amphotericin B 50 mg 3 times a week (total dose: 2250 mg) healing was obtained. Nevertheless, amphotericin B was discontinued as signs of renal injury were detected. Subsequently itraconazole 200 mg/day for 6 months was given and clinical remission was achieved.

DISCUSSION

A clinical diagnosis of cutaneous cryptococcosis is difficult to make due to lack of pathognomonic skin lesion (2, 3). It can simulate bacterial cellulitis (4, 5), discoid lupus erythematosus (6), molluscum contagiosum (7), herpes (8) and other diseases. Although the most described lesions are nodule, ulcer and whitlow (2, 3).

Cutaneous cryptococcosis is mostly attributed to inhalation of *Cryptococcus* spores and later haematogenous dissemination (i.e. secondary cutaneous cryptococcosis), nevertheless some authors suggest the possibility of cutaneous inoculation (i.e. primary cutaneous cryptococcosis (PCC)) (1–4). In our patient the portal of entry was not defined and a lung infection that spontaneously cleared cannot be ruled out.

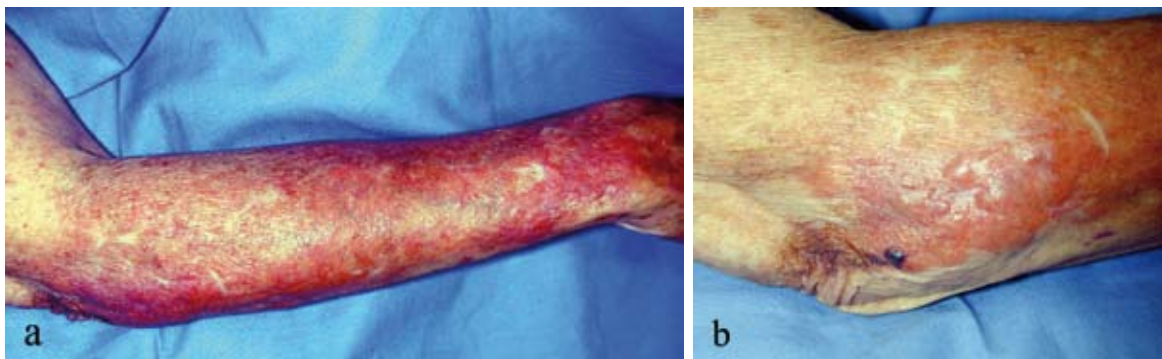


Fig. 1. Cutaneous cryptococcosis. Large erythematous plaque with poorly defined borders on right forearm (a). Close-up of elbow (b).

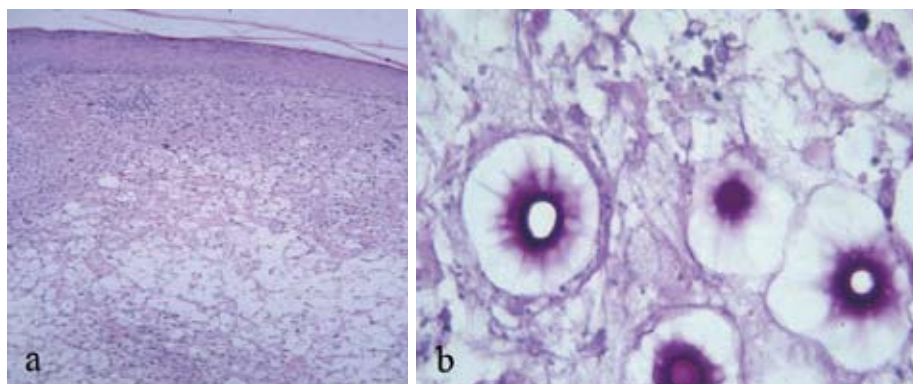


Fig. 2. Skin biopsy showing extensive dermal infiltration with predominance of vacuolar histiocytes. Hematoxylin-eosin stain, original magnification $\times 40$ (a). Cryptococcus showing a radiated aspect. Periodic acid Schiff stain, original magnification $\times 400$ (b).

The existence of PCC is still controversial (2) and some authors consider it a “sentinel” of cryptococcal systemic infection (4). PCC is defined in the literature by identification of *C. neoformans* in the skin lesion and presence of a chancriform syndrome, without evidence of systemic dissemination (2, 4). However, just a few authors could demonstrate the chancriform syndrome (5), most of them described patients with isolated cutaneous lesion without systemic involvement (6, 7).

The French Cryptococcosis Study Group (2) proposed some additional criteria to distinguish PCC from secondary cutaneous cryptococcosis. They found that PCC occurred frequently in patients from rural area, with solitary skin lesion or lesions confined to a limited body area, particularly on unclothed areas (limbs) and without signs of extracutaneous disease. Furthermore, prior history of trauma, pre-existing skin lesion at the same body site or exposure to pigeon droppings, soil and wood debris are further evidences of PCC. We detected in our patient most of the criteria described above, such as lesions confined to unclothed areas, possible skin injury (activities predisposing to wounds and fragile skin of dorsal forearms), exposure to possible contaminated source (soil and dust), absence of systemic signs or antigen detection and favourable outcome. Association between serotype D of *C. neoformans* and skin lesions has been reported (2), although in our case we could not identify the *Cryptococcus* serotype due to technical limitations.

The treatment of choice for cryptococcosis depends on the anatomical site of involvement and the host’s immune status. The guidelines published by the Infectious Disease Society of America recommended fluconazole 200–400 mg/day for 3–6 months for cutaneous involve-

ment in immunocompetent hosts, nevertheless there are no detailed studies of therapeutic effectiveness. Itracozazole and amphotericin B are acceptable alternatives for patients with more severe disease (9).

REFERENCES

1. Revenga F, Paricio JF, Merino FJ, Nebreda T, Ramírez T, Martínez AM. Primary cutaneous cryptococcosis in an immunocompetent host: case report and review of the literature. *Dermatology* 2002; 204: 145–149.
2. Neuville S, Dromer F, Morin O, Dupont B, Ronin O, Lortholary O. Primary cutaneous cryptococcosis: a distinct clinical entity. *Clin Infect Dis* 2003; 36: 337–347.
3. Christianson JC, William E, Andes D. Primary cutaneous cryptococcosis in immunocompetent and immunocompromised hosts. *Med Mycol* 2003; 41: 177–188.
4. Ng WF, Loo KT. Cutaneous cryptococcosis-primary versus secondary disease: report of two cases and review of the literature. *Am J Dermatopathol* 1993; 15: 372–377.
5. Sanchez-Albisua B, Rodriguez-Peralto JL, Romero G, Alonso X, Vanaclocha F, Iglesias L. Cryptococcal cellulitis in an immunocompetent host. *J Am Acad Dermatol* 1997; 36: 109–112.
6. Miura T, Akiba H, Saito N, Seiji M. Primary cutaneous cryptococcosis. *Dermatologica* 1971; 142: 374–379.
7. Ghigliotti G, Carrega G, Farris A, Burrioni A, Nigro A, Paganò G, DeMarchi R. Cutaneous cryptococcosis resembling molluscum contagiosum in a homosexual man with AIDS. *Acta Derm Venereol* 1992; 72: 182–184.
8. Boerton LK, Wintroub BU. Disseminated cryptococcosis presenting as herpetiform lesions in a homosexual man with acquired immunodeficiency syndrome. *J Am Acad Derm* 1984; 10: 387–390.
9. Saag MS, Graybill RJ, Larsen RA, Pappas PG, Perfect JR, Powderly WG, et al. Practice guidelines for the management of cryptococcal disease. *Clin Infect Dis* 2000; 30: 710–718.