

## Imatinib-induced Erythrodermia in a Patient with Chronic Myeloid Leukemia

Pınar Oztas<sup>1</sup>, Servet Erbası<sup>2</sup>, Nurdan Lenk<sup>1</sup>, Muhterem Polat<sup>1</sup>, Ozge Han<sup>3</sup>, Ferda Artuz<sup>1</sup> and Nuran Allı<sup>1\*</sup>

<sup>1</sup>1st Dermatology Clinic, <sup>2</sup>Hematology Clinic and <sup>3</sup>Pathology Clinic, Ankara Numune Education and Research Hospital, 44. cadde 27/19 Manolya Sitesi, TR-06520 Cukurambar Ankara, Turkey. E-mail: poztas@yahoo.com  
Accepted June 28, 2005.

Sir,

Chronic myeloid leukemia (CML) is a clonal, myeloproliferative disorder which is the first human malignancy to be associated with a specific genetic lesion, the Philadelphia chromosome, that carries the BCR-ABL oncogene (1). Imatinib (Glivec®) is the first molecularly targeted drug developed for CML and it has achieved a remarkable success. Few side effects are reported with imatinib, consisting mainly of haematological side effects such as neutropenia and thrombocytopenia. Non-haematological side effects are moderate oedema, nausea, arthralgias and weight gain. In this paper, we report a patient with CML, who was treated with imatinib and developed erythrodermia.

### CASE REPORT

A 49-year-old woman was referred from the haematology clinic with a widespread erythematous itchy eruption of 7 days duration. She had been diagnosed with CML 2 months earlier. At that time, she was suffering from malaise and dizziness; her white blood count was 133000/ $\mu$ l and her haemoglobin level was 9.34 g/dl.

Imatinib 400 mg/day monotherapy was started and peripheral white blood count decreased to 9300/ $\mu$ l in a 6-week period. No additional therapy was used for CML. Seven days before the dermatology consultation skin lesions started on the trunk and rapidly spread all over with severe pruritus. On dermatological examination a widespread erythema was observed throughout the skin (Fig. 1). The face was also involved, with oedema around the eyelids. Complete blood count, fasting glucose levels, hepatic and renal functions, serum electrolytes, ANA and anti-ds-DNA and urinalysis were normal or negative. An abdominal ultrasound showed hepatosplenomegaly with a hepatic craniocaudal diameter of 16 cm and a splenic diameter of 12 cm. A skin biopsy was taken. Mild orthokeratosis with areas of focal parakeratosis and slight spongiosis was observed in the epidermis that contained focal spongiotic vesiculation (Fig. 2). Superficial dermal infiltrate of lymphocytes and scattered neutrophils and eosinophils with accentuation around the vessels and epidermal appendages was noted and was consistent with a drug eruption.

The imatinib therapy of the patient was stopped and a rapid disappearance of the rash was observed in a few days. When the patient was fully well the haematologists started imatinib therapy with a half dose of 200 mg/day.

Cutaneous lesions reappeared rapidly, and the patient was advised not to use the drug any more. The patient is still under haematology and dermatology follow-up.

### DISCUSSION

Imatinib functions by competitively inhibiting the adenosine triphosphate-binding site of the protein kinase enzyme, leading to the inhibition of tyrosine phosphorylation of proteins involved in BCR-ABL gene without

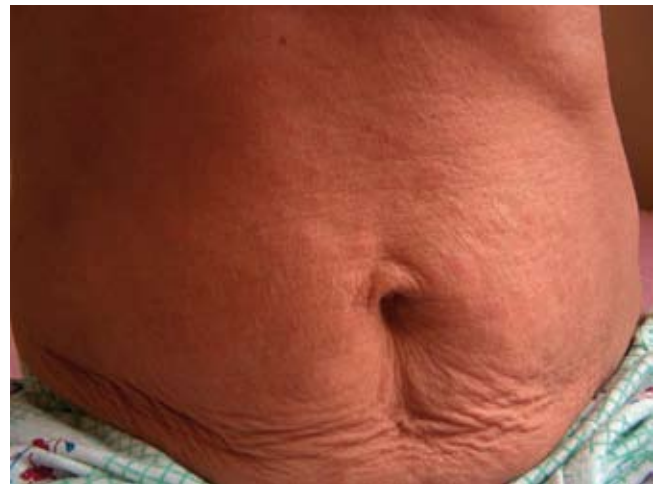

Fig. 1. Abdomen of the patient showing widespread erythema after imatinib treatment.

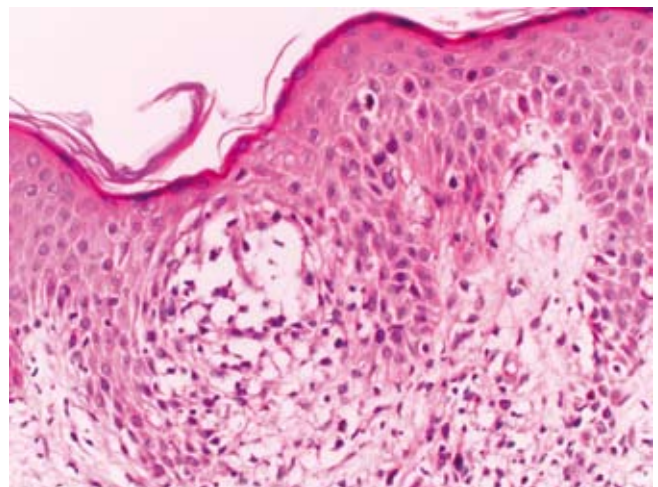


Fig. 2. Epidermis showing focal spongiotic vesiculation (haematoxylin and eosin,  $\times 200$ ).

affecting normal cells (2). Imatinib also shows its effect on the platelet-derived growth factor and c-kit. Recently, it has been shown that imatinib has an antifibrogenic effect on bone marrow fibrosis in CML (3). Except for CML, imatinib has also shown to be effective among idiopathic hypereosinophilic syndrome and gastrointestinal stromal tumours (2). There are few reports concerning the side effects of the drug. Haematological alterations like leukopenia or thrombocytopenia, or thrombocytosis and leukocytosis have been reported (3, 4). Skin changes due to imatinib are palpebral oedema, skin hypopigmentation and reactivation of porphyria cutanea tarda (5–7). All side effects reported are reversible. Our case is the first report showing the erythrodermic potential of the drug.

The Naranjo scale is a scale used for evaluating drug side effects. It is an objective quantitative method to state the relation between the drug usage and formation of a specific side effect (8). The Naranjo scale concludes different relations such as 'doubtful', 'possible', 'probable' and 'highly probable'. When the Naranjo scale was used for our patient, it indicated a 'highly probable' relationship (with a value of 9) between the adverse effect and imatinib therapy.

## REFERENCES

1. Melo JV, Hughes TP, Apperley JF. Chronic myeloid leukemia. *Hematology (Am Soc Hematol Educ Program)* 2003; 1: 132–152.
2. Abou-Jawde R, Choueiri T, Alemany C, Mekhail T. An overview of targeted treatments in cancer. *Clin Ther* 2003; 25: 2121–2137.
3. Hasselbalch HC, Bjerrum OW, Jensen BA, Clausen NT, Hansen PB, Birgens H, et al. Imatinib mesylate in idiopathic and postpolycythemic myelofibrosis. *Am J Hematol* 2003; 74: 238–242.
4. Turkina AG, Khoroshko ND, Druzhkova GA, Zingerman BV, Zakharova ES, Chelysheva E, et al. Therapeutic efficacy of imatinib mesylate (Gleevec) in chronic phase of myeloid leukemia. *Ter Arkh* 2003; 75: 62–67.
5. Esmali B, Prieto VG, Butler CE, Kim SK, Ahmadi MA, Kantarjian HM, et al. Severe periorbital edema secondary to STI571 (Gleevec). *Cancer* 2002; 95: 881–867.
6. Tsao AS, Kantarjian H, Cortes J, O'Brien S, Talpaz M. Imatinib mesylate causes hypopigmentation in the skin. *Cancer* 2003; 98: 2483–2487.
7. Breccia M, Latagliata R, Carosino I, Mandelli F, Alimena G. Reactivation of porphyria cutanea tarda as a possible side effect of imatinib at high dosage in chronic myeloid leukemia. *Leukemia* 2004; 18: 182.
8. Naranjo CA, Busto U, Sellers EM, Sandor P, Ruiz I, Roberts EA, et al. A method for estimating the probability of adverse drug reactions. *Clin Pharmacol Ther* 1981; 30: 239–245.