

CLINICAL REPORT

Pimecrolimus and Narrowband UVB as Monotherapy or Combination Therapy in Children and Adolescents with Atopic Dermatitis

Tien-Yi TZUNG¹, Chyi-Bin LIN¹, Ya-Hui CHEN¹ and Chia-Yi YANG²

¹Department of Dermatology, Veterans General Hospital-Kaohsiung, Kaohsiung, Taiwan, and ²Department of Dermatology, Taipei Municipal Ren-Ai Hospital, Taipei, Taiwan

Topical pimecrolimus and narrowband ultraviolet B (UVB) are both known to be effective in treating atopic dermatitis. We compared the clinical efficacy of monotherapy with either twice daily topical 1% pimecrolimus cream or twice weekly narrowband UVB, and combination therapy in 26 children and adolescents with moderate to severe atopic dermatitis in a half-side manner for 6 weeks. Twenty-four patients completed the study. Monotherapy and combination therapy notably reduced the scores of the Eczema Area and Severity Index ($p=0.002$) and the severity of pruritus ($p\leq 0.004$). There was no significant difference in therapeutic efficacy among the treatment regimens at week 6. In conclusion, because of the lack of short-term additive therapeutic efficacy, concomitant use of pimecrolimus and narrowband UVB is inadvisable in treating moderate to severe atopic dermatitis in children and adolescents. Key words: bilateral comparison study; pimecrolimus; narrowband UVB; atopic dermatitis; topical calcineurin inhibitor.

(Accepted May 24, 2005.)

Acta Derm Venereol 2006; 86: 34–38.

Tien-Yi Tzung, MD, 386 Ta-Chung 1st Rd, Kaohsiung 813, Taiwan, E-mail: tytzung@isca.vghks.gov.tw

Atopic dermatitis (AD) is a chronic relapsing inflammatory skin disorder affecting up to 20% of school-aged children (1). At present, topical corticosteroids are the state-of-the-art treatment, but the potential adverse effects of topical corticosteroids draw concern from patients and their families and compromise treatment compliance (2, 3).

Pimecrolimus is a novel steroid-free topical calcineurin inhibitor (TCI) (4), which has shown its effectiveness and safety in the treatment of mild to moderate AD from infants to adults (5–9). It can also reduce the episodes of flares and the amount of corticosteroids used to avoid flares (7, 8, 10). Additionally, narrowband ultraviolet B (nUVB) is known to be an effective treatment modality for moderate to severe AD in adults as well as in children (11–13). When combined with topical corticosteroids, nUVB phototherapy can reduce the amount and the potency of corticosteroids used (11,

14). The efficacy of combination therapy using pimecrolimus and nUVB in AD has never been reported. The objective of our study was to clarify whether combination therapy is more effective than monotherapy using either pimecrolimus or nUVB alone in treating children and adolescents with AD. However, the combination of ultraviolet therapy and TCI is not recommended by the manufacturers of these products for safety reason.

MATERIALS AND METHODS

This was a single-centre, prospective, randomized, investigator-blind, bilateral comparison study approved by the local ethics and pharmacy committee. Written informed consent was obtained from patient's parents or guardians before the study.

Subject selection

Children and adolescents, aged from 5 to 17 years old, suffering from moderate to severe AD of symmetric distribution were eligible for recruitment. Before treatment, each patient was interviewed and received a thorough physical examination including a clinical assessment of AD with the Eczema Area and Severity Index (EASI) (15), which is a validated method of assessment in AD (16). Four key signs (erythema, induration/papulation, excoriation and lichenification) were rated on a scale from 0 to 3 at four body sites (head and neck, upper limb, trunk and lower limb) to provide a maximum score of 72, namely, 36 for each half of the body. Patients receiving antihistamines, systemic corticosteroids, immunosuppressive therapy, Chinese herbal medicine or phototherapy during the preceding 3 months were excluded, as were those who had received topical corticosteroids or antihistamines during the preceding 1 week. Of 26 enrolled patients (12 male and 14 female), the disease severity scored at least 3 with a mean of 4.2 in the Investigator's Global Assessment (6). The mean whole body EASI score was 30.5 (SD=11.7, 12.2–52.5) with a mean involved body surface of 48.5% (range 15–95). At baseline, bilateral severity of AD in all patients rated by EASI scores was similar ($p=0.477$).

Treatments

Patients were randomized to treatment with a thin film of 1% pimecrolimus cream (Elidel[®], Novartis Pharma GmbH, Nuremberg, Germany) twice daily on all skin lesions and one half of the body was chosen at random to be treated with nUVB twice



Fig. 1. Tailor-made clothing for half-side irradiation.

weekly for 6 weeks. The other half of the body was shielded from irradiation with tailored UV-filtering clothing (Fig. 1), which could prevent the transmission of UV radiation completely (group A; $n=12$). In the second group, lesions on one half of the body assigned randomly had a thin film of pimecrolimus cream applied twice daily and the whole body was irradiated with nUVB twice weekly for the same duration (group B; $n=14$). The amount of pimecrolimus cream used in both groups was documented. On the irradiation days, pimecrolimus was applied 1 h after irradiation.

Irradiation was performed using 24 Waldmann TL-01/100 fluorescent tubes mounted in a UV 5001BL cabinet (Waldmann, Villingen-Schwenningen, Germany). The starting dose was 70% of the predetermined minimal erythema dose for each patient with percentage-based increments every week to a maximum dose of 1.5 J/cm² (17). No other active treatment, including emollients, was allowed. However, in the 4-week post-treatment observation phase, petrolatum could be used liberally.

Assessments

The evaluation was performed by the same blinded investigator at week 0 (baseline), 1, 2, 4, 6 and post-treatment week 2 and 4 with the aid of a set of reference photographs whose severity had been agreed among the investigators. The primary outcome measure was the change of EASI scores. The severity of pruritus experienced during the previous 24 h before each visit was assessed by the patients or their primary caregivers with a 10-cm visual analogue scale. At baseline, the mean pruritus score was 6.9. Sleep loss, which could not be evaluated in a half-side fashion, was excluded. Adverse events were documented on each visit. A complete blood cell count, blood chemistry and serum level of eosinophilic cationic protein (ECP) and total IgE were determined at baseline and at the end of the treatment.

Statistical analysis

EASI score and the severity of pruritus were compared at baseline and across six time points using Friedman's test. The comparisons between the baseline and the other six time points were evaluated with the Wilcoxon signed ranks test, as was the comparison between combination therapy and monotherapy. A p value <0.05 was considered statistically significant.

RESULTS

Group A (combined therapy vs pimecrolimus alone)

Compared with baseline, combination therapy with nUVB and topical pimecrolimus and monotherapy using topical pimecrolimus both showed therapeutic effectiveness in AD after the 6-week treatment with a mean reduction in EASI scores of 56% and 53% from baseline ($p=0.002$ for both) (Fig. 2A). There was no difference between combination therapy and pimecrolimus alone ($p=0.084$) (Fig. 3A, B). One patient showed almost clearing of the skin lesions at week 6 and still had no flares at week 10. Compared with the side using pimecrolimus alone, combination therapy did not reduce the amount of pimecrolimus used during the treatment phase ($p=0.858$). Nevertheless, the side treated with pimecrolimus alone tended to flare more rapidly after discontinuation of treatment ($p=0.002$, week 10).

Group B (combined therapy vs nUVB alone)

Combination therapy and monotherapy using nUVB both demonstrated therapeutic effectiveness in AD after the 6-week treatment with mean 59% and 55% reductions of EASI scores from baseline ($p=0.002$ and $p=0.002$, respectively) (Fig. 2B). There was no difference between combination therapy and nUVB alone at the end of the 6-week treatment ($p=0.059$) (Fig. 3C, D) as well as the 4-week follow-up ($p=0.093$). One patient showed almost clearing of the skin lesions at week 6 and still had no flares at week 10.

Severity of pruritus and side effects

Combination therapy and monotherapy with either pimecrolimus or nUVB were all equally effective in reducing pruritus with a mean score reduction of 3.1, 3.0 and 3.0 at the end of treatment ($p<0.001$, $p=0.002$ and $p=0.004$, respectively). Two patients in group B complained of intractable generalized pruritus and tender erythema after nUVB irradiation, whereas the others in both groups tolerated the treatment protocol well. The laboratory investigations including ECP and IgE level did not reveal any consistent change during the course of treatment.

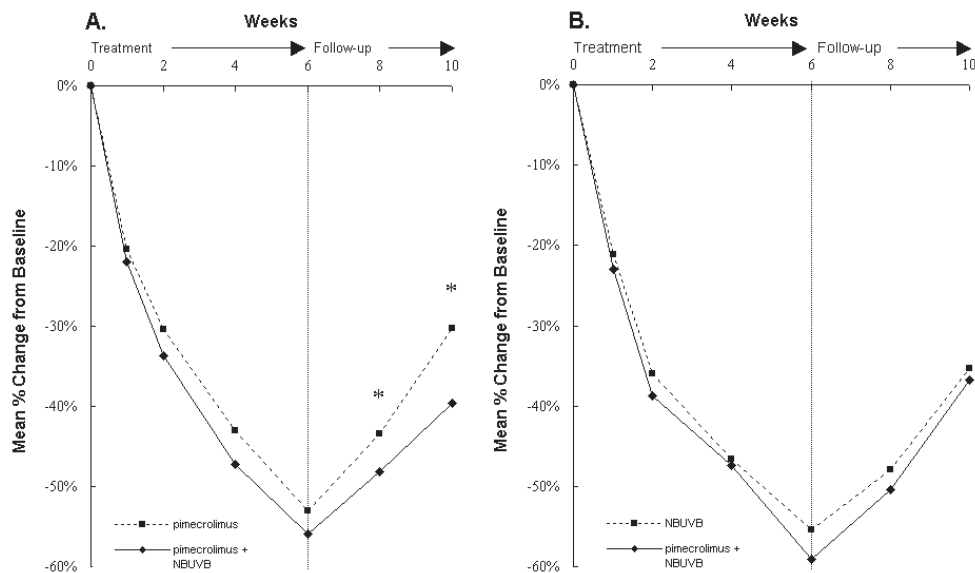


Fig. 2. Eczema Area and Severity Index – mean % change from baseline in group A (A) (pimecrolimus combined with narrowband UVB (NBUVB, nUVB) vs pimecrolimus alone) and in group B (B) (pimecrolimus combined with nUVB vs nUVB alone). Combination therapy had a statistically significant better maintenance effect than monotherapy using pimecrolimus at week 8 and week 10 ($*p=0.047$ and $*p=0.002$, respectively) in group A.

DISCUSSION

The exact mechanism of narrowband UVB in treating AD is not certain to date. However, the immunomodulatory effects of UV phototherapy are known to be of critical importance for its therapeutic efficacy, including induction of immunosuppressive factors, regulation of proteolytic enzymes by UV-inducible cytokines, modulation of adhesion molecule expression, targeting

of cytokine and growth factor receptors, and induction of apoptosis in skin-infiltrating cells (18–19).

Pimecrolimus specifically targets T cells in affected skin, preventing T-cell reactivation and suppressing the release of proinflammatory cytokines (4, 20). It is interesting to know whether combination therapy using nUVB and pimecrolimus has an additive or synergistic effect in treating AD.

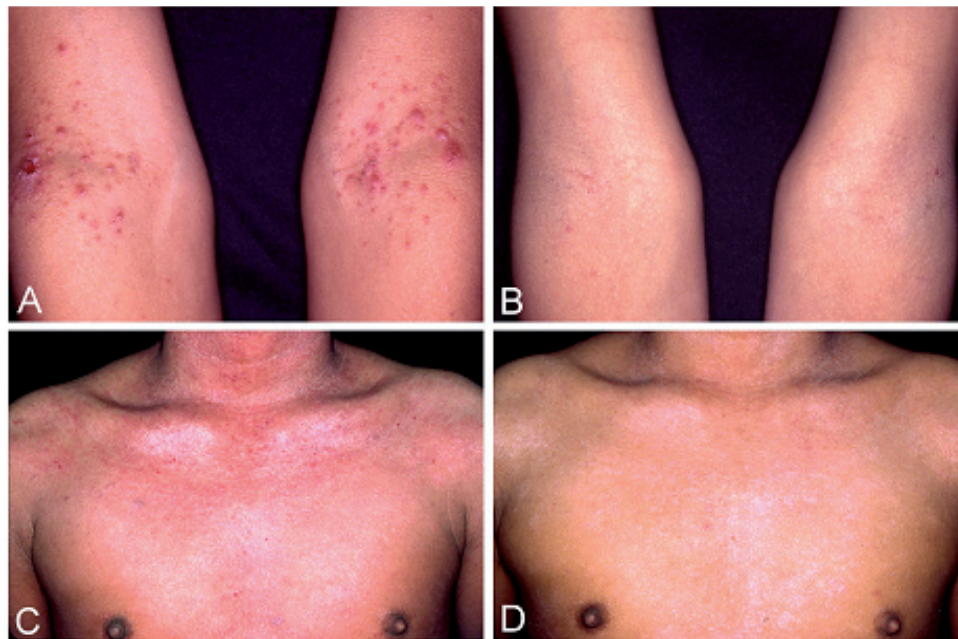


Fig. 3. (Top) Atopic dermatitis (AD) lesions on the bends of the arms of a 10-year-old boy, treated with pimecrolimus on the whole body and additionally with nUVB irradiation on the left side of the body (group A). (A) baseline; (B) after 6-week treatment. (Bottom) AD lesions on the chest of a 15-year-old boy, treated with nUVB irradiation on the whole body and additionally with pimecrolimus on the right side of the body (group B). (C) baseline; (D) after 6-week treatment.

In our study, pimecrolimus and nUVB phototherapy used either alone or in combination notably reduced the EASI scores and severity of pruritus. Unlike an additive therapeutic effect of tacrolimus plus excimer laser in vitiligo (21), our study did not show any significant therapeutic difference between monotherapy and combination therapy in AD.

Bilateral comparison studies have been widely used to compare the efficacy of different modalities of phototherapy. The advantage is that all variables that could influence treatment outcome, apart from the one being studied, are the same. Previous studies in AD indicated that conventional UVB (22) and nUVB (23) had a better therapeutic efficacy than placebo white light and UVA/UVB, respectively. However, the results of all the following bilateral comparison studies in patients with AD, including UVA/UVB versus UVB (24), UVA solarium versus UVB (25), and PUVA versus nUVB phototherapy (26), showed similar efficacy regardless of the type of intervention. One possible explanation for the above-mentioned results is that systemic effects of photo(chemo)therapy might have contributed to the other half of the body not treated and thus obscure a difference in efficacy. Nevertheless, in severe AD treated with UVA1, Tzaneva et al. (27) demonstrated that lesions protected from irradiation had no parallel improvement with irradiated ones. In addition, Dawe et al. (28) found that nUVB phototherapy cleared chronic plaque psoriasis mainly through local rather than systemic effects. In our study, no improvement of shielded, perineal lesions in two patients of group B also suggested that direct irradiation accounted largely for the clinical improvement. Furthermore, the longer remission on the irradiated side of group A patients indicates a local effect of nUVB, as this type of irradiation is known to induce long-lasting remission (11, 23, 26).

It was not our purpose to determine whether the use of a TCI plus UV exposure could induce long-term adverse effect. In fact, tacrolimus itself had a UVB filter effect and inhibited the formation of thymine dimers in UVB-exposed mouse skin (29). However, Niwa et al. (30) using the 7,12-dimethylbenz(a)anthracene/12-O-tetradecanoylphorbol-13-acetate (DMBA-TPA) model demonstrated accelerated carcinogenesis of tacrolimus in mice, although pimecrolimus itself had no further influence on the rate of UV radiation-induced skin tumours in an albino hairless mice study (31). For safety concerns, we adjusted the irradiation regimen of Reynolds et al. (14) from 12 weeks to 6 weeks. If combination therapy was more efficacious than monotherapy, a favourable improvement might have been detected within a shorter period of treatment.

In conclusion, the results of our study provide clinical evidence supporting the consensus of the European Working Group on Atopic Dermatitis (20). Combining phototherapy with TCI treatment is inadvisable and, in

most cases, unnecessary, not only because of long-term safety concerns but also because of the lack of short-term additive therapeutic efficacy.

ACKNOWLEDGEMENT

We thank Dr Nai-Jen Hsu for his invaluable help while preparing this manuscript. No conflict of interest exists.

REFERENCES

1. Leung AK, Barber KA. Managing childhood atopic dermatitis. *Adv Ther* 2003; 20: 129–137.
2. Charman CR, Morris AD, Williams HC. Topical corticosteroid phobia in patients with atopic dermatitis. *Br J Dermatol* 2000; 142: 931–936.
3. Thestrup-Pedersen K. Treatment principles of atopic dermatitis. *J Eur Acad Dermatol Venereol* 2002; 16: 1–9.
4. Grassberger M, Baumruker T, Enz A, Hiestand P, Hultsch T, Kalthoff F, et al. A novel anti-inflammatory drug, SDZ ASM 981, for the treatment of skin diseases: in vitro pharmacology. *Br J Dermatol* 1999; 141: 264–273.
5. Luger T, Van Leent EJ, Graeber M, Hedgcock S, Thurston M, Kandra A, et al. SDZ ASM 981: an emerging safe and effective treatment for atopic dermatitis. *Br J Dermatol* 2001; 144: 788–794.
6. Eichenfield LF, Lucky AW, Boguniewicz M, Langley RG, Cherill R, Marshall K, et al. Safety and efficacy of pimecrolimus (ASM 981) cream 1% in the treatment of mild and moderate atopic dermatitis in children and adolescents. *J Am Acad Dermatol* 2002; 46: 495–504.
7. Wahn U, Bos JD, Goodfield M, Caputo R, Papp K, Manjra A, et al. Efficacy and safety of pimecrolimus cream in the long-term management of atopic dermatitis in children. *Pediatrics* 2002; 110: e2.
8. Meurer M, Folster-Holst R, Wozel G, Weidinger G, Junger M, Brautigam M. Pimecrolimus cream in the long-term management of atopic dermatitis in adults: a six-month study. *Dermatology* 2002; 205: 271–277.
9. Ho VC, Gupta A, Kaufmann R, Todd G, Vanaclocha F, Takaoka R, et al. Safety and efficacy of nonsteroid pimecrolimus cream 1% in the treatment of atopic dermatitis in infants. *J Pediatr* 2003; 142: 155–162.
10. Ellis C, Luger T, Abeck D, Allen R, Graham-Brown RA, De Prost Y, et al. International Consensus Conference on Atopic Dermatitis II (ICCAD II): clinical update and current treatment strategies. *Br J Dermatol* 2003; 63: 3–10.
11. George SA, Bilslund DJ, Johnson BE, Ferguson J. Narrow-band (TL-01) UVB air-conditioned phototherapy for chronic severe adult atopic dermatitis. *Br J Dermatol* 1993; 128: 49–56.
12. Collins P, Ferguson J. Narrowband (TL-01) UVB air-conditioned phototherapy for atopic eczema in children. *Br J Dermatol* 1995; 133: 653–655.
13. Degitz K, Messer G, Plewig G, Röcken M. Schmalspektrum-UVB 311nm versus Breitspektrum-UVB. *Neue Entwicklungen in der Phototherapie. Hautarzt* 1998; 49: 795–806.
14. Reynolds NJ, Franklin V, Gray JC, Diffey BL, Farr PM. Narrow-band ultraviolet B and broad-band ultraviolet A phototherapy in adult atopic eczema: a randomised controlled trial. *Lancet* 2001; 357: 2012–2016.
15. Hanifin JM, Thurston M, Omoto M, Cherill R, Tofte SJ, Graeber M. The eczema area and severity index (EASI): assessment of reliability in atopic dermatitis. *Exp Dermatol* 2001; 10: 11–18.

16. Barbier N, Paul C, Luger T, Allen R, De Prost Y, Papp K, et al. Validation of the Eczema Area and Severity Index for atopic dermatitis in a cohort of 1550 patients from the pimecrolimus cream 1% randomized controlled clinical trials programme. *Br J Dermatol* 2004; 150: 96–102.
17. Grundmann-Kollmann M, Behrens S, Podda M, Peter RU, Kaufmann R, Kerscher M. Phototherapy for atopic eczema with narrow-band UVB. *J Am Acad Dermatol* 1999; 40: 995–997.
18. Agati G, Fusi F. New trends in photobiology. Biological effects of narrow-band (311 nm TL01) UVB irradiation: a review. *J Photochem Photobiol B* 1997; 38: 99–106.
19. Krutmann J, Morita A, Elmetts CA. Mechanisms of photo-(chemo)therapy. In: Krutmann J, Hönigsmann H, Elmetts CA, Bergstresser PR, eds. *Dermatological phototherapy and photodiagnostic methods*. New York: Springer, 2001: 54–65.
20. Alomar A, Berth-Jones J, Bos JD, Giannetti A, Reitamo S, Ruzicka T, et al. (European Working Group on Atopic Dermatitis). The role of topical calcineurin inhibitors in atopic dermatitis. *Br J Dermatol* ; 151: 3–27.
21. Passeron T, Ostovari N, Zakaria W, Fontas E, Larrouy JC, Lacour JP, et al. Topical tacrolimus and the 308-nm excimer laser: a synergistic combination for the treatment of vitiligo. *Arch Dermatol* 2004; 140: 1065–1069.
22. Jekler J, Larkö O. UVB phototherapy of atopic dermatitis. *Br J Dermatol* 1988; 119: 697–705.
23. Hjerpe M, Hasan T, Sakasala I, Reunala T. Narrowband UVB treatment in atopic dermatitis. *Acta Derm Venereol* 2001; 81: 439–440.
24. Jekler J, Larkö O. Combined UVA-UVB versus UVB phototherapy for atopic dermatitis: a paired-comparison study. *J Am Acad Dermatol* 1990; 22: 49–53.
25. Jekler J, Larkö O. UVA solarium versus UVB phototherapy of atopic dermatitis: a paired-comparison study. *Br J Dermatol* 1991; 125: 569–572.
26. Der-Petrossian M, Seeber A, Hönigsmann H, Tanew A. Half-side comparison study on the efficacy of 8-methoxypsoralen bath-PUVA versus narrow-band ultraviolet B phototherapy in patients with severe chronic atopic dermatitis. *Br J Dermatol* 2000; 142: 39–43.
27. Tzaneva S, Seeber A, Schwaiger M, Hönigsmann H, Tanew A. High-dose versus medium-dose UVA1 phototherapy for patients with severe generalized atopic dermatitis. *J Am Acad Dermatol* 2001; 45: 503–507.
28. Dawe RS, Cameron H, Yule S, Man I, Ibbotson SH, Ferguson J. UV-B phototherapy clears psoriasis through local effects. *Arch Dermatol* 2002; 138: 1071–1076.
29. Tran C, Lubbe J, Sorg O, Carraux P, Didierjean L, Saurat J. Topical tacrolimus decreases UVB-induced DNA damage in mouse skin. *J Invest Dermatol* 2003; 121: abstract 1072.
30. Niwa Y, Terashima T, Sumi H. Topical application of the immunosuppressant tacrolimus accelerates carcinogenesis in mouse skin. *Br J Dermatol* 2003; 149: 960–967.
31. Forbes PD. Expert commentary on the preclinical photocarcinogenesis study SDZ ASM 981 cream: 52-week photocarcinogenesis study in hairless mice. Novartis data on files.