

A Superficial Form of Malignant Peripheral Nerve Sheath Tumour Associated with Segmental Neurofibromatosis

Kapsok Li, Chong Hyun Won and Sang Eun Moon*

Department of Dermatology, Seoul National University Boramae Hospital, 425 Shindaebang-dong, Dongjak-gu, Seoul, 156-707, Korea. *E-mail: semoon@snu.ac.kr

Accepted April 18, 2005.

Sir,

Malignant peripheral nerve sheath tumour (MPNST) is a sarcoma that arises from peripheral nerves or displays differentiation of the nerve sheath elements. Usually MPNST occurs in a clinical setting of neurofibromatosis, type 1 (NF1) – about 50% of MPNSTs are associated with NF1 (1), and they rarely arise from segmental NF (NF5) (2). Commonly, MPNST is found in deep soft tissue along the major peripheral nerve trunk and consists of spindle-shaped tumour cells. Meanwhile, though relatively rare, superficial forms of this tumour are also well recognized (3). Herein we describe a case of the superficial form of a low grade MPNST associated with NF5, which showed an unusual spatial and chronological relationship.

CASE REPORT

A 66-year-old woman presented with a skin lesion on the left thigh. Two years earlier a tiny red papule suddenly developed and gradually enlarged, which had subsequently progressed and resulted in a 2.1 × 3.5 cm-sized erythematous indurated plaque (Fig. 1A). The patient did not experience any pain or dysaesthesia of the affected limb. In addition, she had no personal or family history of dermatoses, including NF.

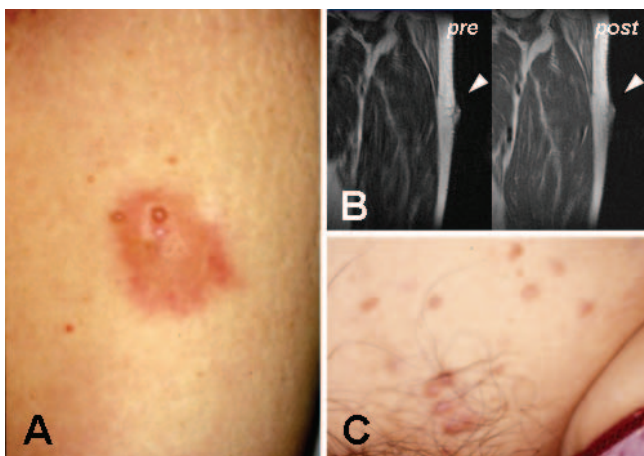


Fig. 1. Clinical manifestations of the skin lesion. (A) Gross appearance of a malignant peripheral nerve sheath tumour: relatively well demarcated 2.1 × 3.5 cm-sized indurated erythematous plaque on the left lateral thigh. (B) Magnetic resonance imaging of the tumour (arrowhead) in pre- and post-enhancement. The tumour was confined to the superficial layer and showed minimal extension to deep portions. (C) Neurofibromas on the left mons pubis.

On physical examination, no café-au-lait spot or axillary/inguinal freckling were observed. An ophthalmological examination revealed only diabetic changes, and no Lisch nodule. Under suspicion of dermatofibrosarcoma protuberans (DFSP), a punch biopsy was performed. The biopsy specimen showed a spindle-cell tumour mainly located in the dermis without epidermal melanocytic dysplasia or dermo-epidermal junctional disturbance. Hypercellularity and nuclear atypia were notable, but few mitoses were identified (Fig. 2A). A further immunohistochemical evaluation revealed S100+, HMB45– and CD34– (Fig. 2B). Magnetic resonance imaging (MRI) revealed an exophytic mass protruding from the superficial layer. There was no evidence of extension to deeper tissue or lymphadenopathy (Fig. 1B).

She was diagnosed as having a superficial form of a low grade MPNST. A wide excision was performed with a 1.5-cm normal skin margin. Gross inspection of the excised specimen revealed no evidence of subcutaneous involvement. During the operation we tried to identify the associated nerve trunk, but failed. She had an uneventful recovery, but 1 month after the operation she

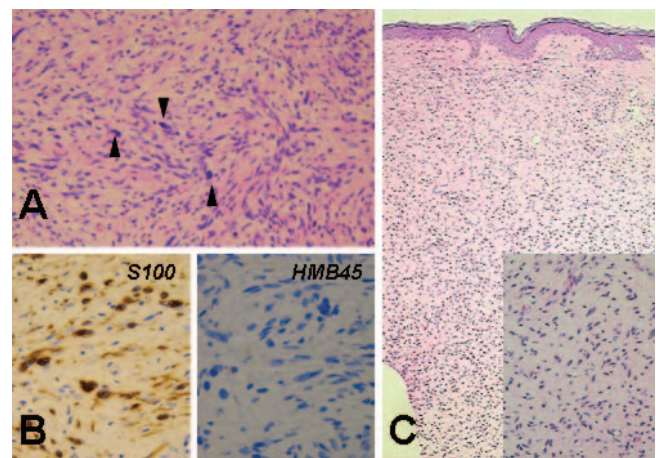


Fig. 2. Histopathological findings. (A) The tumour consisted of spindle cells. A storiform arrangement and hypercellularity were noteworthy. Various features of nuclear atypia were also notable (arrowheads) (H&E, ×100). (B) Immunohistochemical findings for S100 and HMB45: only S100 protein was stained in tumour cells (immunoperoxidase method, ×200). (C) A biopsy specimen from the neurofibroma of the left pubis: in the scanning view, a dermal tumour encompassing the entire dermis can be identified (H&E, ×40). Inset: at higher magnification, the morphology of an individual tumour cell can be appreciated (H&E, ×100).

Table I. Clinical features of previously reported (Ref 2) and our present case (*italic*) of malignant peripheral nerve sheath tumour (MPNSTs) associated with segmental neurofibromatosis

Age/sex	Symptom/tumour location	Nerve origin	Type of MPNST	Treatment	Outcome
43/F	Pain/thigh(anterior)	Lateral femoral cutaneous nerve	Superficial high grade	Operation+radiation+ chemotherapy	Recurrence at 26 months
48/F	Radiating pain/intrapelvic	Posterior femoral cutaneous nerve	Deep	Operation+chemotherapy	Recurrence at 2 months
66/F	<i>Asymptomatic/thigh (lateral)</i>	<i>Not identified</i>	<i>Superficial/low grade</i>	<i>Operation</i>	<i>No recurrence at 16 months</i>

complained of multiple erythematous papules on the left mons pubis (Fig. 1C), which were later confirmed as neurofibroma by biopsy (Fig. 2C). These neurofibromas were confined to the left pubis without signs of NF1 in other dermatomes, and thus classified as NF5.

Sixteen months after en bloc excision, she was free of any side effect or disability and there was no evidence of recurrence. The NF5 lesions on the pubis were unchanged.

DISCUSSION

The actual case was classified as a low grade MPNST based on pathology and MRI scans. A clear resection margin and minimal subcutaneous invasion with no evidence of local invasion or distant metastases confirmed the superficial nature of this case. Microscopically, hypercellular spindle cells with diffuse nuclear atypia were notable, but mitotic figures were scant. Thus we ruled out cellular neurofibroma or schwannoma, and designated the tumour as low grade. Differential diagnosis from other spindle-cell fibrosarcomas was possible by immunohistochemical studies. S100+/HMB45- indicated a neurogenic origin and dismissed the possibility of an ordinary melanoma (additional information is required to rule out HMB45- melanoma, such as amelanotic melanoma, *vide infra*). CD34 stained only on vascular endothelium, and thus DFSP was excluded as a possible diagnosis.

Superficial MPNSTs have several features that discriminate them from their deep counterparts (4). Histologically deep MPNSTs usually show spindle-type tumour cells, but in superficial MPNSTs an epithelioid type is much more frequently encountered (3). This case showed spindle-type tumour cells, a minor histological variant for superficial MPNST. In the case of ordinary spindle cell superficial MPNST, differential diagnosis from amelanotic melanoma poses great difficulty. The common embryological origin of melanocytes and Schwann cells makes the problem more intricate. As suggested by Schadendorf et al. (5), distinction between MPNST and amelanotic melanoma cannot be made on a histopathological basis alone. In the present case, the benign nature of the primary tumour was evident at diagnosis, i.e. no evidence of local invasion or distant

metastases. Additionally there was no sign or symptom of recurrence at 16-month follow-up after excision.

The difference between NF1 and NF5 can be traced back to the timing of *NF-1* gene mutation, crudely germline vs somatic. Genetic aberrancy in NF1 is far wider in extent and severity, and thus NF1 has a higher malignant potential. Progression of NF1 into MPNST is well established, but NF5 has rarely been associated with MPNST. Only one case report exists in the English literature (2), which is summarized in Table I in addition to our case.

In the present case, the relationship between MPNST and later developed NF5 seems to be remote, spatially and chronologically. At first glance the two lesions seem to be located at different dermatomes, although a hint of a connection is suggested by the iliohypogastric nerve, which originates from the lumbar plexus and ramifies over the iliac crest into its lateral cutaneous and anterior pubic branches (6). The development of NF5 after resection of MPNST seems to be more perplexing, considering the fact that in general a MPNST develops from known neurofibroma. We suspect that the sudden appearance of NF5 was because of unnoticed lesions growing into gross lesions after the excision of primary MPNST.

REFERENCES

- Weiss SW, Goldblum JR. Malignant tumors of the peripheral nerves. In: Weiss SW, Goldblum JR, editors. Soft tissue tumors, 4th edn. St Louis: Mosby, : 1209–1263.
- Schwarz J, Belzberg AJ. Malignant peripheral nerve sheath tumors in the setting of segmental neurofibromatosis. *J Neurosurg* 2000; 92: 342–346.
- Misago N, Ishii Y, Kohda H. Malignant peripheral nerve sheath tumor of the skin: a superficial form of this tumor. *J Cutan Pathol* 1996; 23: 182–188.
- Coady MSE, Polaczar S, Page RE. Cutaneous malignant peripheral nerve sheath tumor (MPNST) of the hand: a review of current literature. *J Hand Surg* 1993; 18B: 478–481.
- Schadendorf D, Haas N, Worm M, Ostmeier H, Kohlmus C, Gottschalk J, et al. Amelanotic malignant melanoma presenting as malignant schwannoma. *Br J Dermatol* 1993; 129: 609–614.
- Netter FH. Section IV. Abdomen and Section VII. Lower limb. In: Netter FN, Colacino S, editors. Atlas of human anatomy, 8th edn. Ciba-Geigy Corporation, 1998: Plate 240, 467.