

Disseminated Cryptococcosis in an Elderly Woman

Jesús Rodríguez-Lozano¹, Manuel Almagro¹, Jesús del Pozo¹, Juan Mosquera², Beatriz Fernández-Jorge¹, Sabela Paradelo¹ and Eduardo Fonseca¹

Departments of ¹Dermatology and ²Pathology, Hospital Juan Canalejo, La Coruña, Sir John Moore S/N, ES-15001 La Coruña, Spain. E-mail: del_pozo@canalejo.org

Accepted March 11, 2005.

Sir,

Cryptococcosis is a fungal infection caused by *Cryptococcus neoformans*, an opportunistic yeast with a worldwide distribution. The portal of entry is usually the respiratory tract and it may cause pneumonia, pulmonary nodules, pleural effusion or an asymptomatic pulmonary infection. From this location it disseminates to other viscera, mainly the central nervous system and the skin. Cutaneous lesions in systemic cryptococcosis may have very different clinical features, even in the same patient. Cryptococcal disease usually affects immunosuppressed individuals, especially those with HIV infection, but it has been described in immunocompetent patients, including cases in elderly people, in whom senescent changes in immunological function may have played a role.

CASE REPORT

A 75-year-old woman was admitted to our hospital with asymptomatic skin lesions on her right thigh, right shoulder and back with 3 months of evolution, and without systemic manifestations. She had a past history of dementia due to hydrocephalus for 25 years, and pneumonia 8 months before her admission.

Her cutaneous lesions were interpreted as cutaneous abscesses and treated with oral antibiotics without improvement.

A detailed examination revealed different types of lesions. On the anterior side of her thigh she presented an ulcerative lesion sharply delimited with an erythematous halo (Fig. 1). On her shoulder and right leg she presented abscessiform lesions with underlying fluctuation, like cold abscesses, without inflammatory signs (Fig. 1). A fistulous lesion was present over her right scapula.

The histopathological study of skin biopsies showed a granulomatous dermatitis with necrotizing areas. PAS, Alcian blue and mucicarmine staining revealed multiple yeast forms surrounded by a clear capsule (Fig. 2).

Due to clinical presentation, characterized by cold abscesses, investigations to rule out mycobacterial or fungal infection were done and microbiological studies yielded *C. neoformans* var. *neoformans*. The routine complementary tests were normal.

With the diagnosis of cutaneous cryptococcosis additional studies were done to detect other organ involvement, and to assess if our patient had immunodeficiency or underlying malignancy.

Serum and cerebrospinal fluid (CSF) cryptococcal antigen tests were negative, as were serum and CSF cultures. Brain CT scan showed cortical atrophy and hydrocephalus, chest X-ray was normal and sputum culture was negative. Urine culture yielded *C. neoformans*. HIV 1 and 2, cytomegalovirus, Epstein-Barr virus, hepatitis B virus, hepatitis C virus and syphilis, T-cell subset analysis and tumoral markers

were investigated; all results were normal or negative. Occult blood in faeces was positive, and therefore colonoscopy was performed, showing a benign polyp in the colon.

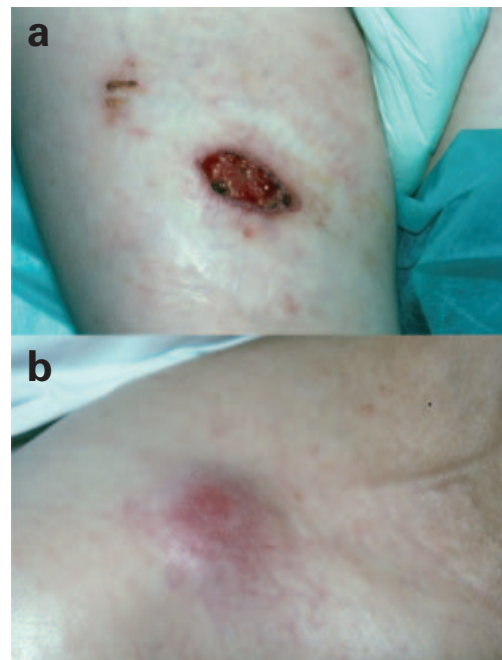


Fig. 1. (a) An ulcerative lesion on the thigh. (b) An abscessiform lesion on the shoulder.

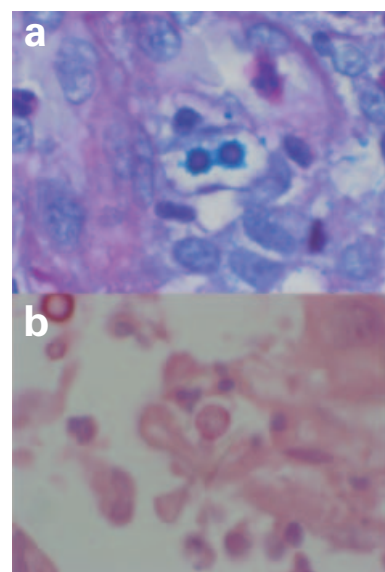


Fig. 2. (a) Alcian blue and (b) mucicarmine stains showing yeast forms.

Abdominopelvic CT detected a pelvic mass, and benign teratoma was diagnosed at subsequent gynaecological valuation. Given her poor general state, surgery was not indicated and the patient is undergoing periodic revisions.

The patient was treated with intravenous fluconazole 200 mg/12 h for 15 days and thereafter oral fluconazole 200 mg/day for 6 months. The lesions healed completely and no recurrence or any other skin lesion has appeared in the 1 year of follow-up.

DISCUSSION

Cryptococcosis, also named torulosis, European blastomycosis and Buschke disease, is a mycosis caused by *C. neoformans*, an opportunistic yeast with a worldwide distribution. *C. neoformans* has two varieties and five serotypes. Serotypes A, D and AD correspond with *neoformans* variety, whereas B and C serotypes correspond with *gattii* variety (1–3).

This yeast grows unencapsulated in the environment and in fruits, some trees and other vegetables (4). It is present in the digestive tract of pigeons, and is eliminated in great amounts in their faeces, but the fungus does not infect these birds (4). *C. neoformans* var. *neoformans* is more prevalent in Europe, the USA and other temperate climates throughout the world, whereas *C. neoformans* var. *gattii* is more prevalent in Africa and in tropical and subtropical areas and is not associated with birds, but it grows in the litter around certain species of eucalyptus trees (5).

The disease is usually acquired in the context of a cellular immunodeficiency, as in patients with AIDS (6), transplant recipients receiving immunodepressors and/or corticosteroids, patients with lymphomas, and those with sarcoidosis (7). Nevertheless, some authors do not consider *C. neoformans* var. *gattii* an opportunistic microorganism as it commonly infects non-immunosuppressed hosts (3, 8).

The portal of entry is usually the respiratory tract. It is usually asymptomatic, but pulmonary disease may ensue. If immunodeficiency is present, *Cryptococcus* can spread to other internal organs like the brain, meninges, skin, bone and genitor-urinary tract (1, 2). Infection of the central nervous system will determine the prognosis and sequelae. This fungal infection has a high mortality rate, frequently leading to sequelae and relapses (9). In our case the respiratory tract was probably the portal of entry, causing dissemination to skin and urinary tract, without demonstrable participation of the central nervous system, as the dementia was very long-standing.

Cutaneous lesions can be seen anywhere on the body, but the majority are distributed on the face, scalp and neck. Early recognition of these lesions is very important because they can precede neurological symptoms (10).

We have found only seven cases of cutaneous cryptococcosis in elderly patients in the literature but they were primary (11–13), and to the best of our knowledge, our patient is the first reported case of disseminated cutaneous cryptococcosis in an elderly but immunocompetent host. It seems evident that immune response is impaired in older age, especially in deteriorated individuals.

REFERENCES

- Hay RJ. *Cryptococcus neoformans* and cutaneous cryptococcosis. *Semin Dermatol* 1985; 4: 252–259.
- Hernández AD. Cutaneous cryptococcosis. *Dermatol Clin* 1989; 7: 269–274.
- Diamond RD. *Cryptococcus neoformans*. In: Mandell GL, Bennett JE, Dolin R, editors. *Mandell, Douglas and Bennett's principles and practice of infectious diseases*, vol. 2, 5th edn. New York: Churchill Livingstone, 2000: 2707–2718.
- Pal M, Mehrotra BS. Studies on the isolation of *Cryptococcus neoformans* from fruits and vegetables. *Mykosen* 1985; 28: 200–205.
- King JW. Cryptococcosis. e-Medicine; updated 20 August 2004 [accessed on 20 November 2004]. Available at: <http://www.emedicine.com>.
- Anonymous. Cryptococcosis and AIDS (editorial). *Lancet* 1988; 1: 1434–1436.
- Revinga F, Paricio JF, Nebreda T. Cryptococcosis. *Piel* 2001; 16: 329–334.
- Mitchell DH, Sorrell TC, Allworth AM, Heath CH, McGregor AR, Papanoum K, et al. Cryptococcal disease of the CNS in immunocompetent hosts: influence of cryptococcal variety on clinical manifestations and outcome. *Clin Infect Dis* 1995; 20: 611–661.
- Schupbach CW, Wheeler CE, Briggaman RA. Cutaneous manifestations of disseminated cryptococcosis. *Arch Dermatol* 1976; 112: 1734–1740.
- Revinga F, Paricio JF, Merino FJ, Nebreda T, Ramírez T, Martínez AM. Primary cutaneous cryptococcosis in an immunocompetent host: case report and review of the literature. *Dermatology* 2002; 204: 145–149.
- Werchniak AE, Baughman RD. Primary cutaneous cryptococcosis in an elderly man. *Clin Exp Dermatol* 2004; 29: 159–160.
- Patel PP, Ramanathan J, Kayser M, Baran J. Primary cutaneous cryptococcosis of the nose in an immunocompetent woman. *J Am Acad Dermatol* 2000; 43: 344–345.
- Thomas I, Schwartz RA. Cutaneous manifestations of systemic cryptococcosis in immunosuppressed patients. *J Med* 2001; 32: 259–266.