

## Treatment of Molluscum Contagiosum with Topical Diphenacyprone Therapy

Seung Hoon Kang, Deborah Lee, Jeong Hoon Park, Si Hyung Cho\*, Sang Seok Lee and Sung Wook Park

Departments of Dermatology, Inje University Busan-Paik Hospital, Gaegum-dong 633-165, Busanjin-gu, Busan, 614-735 South Korea. \*E-mail: csh92@hanmail.net

Accepted February 7, 2005.

Sir,

Molluscum contagiosum is a common benign disease of children induced by the molluscum contagiosum virus. Generally, in healthy individuals it heals spontaneously without scars within a few months, and treatment is not absolutely necessary (1–4). However, the disease may spread extensively if it occurs in immunocompromised patients or those with atopic dermatitis (5–7). Furthermore, continuous scratching of the lesions in chronic pruritus may lead to inflammation and secondary bacterial infection. Generally, physical removal by surgical curettage with a curette or small pincer or cryotherapy is used for the treatment of molluscum contagiosum (4–7). However, pain felt during treatment is a major problem because most patients are less than 10 years old. Thus, there have been many attempts to minimize pain by applying topical anaesthetics or administering pharmaceutical agents (8–11). Although immunotherapy using diphenacyprone in the treatment of alopecia areata, verruca vulgaris and verruca plana has been reported in literature, there have not been any reports of its use to treat molluscum contagiosum.

### MATERIALS AND METHODS

This study, approved by the local ethical committee, was conducted on 22 children with multiple lesions who visited the outpatient clinic. Two dermatologists interviewed simultaneously, examined and verified the condition of molluscum contagiosum.

Diphenacyprone (Merck, Whitehouse Station, NJ, USA) in a powder form was dissolved in acetone to make solutions. Sensitization was carried out by applying a 0.5% diphenacyprone solution using a soaked cotton ball stick unilaterally to a 2–3-cm diameter circle on the outer shoulder region. Observations were made 48 hours after diphenacyprone application, and the subjects were judged to have been sensitized if the score was  $\geq 1$  according to the standards set out by ICDRG (International Contact Dermatitis Research Group), which categorizes 0 for no response, 1 for erythema, 2 for small vesicle, and 3 for super-vesicular reaction. One week after initial sensitization, a 0.0001% diphenacyprone solution was applied directly to the lesions and weekly thereafter. Concentration was maintained to the extent of having some itching sensation and erythema for 24–36 hours after the application. The concentration was increased 5–10-fold up to a maximum of 0.1% every week if there was no response.

The numbers of lesions were counted by dividing the body into seven areas such as the face, trunk (abdomen, back), arm (left, right) and leg (left, right). The numbers were verified and recorded for the same body parts on each visit. Eight weeks after treatment began its efficacy was determined by changes in the number of lesions. Efficacy was determined by comparing

the total number of lesions. It was categorized as 'complete clearance' if there was absolute clinical clearance; 'good response', clearance of 50% or more; 'fair response', clearance of < 50%; and 'fail', in the case of no clearance.

### RESULTS

Twenty-two children aged 15 months to 6 years were evaluated. The number of lesions was 20–166 (mean  $69.0 \pm 40.1$ ). The children were treated with topical diphenacyprone weekly and were followed up for 8 weeks. Fourteen of 22 patients (63.6%) achieved a complete clearance in the mean treatment period of 5.1 weeks (Fig. 1). Partial clearance was observed in three patients (13.6%) who were treated at inadequate intervals. Most patients experienced partial erythema and mild pruritus during treatment, but the symptoms were mild enough to allow it to continue. However, four patients dropped out because of the adverse effects of the treatment.

### DISCUSSION

Many mechanical methods such as cryotherapy and surgical curettage have been used for treatment of molluscum contagiosum (4, 7). In patients with an excessive number of lesions, pain accompanying treatment is a significant factor. To overcome such problems, painless treatments using phodophylline, salicylic acid, potassium hydroxide, silver nitrate, trichloroacetic acid, retinoic acid and imiquimod have been attempted (8–11).

We evaluated the clinical effectiveness and advantages of diphenacyprone immunomodulatory therapy in treating children with molluscum contagiosum. This study showed that prominent responses to treatment had occurred in areas other than those of topical application and with a simultaneous tendency toward a favourable result. The advantages of diphenacyprone therapy are: there is less pain than with existing invasive methods; the procedure is simple and safe; and the adverse effects are mild. Furthermore, the treatment cost was lower than that of the existing methods. Thus, topical diphenacyprone therapy can be a good choice as a first-line treatment, with a complete cure expected in most patients who have many lesions and can undergo continuous treatment through regular hospital visits.

### ACKNOWLEDGEMENT

We thank Han-Young Wang, MD, PhD, of Wang Hang Young Clinics, Busan, Korea, for comments and contributions.

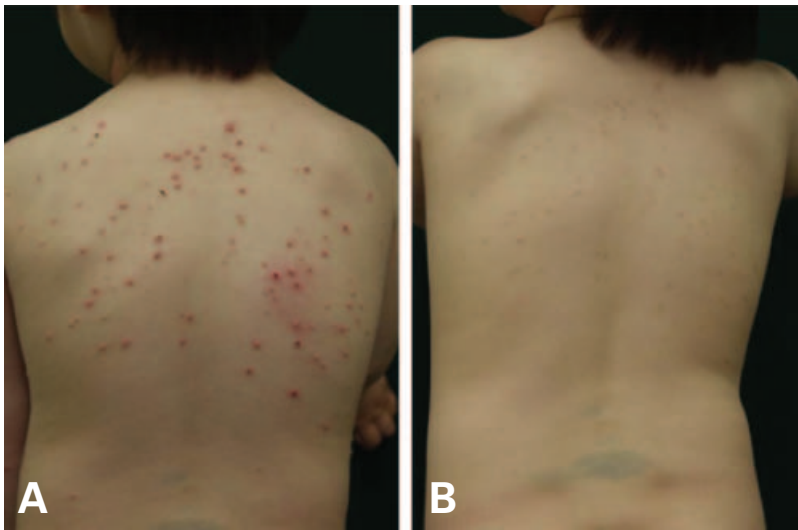


Fig. 1. (A) Numerous molluscum lesions on the back. (B) Eight weeks after application of diphenacyprone, all lesions have cleared leaving temporary hyperpigmentation.

## REFERENCES

1. Janniger CK, Schwartz RA. Molluscum contagiosum in children. *Cutis* 1993; 52: 194–196.
2. Waugh MA. Molluscum contagiosum. *Dermatol Clin* 1998; 16: 839–841.
3. Prasad SM. Molluscum contagiosum. *Pediatr Rev* 1996; 17: 118–119.
4. Myskowski PL. Molluscum contagiosum. New insights, new directions. *Arch Dermatol* 1997; 133: 1039–1041.
5. Schwartz JJ, Myskowski PL. Molluscum contagiosum in patients with human immunodeficiency virus infection. A review of twenty-seven patients. *J Am Acad Dermatol* 1992; 27: 583–588.
6. Vozmediano JM, Manrique A, Petraglia S, Romero MA, Nieto I. Giant molluscum contagiosum in AIDS. *Int J Dermatol* 1996; 35: 45–47.
7. Clinical Effectiveness Group. National guideline for the management of molluscum contagiosum. *Sex Transm Infect* 1999; 75, (Suppl 1), 80–81.
8. Smith KJ, Skelton H. Molluscum contagiosum: recent advances in pathogenic mechanisms, and new therapies. *Am J Clin Dermatol* 2002; 3: 535–545.
9. Skinner RB Jr. Treatment of molluscum contagiosum with imiquimod 5% cream. *J Am Acad Dermatol* 2002; 47, (Suppl 4), 221–224.
10. Romiti R, Ribeiro AP, Grinblat BM, Rivitti EA, Romiti N. Treatment of molluscum contagiosum with potassium hydroxide: a clinical approach in 35 children. *Pediatr Dermatol* 1999; 16: 228–231.
11. Niizeki K, Hashimoto K. Treatment of molluscum contagiosum with silver nitrate paste. *Pediatr Dermatol* 1999; 16: 395–397.