

Eczema Herpeticum During Treatment of Atopic Dermatitis with 1% Pimecrolimus Cream

Sonia Segura, David Romero, Cristina Carrera, Pilar Iranzo and Teresa Estrach

Department of Dermatology, Clinic Hospital, Barcelona University, 170, Villarroel, 08036 Barcelona, Spain. E-mail: sonietast@yahoo.es

Accepted January 28, 2005.

Sir,

The topical immunomodulators tacrolimus and pimecrolimus have proven effective in managing atopic dermatitis (AD). Reported adverse effects are infrequent; however, cutaneous infections are potential complications of their application. Eczema herpeticum (EH) is a widespread viral infection by herpes simplex virus (HSV) often associated with AD. EH was reported in 1.9% of patients treated with 0.1% tacrolimus ointment in an open-labelled, non-comparative study with 6–12 months of follow-up (1). Although other cases of EH during treatment with 0.1% tacrolimus have been reported (2–4), the available data are not enough to link this therapy with an increased risk for EH, nor to exclude an association. EH has also been described in children and adults in clinical trials with 1% pimecrolimus cream (5, 6). We report an adult AD patient who developed EH during treatment with pimecrolimus.

CASE REPORT

A 27-year-old man came to the emergency department with a 2-day history of high fever, malaise and progressive appearance of widespread vesicles that rapidly became eroded. He had a long history of head-and-neck-type AD; flares had been treated with topical immunomodulators during the last year with a good response. For 2 weeks before the present rash, he had been applying pimecrolimus cream for a desquamative cheilitis. He denied any previous oral ulceration or cold sore.

The physical examination showed facial oedema with a monomorphic vesicular eruption on the face, neck, chest, upper back and limb folds (Fig. 1). He also had bilateral cervical lymphadenopathies and tonsillar exudate.

Blood and smear cultures from both cutaneous lesions and tonsillar exudate were negative for bacteria. Viral cultures of two smears from the facial lesions were positive for HSV type 1. Unfortunately, serological studies to assess a primary or secondary infection were not performed. The patient was successfully treated with 5 mg/kg/day intravenous acyclovir and amoxicillin/clavulanic acid antibiotic prophylaxis to prevent bacterial infection of eroded lesions.

DISCUSSION

Patients with AD are prone to present viral infections due to dysfunction of cell-mediated immunity, disruption of skin barrier and contamination secondary to scratching. EH is a generalized cutaneous infection by HSV type 1 or 2, characterized by monomorphic eruption of dome-shaped vesicles accompanied by fever, malaise and lymphadenopathy.

EH has been observed in 3–6% of patients with AD (7, 8), but there is a lack of information about the general incidence of EH in AD, and predisposing factors.

Topical treatments for AD usually have immunosuppressive effects that could increase the risk of viral infections in these patients. The topical use of corticosteroids has been associated with the development of EH in non-controlled studies (7, 9). More recently, a retrospective study that compared 100 cases of EH with 105 control patients with AD failed to demonstrate an apparent relation between EH and corticosteroid treatment, but identified as risk factors early onset of AD and increased total serum IgE (10).

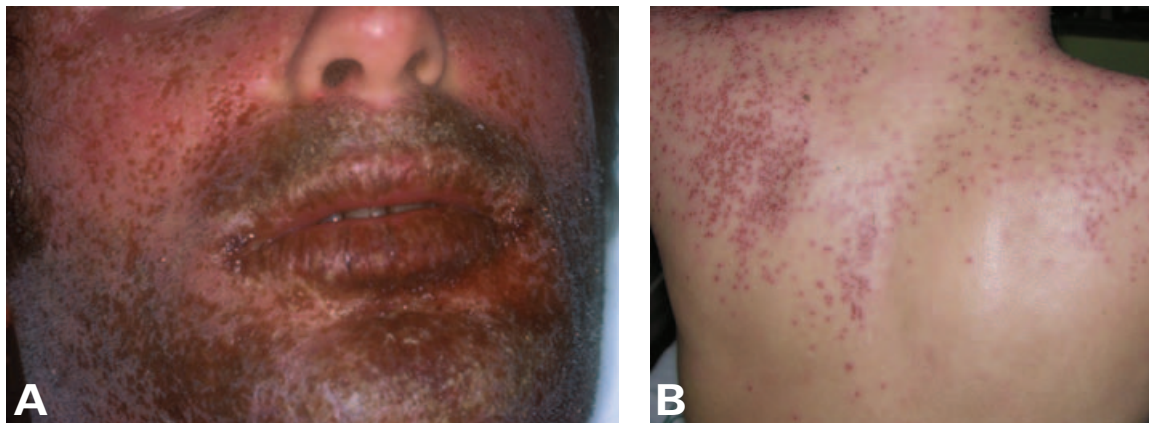


Fig. 1. (A) Facial and lip oedema with confluent vesicles and crusts; (B) monomorphic erosive eruption on the back.

Topical corticosteroids have been the standard treatment for AD, but they carry the risk of skin atrophy, striae, telangiectasia and systemic side effects. The new topical immunomodulators such as tacrolimus and pimecrolimus are effective in the management of AD without the side effects of topical corticosteroids (11).

Tacrolimus is a macrolide molecule that inhibits T-cell activation. Several cases of EH during application of 0.1% tacrolimus ointment have already been described (1–4).

Pimecrolimus is a new ascomycin macrolactam derivative that selectively inhibits the release of pro-inflammatory mediators from activated T cells, via the inhibition of calcineurin (12). It has proved to be effective in the treatment of mild to moderate AD. Its application in early AD lesions prevents the progression to AD flares, reducing the need for corticosteroids (5, 6, 13, 14). Pimecrolimus does not induce skin atrophy and, in contrast to tacrolimus, it has a negligible absorption through the skin, giving a better safety profile – especially in children. Nevertheless, skin infections have been described in clinical trials comparing 1% pimecrolimus cream with either topical corticosteroids or vehicle cream (5, 6, 14). Skin infections were the most frequently reported serious adverse event in a 1-year controlled study with 713 children with AD, which compared topical 1% pimecrolimus cream with topical corticosteroid therapy. In the same study, the incidence of grouped viral skin infections was slightly higher in the pimecrolimus group. Two cases of EH occurred in the study group, although there were no significant differences between both groups in the incidence of individual viral skin infections (5). A more recent randomized study with 192 adult patients with moderate AD compared safety and efficacy of 1% pimecrolimus cream-based treatment versus vehicle cream, and showed HS infection to be more frequent in the pimecrolimus group, even though this difference was not statistically significant (14).

A recent randomized, multicentre study with 658 adults affected by moderate to severe AD which compared the pimecrolimus risk of skin infection versus topical corticosteroids, failed to demonstrate a higher incidence of skin infections in the pimecrolimus group. However, two cases of EH occurred in the pimecrolimus group (6).

As demonstrated in a recent prospective study, there is a high incidence of asymptomatic or unrecognized symptomatic HS infections in adult patients with AD treated with tacrolimus ointment (4). Thirteen (40%) of 32 patients with a negative HS history had a positive HSV serological test. We herein report a case of EH

after repeated application of pimecrolimus cream for a head-and-neck AD. Even though the causative effect of these topical immunomodulators remains unclear, patients should be taught to recognise HSV infection and stop application to prevent the spreading of the infection.

REFERENCES

1. Reitamo S, Wollenberg A, Schöpf E, Perrot J, Marks R, Ruzicka T, et al. Safety and efficacy of 1 year tacrolimus ointment monotherapy in adults with atopic dermatitis: the European Tacrolimus Ointment Study Group. *Arch Dermatol* 2000; 136: 999–1006.
2. Lübke J, Pournaras CC, Saurat J-H. Eczema herpeticum during treatment of atopic dermatitis with 0.1% tacrolimus ointment. *Dermatology* 2000; 201: 249–251.
3. Ambo M. Relapsing Kaposi's varicelliform eruption and herpes simplex following facial tacrolimus treatment for atopic dermatitis. *Acta Derm Venereol* 2002; 82: 224–225.
4. Lübke J. Adults with atopic dermatitis and herpes simplex and topical therapy with tacrolimus: what kind of prevention? *Arch Dermatol* 2003; 139: 670–671.
5. Wahn U, Bos JD, Goodfield M, Caputo R, Papp K, Manjra A, et al. Efficacy and safety of pimecrolimus cream in long-term management of atopic dermatitis in children. *Pediatrics* 2002; 110: e2.
6. Luger TA, Lahfa M, Fölster-Holst R, Gulliver WP, Allen R, Molloy S, et al. Long-term safety and tolerability of pimecrolimus cream 1% and topical corticosteroids in adults with moderate to severe atopic dermatitis. *J Dermatol Treat* 2004; 15: 169–178.
7. David T, Longson M. Herpes simplex infections in atopic eczema. *Arch Dis Child* 1985; 60: 338–343.
8. Tay Y, Khoo B, Goh C. The epidemiology of atopic dermatitis at a tertiary referral skin center in Singapore. *Asian Pac J Allergy Immunol* 1999; 17: 137–141.
9. Bork K, Bräuninger W. Increasing incidence of eczema herpeticum: analysis of seventy-five cases. *J Am Acad Dermatol* 1988; 19: 1024–2910.
10. Wollenberg A, Zoch C, Wetzel S, Plewig G, Przybilla B. Predisposing factors and clinical features of eczema herpeticum: a retrospective analysis of 100 cases. *J Am Acad Dermatol* 2003; 49: 198–205.
11. Alomar A, Berth-Jones J, Bos JD, Giannetti A, Reitamo S, Ruzicka T, et al. The role of topical calcineurin inhibitors in atopic dermatitis. *Br J Dermatol* 2004; 151: 3–27.
12. Grassberger M, Baumruker T, Enz A, Hiestand P, Hultsch T, Kalthoff F, et al. A novel anti-inflammatory drug, SDZ ASM 981, for the treatment of skin disease: in vitro pharmacology. *Br J Dermatol* 1999; 141: 264–273.
13. Ho VC, Gupta A, Kaufmann R, Todd G, Vanaclocha F, Takaoka R, et al. Safety and efficacy of nonsteroid pimecrolimus cream 1% in the treatment of atopic dermatitis in infants. *J Pediatr* 2003; 142: 155–162.
14. Meurer M, Fartash M, Albrecht G, Vogt T, Worm M, Ruzicka T, et al. Long-term efficacy and safety of pimecrolimus cream 1% in adults with moderate atopic dermatitis. *Dermatology* 2004; 208: 365–372.