

Multiple Skin Metastases of Amelanotic Melanoma Originating from the Sinonasal Mucosa

Teruki Yanagi¹, Masashi Akiyama¹, Maki Kasai¹, Masayuki Yamakura², Mitsufumi Nishio² and Hiroshi Shimizu¹

Departments of ¹Dermatology and ²Internal Medicine, Hokkaido University Graduate School of Medicine, N15W7, Kita-ku, Sapporo 060-8638, Japan. E-mail: yanagi@med.hokudai.ac.jp

Accepted February 21, 2005.

Sir,

Primary sinonasal mucosal melanomas are uncommon, aggressive tumours. Similar to other malignancies, nasal melanomas frequently metastasize to the lymph nodes, lungs, liver and bone. However, skin metastases are very rare (1). We report here a patient with amelanotic melanoma originating from the sinonasal mucosa who rapidly developed multiple skin metastases and the diagnosis was confirmed by a skin biopsy.

CASE REPORT

A 41-year-old Japanese man was referred to our hospital with a sinonasal tumour, systemic lymphadenopathy and multiple subcutaneous nodules. He noticed that his right nostril had become obstructed 10 months before and had suffered repeated episodes of epistaxis a month before. Multiple subcutaneous nodules had appeared 2 months before and they had gradually enlarged and increased in number. Physical examination revealed approximately 30 asymptomatic subcutaneous nodules on his trunk (Fig. 1a). Diffuse lymphadenopathy was also noted. Magnetic resonance imaging demonstrated a large mass occupying the right maxillary sinus and the nasal cavity (Fig. 1b). Computed tomography showed multiple lymphadenopathy throughout his whole body and metastatic tumours in the peritoneum and retro-peritoneal regions.

In laboratory examinations, biochemical tests revealed high lactate dehydrogenase concentrations (512 IU/l, normal 119–229) and high 5-S-cysteinyldopa concentrations in the serum (144.3 nmol/l, normal 1.5–8.0).

Skin biopsy specimens from the upper back showed nests of anaplastic tumour cells in the subcutaneous tissue. Immunohistochemically, the tumour was positive for S-100 and HMB45, although no melanin pigment was observed. The tumour cells only weakly stained for CD56, but were negative for cytokeratins and leukocyte common antigen (Fig. 2). No cutaneous lesion suggestive of primary malignant melanoma was found over the patient's entire body surface and no remarkable history of skin lesions was obtained. From these findings, the diagnosis of amelanotic melanoma of sinonasal mucosal origin with multiple subcutaneous and lymph node metastases was finally made. Right inguinal lymph node biopsy specimens also revealed similar features to those of the subcutaneous nodule, which supported the diagnosis. The tumour was resistant to systemic chemotherapy, and the patient died after 10 weeks' hospitalization due to renal dysfunction caused by tumour invasion.

DISCUSSION

Mucosal melanomas are rare, representing 1.3% of all melanomas, of which 55% were located within the head

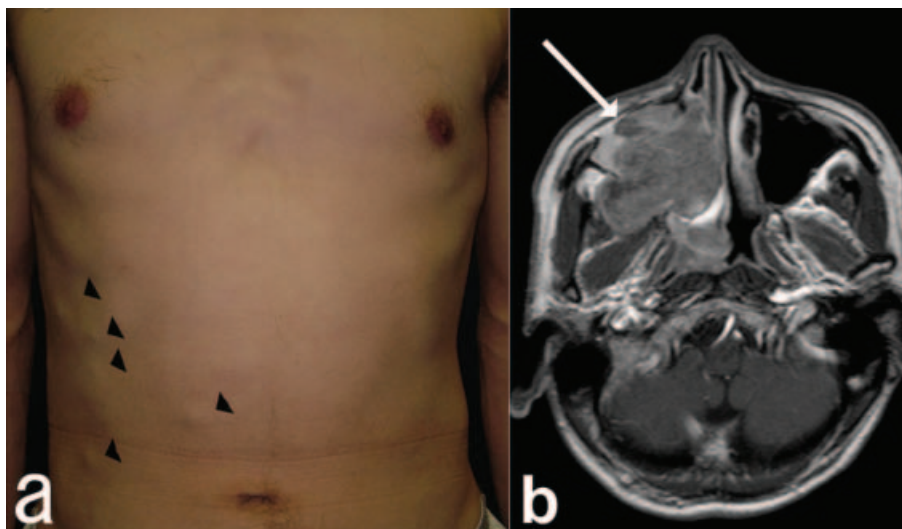


Fig. 1. (a) Multiple subcutaneous nodules (arrowheads) ranging from 0.5 to 1.5 cm in diameter on the trunk. (b) Magnetic resonance imaging of the sinuses demonstrated a large mass (arrow) occupying the right maxillary sinus that had invaded the nasal cavity.

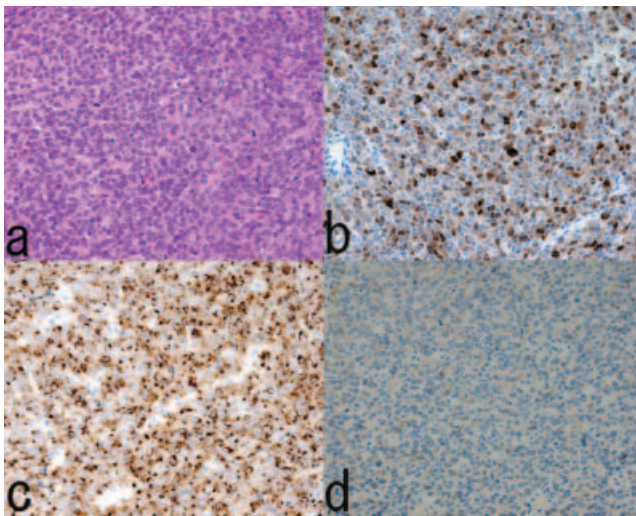


Fig. 2. Histopathological features of the subcutaneous nodule. (a) Dense proliferation of undifferentiated, small to medium sized, atypical cells in the nodule (haematoxylin and eosin). The tumour cells were positive for S-100 protein (b) and HMB45 (c) and were only weakly positive for CD56 (d) (original magnification $\times 40$).

and neck regions (2); 33–67% of these mucosal melanomas found in the head and neck region are amelanotic. This rate is higher than the rate of cutaneous amelanotic melanomas (1, 3, 4). Sinonasal melanomas rarely develop skin metastases, and only one case was found in the literature in which multiple skin metastases occurred 1 year after initial resection of the primary lesion (1, 5). The present case is unique in that

cutaneous metastatic nodules appeared within several months after the patient had noticed nasal congestion, and these skin nodules increased rapidly in number. The definite diagnosis of amelanotic melanoma was made from the histopathological observation of the skin metastatic lesions. The present case suggests that we should bear in mind that sinonasal amelanotic melanoma is one of the differential diagnoses for an aggressive tumour with multiple skin metastatic lesions.

REFERENCES

1. Thompson LD, Wieneke JA, Miettinen M. Sinonasal tract and nasopharyngeal melanomas: a clinicopathologic study of 115 cases with proposed staging system. *Am J Surg Pathol* 2003; 27: 594–611.
2. Chang AE, Karnell LH, Menck HR. The National Center Data Base report on cutaneous and noncutaneous melanoma: a summary of 84,846 cases from the past decade. The American College of Surgeons Commission on Cancer and the American Cancer Society. *Cancer* 1998; 83: 1664–1678.
3. Patel SG, Prasad ML, Escrig M, Singh B, Shaha AR, Kraus DH, et al. Primary mucosal malignant melanoma of the head and neck. *Head Neck* 2002; 24: 247–257.
4. Lengyel E, Gilde K, Remenár É, Esik O. Malignant mucosal melanoma of the head and neck. *Pathol Oncol Res* 2003; 9: 7–12.
5. King DT, Cihak RW, Luther PK, Gurevitch AW, Hirose FM. Malignant neoplasms of the paranasal sinuses involving the skin. *Arch Dermatol* 1978; 114: 1681–1683.