

## INVESTIGATIVE REPORT

# Association of Human Papillomavirus Infection with Palmoplantar Epidermal Cysts in Korean Patients

Hyung-Seok PARK<sup>1</sup>, Won-Serk KIM<sup>1</sup>, Joo-Heung LEE<sup>1</sup>, Jun-Mo YANG<sup>1</sup>, Eil-Soo LEE<sup>1</sup>, Kee-Taek JANG<sup>2</sup>, Dae-Shick KIM<sup>2</sup> and Dong-Youn LEE<sup>1</sup>

Departments of <sup>1</sup>Dermatology and <sup>2</sup>Diagnostic Pathology, Sungkyunkwan University School of Medicine, Samsung Medical Center, Seoul, Korea

**Human papillomavirus (HPV) infection can develop into many different kinds of diseases ranging from simple warts to carcinoma *in situ*. Some investigators have recently suggested that HPV infection could be closely related to palmoplantar epidermal cysts. The aim of this study was to determine the existence of HPV and its subtype in palmoplantar epidermal cysts of Korean patients. We investigated 13 cases of palmoplantar epidermal cysts by employing clinical, histopathological and immunohistochemical examinations. In addition, PCR was performed using HPV 57 and 60 type primers. Four of the 13 cases (30.8%) showed the distinct histopathological features of palmoplantar epidermal cysts such as parakeratosis, vacuolar structures and eosinophilic inclusion bodies and these 4 cases showed positive immunohistochemical staining reactions for HPV. PCR for HPV detected type 60-positive bands in 5 of the 13 cases (38.5%), which included the 4 cases that were positive for immunohistochemical staining. These results show that HPV is associated with some cases of palmoplantar epidermal cysts in Korean patients, suggesting that HPV may play a role in the pathogenesis of these cysts. *Key words: immunohistochemical staining; polymerase chain reaction.***

(Accepted January 14, 2005.)

Acta Derm Venereol 2005; 85: 404–408.

Dong-Youn Lee, Department of Dermatology, Samsung Medical Center, Sungkyunkwan University School of Medicine, 50 Ilwon-dong, Kangnam-gu, Seoul, 135-710, Korea. E-mail: dylee@smc.samsung.co.kr

Epidermal cysts occur at every site of the body, especially on the face, scalp, neck and trunk, and they occasionally occur on the palms or soles. These cysts are usually the result of inflammation around a pilosebaceous follicle (1). However, because there are no pilosebaceous follicles on the palms and soles, palmoplantar epidermal cysts (PPECs) may arise through a different pathogenic mechanism, such as deep implantation of an epidermal fragment as a result of a blunt penetrating injury (1). Yet the pathogenic mechanism of PPECs is still controversial.

Since 1987, there has been evidence presented that human papillomavirus (HPV) is closely related to the

occurrence of both palmar (2) and plantar (3–8) epidermal cysts, especially HPV types 57 and 60 (9–11).

In order to determine the existence of HPV and its subtypes in PPECs in Korean patients, we examined the clinicopathological findings of PPECs, and investigated the presence of HPV utilizing both immunohistochemical staining and polymerase chain reaction (PCR) methods.

## MATERIALS AND METHODS

### *Patients*

The study population comprised 13 patients (6 women and 7 men, aged 17–76 years, mean 35.1) with biopsy-confirmed PPECs that were examined at the Department of Dermatology, Samsung Medical Center between 1994 and 2003. We reviewed the hospital records and histopathological slides of these patients. Clinical data such as sex, age, occupation, duration, location of skin lesion, associated symptoms and previous history of trauma were reviewed.

### *Histopathology and immunohistochemistry*

All tissue specimens were obtained with punch or excisional biopsy, and then they were fixed in formalin and embedded in paraffin. The biopsy specimens were examined with haematoxylin and eosin (H&E) staining for the characteristic findings of epidermal cysts as well as those of HPV infection such as parakeratosis, vacuolar structures and eosinophilic inclusion bodies. We performed immunohistochemical staining as reported elsewhere (12) by the avidin-biotin complex method (DAKO Co., Carpinteria, CA, USA) using a monoclonal HPV antibody (DAKO Clone K1H8) that recognizes HPV capsid protein. Peroxidase activity was developed in diaminobenzidine solution with hydrogen peroxide.

### *PCR*

DNA was extracted from paraffin-embedded blocks of 13 patients with PPECs. Ten paraffin sections from each of the patients were collected, deparaffinized with xylene and washed with ethanol. The deparaffinized tissues were digested in an extraction buffer containing 10 mM of Tris-HCl (pH 8.0), 1 mM of EDTA, 0.5% Tween 20 and 400 µg/µl of proteinase K for 12 h at 55°C. After inactivation of proteinase K by boiling, DNA was extracted by Tris-saturated phenol/ chloroform/isoamyl alcohol and ethanol precipitation.

Three PCR primers were used as follows: the consensus primer for HPV types 1, 2, 3, 4, 5, 6b, 7, 8, 9, 10a, 11, 12, 14a, 16, 17, 18, 19, 20, 21, 22, 24, 25, 31, 33, 36, 37, 38, 39 and 46 was a 23-mer for the E1 open reading frame (13), and the other two were primers for HPV 57 and 60, as designed from the L1

region of each type (14). The sequence and position of these primers were synthesized by Bioneer Corporation (Seoul, Korea) (Table I). PCR amplifications of the 13 samples were performed using the following method. DNA samples were amplified in a 50- $\mu$ l reaction mixture containing 50 mM of KCl, 10 mM of Tris HCl (pH 9.0), 1.5 mM of MgCl<sub>2</sub>, 0.1% Triton-100, 200  $\mu$ M of each dNTP, 2 U of Taq DNA polymerase (Promega), 50  $\mu$ M of consensus primer and 50  $\mu$ M of HPV 57 and 60 primers, respectively. DNA samples were added, and the mixture was overlaid with several drops of mineral oil. Amplification consisted of 30 cycles of denaturation at 94°C for 30 s, primer annealing at 58°C for 90 s and elongation at 72°C for 90 s. The initial denaturation step was lengthened to 5 min, and the final elongation was carried out for 5 min. The PCR products were then electrophoresed in 2% agarose gel. The obtained PCR product was ligated with a TA cloning vector (SRL Inc., Tokyo, Japan) and subjected to cycle sequencing as recommended in the DIG sequencing kit manual (Boehringer Mannheim GmbH, Mannheim, Germany). The resulting sequencing data were aligned with data obtained from GENE bank using a Basic Local Alignment Search Tools (BLAST) program through the internet.

## RESULTS

### Clinical findings

The median duration of the lesions before biopsy was 5 months (Table II). All cases presented as a solitary

dermal or subcutaneous nodule (Fig. 1), which in most cases developed on the weight-bearing areas of the foot and was tender in nine cases. We could not find any relationship between the PPECs and the subject's occupation. Only one patient (case 4) had a previous history of trauma at the site of the lesion.

### Histopathology and immunohistochemistry

A true cyst with a wall composed of epithelium was seen in all cases. Four cases of the 13 PPECs additionally showed distinct histopathological features that were suggestive of HPV infection including parakeratosis, vacuolar structures and eosinophilic inclusion bodies in the cyst wall and within the keratinous mass (see Fig. 2 for representative examples). Additionally, seven cases showed at least one feature of HPV infection (see Table II). Only two cases displayed no evidence at all of HPV infection.

On immunohistochemical analysis, the HPV capsid antigen was demonstrated in the four cases (30.8%) that showed distinctive histopathological features of HPV infection. Positive staining was found in the vacuolated structures in the horny layer and in the nuclei of the cells with intracytoplasmic inclusion bodies, even though not

Table I. Sequences and positions of PCR primers

Primer	Sequences	bp position
HPV CP(S) F	5'- ATATTGTCTGAGCCTCC(A,T)AA(A,G)TT -3'	1744-1722
HPV CP(S) B	5'- ATGTTAAT(A,T)(G,C)AGCC(A,T)CCAAAATT -3'	1770-1748
HPV CP B	5'- TTATCA(A,T)ATGCCCA(C,T)TGACCAT -3'	1796-1774
HPV 57F	5'- GCGCAGGGAGCAAATGTTC -3'	6491-6509
HPV 57B	5'- GCCCTCCGAGCCAGTA -3'	6685-6669
HPV 60F	5'- TAGCACACICTGATAAAC -3'	6233-6253
HPV 60B	5'- ATGGCGT1ACTGTCTAAA -3'	6519-6499

Table II. Summary of clinical data, histopathological, immunohistochemical and PCR results of 13 patients

	Sex/Age (years)	Occup.	Duration (months)	Location	Sympt.	History of		Histologic findings				PCR* (type 60)
						Trauma	Warts	PK	VW	IEB	IHC	
1	F/32	HW	6	ACS	Pain	No	No	+	+	+	+	+
2	F/55	HW	6	AMS	Pain	No	No	+	+	+	+	+
3	M/17	ST	4	AMS	Pain	No	No	+	+	+	+	+
4	M/53	OW	18	VBT	Pain	Yes	No	-	-	-	-	-
5	F/21	OW	2	VBT	Pain	No	No	+	-	-	-	-
6	F/43	HW	3	AMS	None	No	No	+	-	-	-	-
7	M/23	ST	12	ACS	Pain	No	No	-	-	-	-	-
8	M/17	ST	?	Heel	Pain	No	Yes	-	+	-	-	-
9	F/26	ST	4	ALS	None	No	No	+	+	-	-	+
10	M/34	OW	?	Palm	None	No	Yes	-	+	-	-	-
11	F/76	HW	?	AMS	None	No	No	+	-	-	-	-
12	M/29	OW	6	ACS	Pain	No	No	+	-	-	-	-
13	F/30	HW	2	VBT	Pain	No	No	+	+	+	+	+

HW, housewife; ST, student; OW, office worker; L, location of PPECs; ACS, anterior central area of the sole; ALS, anterior lateral area of the sole; AMS, anterior medial area of the sole; VBT, ventral area of the big toe; PK, parakeratotic nuclei; VW, vacuolation of cyst wall; IEB, intracytoplasmic eosinophilic bodies; IHC, immunohistochemical staining; PCR, polymerase chain reaction.

\*All patients were negative for HPV type 57 on PCR.

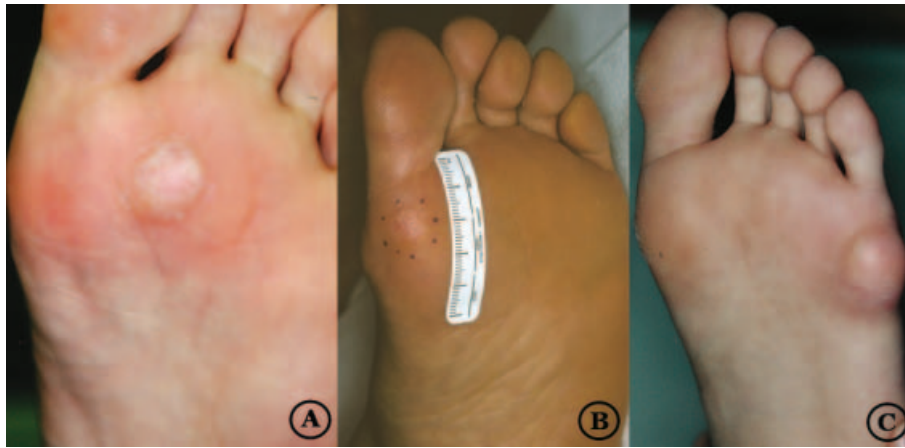

Fig. 1. Clinical features of palmoplantar epidermal cysts (A) Solitary, skin-coloured elevated cystic mass on the anterior surface of the sole in case 1; (B) anterior surface of the sole in case 2; (C) lateral surface of the sole in case 9.

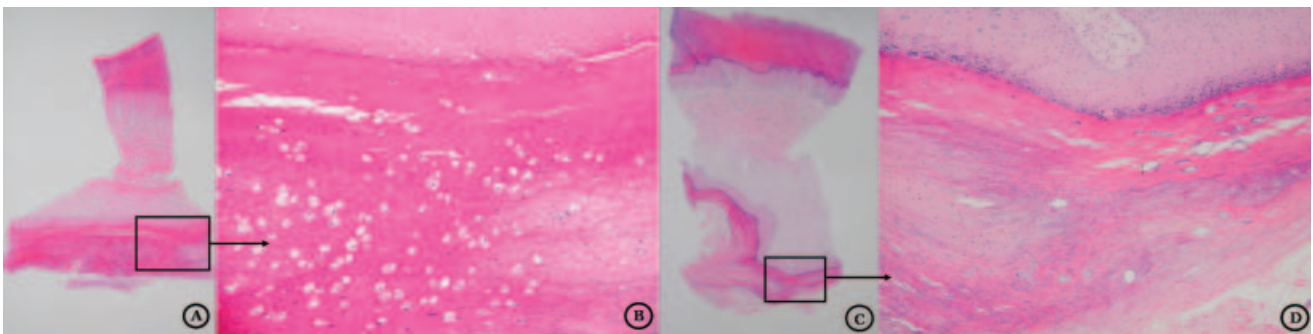


Fig. 2. Vacuolated cells and eosinophilic inclusion bodies are seen in the granular and horny layer of the cyst wall and there is parakeratosis in the keratinous mass within the cyst cavity (H&E: A and B case 1,  $\times 12.5$ ; C and D case 3,  $\times 100$ , respectively).

all of the cells were positive (see Fig. 3 for representative examples).

*PCR results*

The PCR product obtained from PPECs was strongly amplified with the HPV 60 primers in 5 cases of 13 PPECs (38.5%), whereas type 57 HPV and consensus primers were consistently negative (Fig. 4 and Table II). Each of the amplified DNA fragments was confirmed as HPV 60 by DNA sequencing and homology search. Cases 1, 2, 3 and 13 were thus positive for HPV in all aspects except for HPV type 57. Case 9 was positive for HPV 60 on PCR but showed only two features of HPV infection and was negative for HPV on immunochemistry.

**DISCUSSION**

It is generally accepted that most spontaneously arising epidermal cysts might be related to follicular infundibulum (1). However, epidermal cysts can sometimes occur on hairless skin such as the palms and soles, and epidermal cysts constituted 7.2% of plantar lesions in a large histopathological study (15). PPECs have long

been assumed to be derived from implantation of an epidermal fragment due to a penetrating injury or other causes (1, 16).

Since Egawa et al. (3) first reported the association of HPV with plantar epidermal cysts in 1987, most of the HPV-associated PPECs have been reported from Japan (2–6, 8). Matsukura et al. (9) have cloned the viral DNA from plantar epidermal cysts and designated the novel

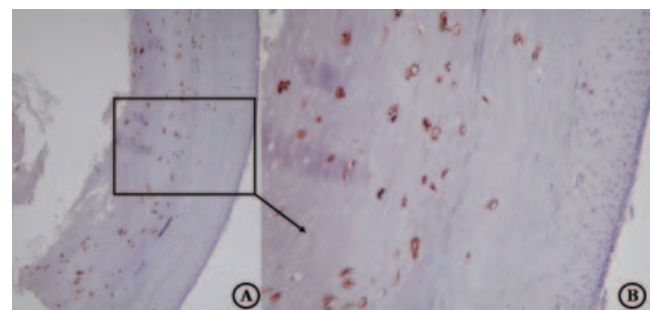


Fig. 3. Positive immunostaining for monoclonal human papillomavirus (HPV) antibody in case 1 is shown in the rims of the vacuoles and the nuclei-like material within the vacuolations of the cyst wall (A,  $\times 40$ ; B,  $\times 100$ ).



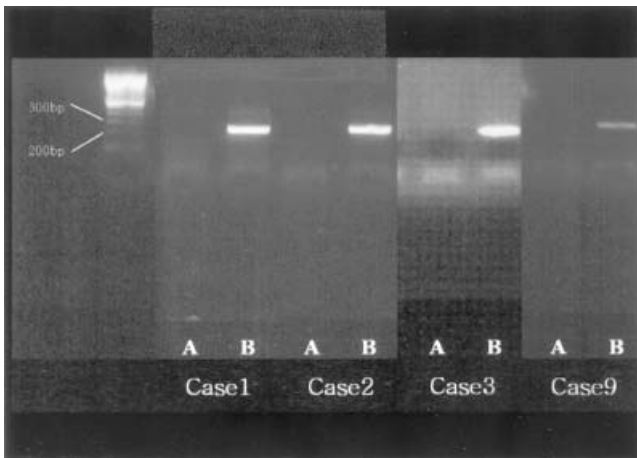


Fig. 4. PCR results: there were positive reactions to type 60 human papillomavirus (HPV) primers (B) but negative reactions to type 57 HPV primers (A) in five cases (case no. 13 is not shown).

HPV type as HPV type 60. It has been suggested that the HPV-associated PPECs have unique clinical and histopathological characteristics, which distinguish them from ordinary traumatic epidermal cysts of the sole (6). First, they are histopathologically characterized by eosinophilic cytoplasmic inclusion bodies in the epithelial cells of the cyst walls and a vacuolar material in the horny layers within the cysts. Second, most of these lesions were observed at pressure points, such as the anterior portion of the foot or heels, and tenderness occurs with only rare exceptions in the relatively young patients. In our experiment, five PCR-confirmed cases matched these characteristics similarly, except there was no subjective symptom in case 9 and case 2 was an older patient.

Although the pathogenesis of PPECs is unknown, a causative association with a newly recognized HPV (especially type 60) has been proposed by some investigators (9, 10, 17). There are at least two alternative explanations for a relation between PPECs and HPV infection (10): one is that the HPV represents a superinfection and the other is that HPV plays an initiating role in the genesis of these cysts. Induction of epidermal cysts by HPV has been reported in mice (18, 19). If the cysts developed on weight-bearing areas of the foot, there may be a possible explanation for the virus to develop PPECs (5). HPV may first induce a wart, and when this is located on the plantar weight-bearing surface, a portion of the wart may penetrate into the dermis and induce cyst formation. If the overlying wart subsequently undergoes regression, then only a dermal cyst would remain. As regards our results, preceding warts existed in two cases, which might imply superinfection. The PPECs were mainly located on weight-bearing areas of the foot in 12 of 13 cases; this favours the innate causative role of HPV infection. Some authors have insisted (4, 17) that PPECs might develop

from the eccrine duct due to HPV infection, and not from epidermal implantation. However, immunohistochemical observation of cytokeratin expression in PPECs did not support the eccrine ductal origin (20).

In addition to HPV 60 in PPECs, HPV 57 has also been recently identified in PPECs (11, 14).

When comparing the immunohistochemical and PCR results, using immunohistochemistry, we detected four cases of PPECs reactive to monoclonal HPV 60 antibody, and we could find one more such case by the PCR method. These findings imply that the PCR method can be a more sensitive tool and negative immunohistochemistry obviously does not exclude the presence of HPV, because the cells may not show the complete structural assembly of viral particles necessary for their visualization.

#### ACKNOWLEDGEMENT

We wish to extend our thanks to Hyuk-Chul Kwon for his valuable technical assistance.

#### REFERENCES

1. Kirkham N. Tumors and cysts of the epidermis. In: Elder D, Elenitsas R, Jaworsky C, et al., eds. *Lever's histopathology of the skin*, 8th edn. Philadelphia: Lippincott-Raven, 1997: 694–695.
2. Egawa K, Inaba Y, Honda Y, Johno M, Ono T. 'Cystic papilloma': human papillomavirus in a palmar epidermoid cyst. *Arch Dermatol* 1992; 128: 1658–1659.
3. Egawa K, Ono T, Arai T. Epidermoid cyst of the sole and human papillomavirus. *Jpn J Dermatol* 1987; 97: 493–495.
4. Yanagihara M, Sumi A, Mori S. Papillomavirus antigen in the epidermoid cyst of the sole. *J Cutan Pathol* 1989; 16: 375–381.
5. Egawa K, Inaba Y, Ono T, Arai T. 'Cystic papilloma' in humans?: demonstration of human papillomavirus in plantar epidermoid cysts. *Arch Dermatol* 1990; 126: 1599–1603.
6. Kato N, Ueno H. Two cases of plantar epidermal cyst associated with human papillomavirus. *Clin Exp Dermatol* 1992; 17: 252–256.
7. Rios LM, Fraga FJ, Fernandez HJ. Human papillomavirus in an epidermoid cyst of the sole in a non-Japanese patient. *J Am Acad Dermatol* 1992; 27: 364–366.
8. Mihara M, Nishiura S, Aso M, Shimao S, Nakakuki S. Papillomavirus-infected keratinous cyst on the sole. *Am J Dermatopathol* 1994; 13: 293–299.
9. Matsukura T, Iwasaki T, Kawashima M. Molecular cloning of a novel human papillomavirus (type 60) from a plantar cyst with characteristic pathological changes. *Virology* 1992; 190: 561–564.
10. Kawase M, Honda M, Niimura M. Detection of human papillomavirus type 60 in plantar cysts and verruca plantaris by in situ hybridization method using digoxigenin labeled probes. *J Dermatol* 1994; 21: 709–715.
11. Kitasato H, Egawa K, Honda Y, Ono T, Mizushima Y, Kawai S. A putative human papillomavirus type 57 new subtype isolated from plantar epidermoid cysts without intracytoplasmic inclusion bodies. *J Gen Virol* 1998; 79: 1977–1981.

12. Iwasaki T, Santana T, Sugase M, Sato Y, Kurata T, Suzuki K, et al. Detection of capsid antigen of human papillomavirus (HPV) in benign lesions of female genital tract using anti-HPV monoclonal antibody. *J Pathol* 1992; 168: 293–300.
13. Tieben LM, Schegget J, Minnaar RP, Bouwes Bavinck JN, Berkhout RJ, Vermeer BJ, et al. Detection of cutaneous and genital HPV types in clinical samples by PCR using consensus primers. *J Virol Methods* 1993; 42: 265–279.
14. Egawa K, Kitasato H, Honda Y, Kawai S, Mizushima Y, Ono T. Human papillomavirus 57 identified in a plantar epidermoid cyst. *Br J Dermatol* 1998; 138: 510–514.
15. Berlin SJ. A review of 2720 lesions of the foot. *J Am Podiatry Assoc* 1980; 70: 318–324.
16. Pinkus H. Epidermoid cyst or epidermal inclusion cyst? *Arch Dermatol* 1975; 111: 130.
17. Egawa K, Honda Y, Inaba Y, Ono T, De Villiers EM. Detection of human papillomaviruses and eccrine ducts in palmoplantar epidermoid cysts. *Br J Dermatol* 1995; 132: 533–542.
18. Kreider JW, Howett MK, Wolfe SA, Bartlett GL, Zaino RJ, Sedlacek T, et al. Morphological transformation in vivo of human uterine cervix with papillomavirus from condylomata acuminata. *Nature* 1985; 317: 639–641.
19. Kreider JW, Patrick SD, Cladel NM, Welsh PA. Experimental infection with human papillomavirus type 1 of human hand and foot skin. *Virology* 1990; 177: 415–417.
20. Abe H, Ohnishi T, Watanabe S. Does plantar epidermoid cyst with human papillomavirus infection originate from the eccrine dermal duct? *Br J Dermatol* 1999; 141: 161–162.