

Recurrent Cutaneous Eosinophilic Vasculitis Presenting as Annular Urticarial Plaques

Yuichiro Tsunemi, Hidehisa Saeki, Hironobu Ihn and Kunihiko Tamaki

Department of Dermatology, Faculty of Medicine, University of Tokyo, 7-3-1 Hongo, Bunkyo-ku, Tokyo 113-8655, Japan. E-mail: ytsun-ty@umin.ac.jp

Accepted December 22, 2004.

Sir,

Clinical and histological cutaneous necrotizing vasculitis of dermal small vessels with an almost exclusively eosinophilic infiltration and without any features of the systemic disease has recently been described by Chen et al. as recurrent cutaneous eosinophilic vasculitis (RCEV) (1, 2). This disease is rare and only a few cases have been reported (1–4). We here describe one more case of RCEV presenting as annular urticarial plaques.

CASE REPORT

A 53-year-old Japanese woman presented with a 3-year history of intensely pruritic eruptions without any other systemic symptoms. Various antihistamines had been tried without apparent benefit. She had no history of allergic diseases such as asthma or allergic rhinitis. Physical examination revealed pruritic, urticarial erythematous plaques predominantly located on the extremities with frequent recurrence. The lesions were partly fused and produced an annular arrangement in some parts (Fig. 1). Each lesion lasted for about 10 days and gradually disappeared resulting in brown pigmentation. All the laboratory data were normal including peripheral blood eosinophil counts, erythrocyte sedimentation rate, C-reactive protein, immunoglobulins A, M, G and E, complement levels and tumour markers. Antinuclear antibody, rheumatoid factor, and antibodies for hepatitis B and C viruses were negative. Systemic

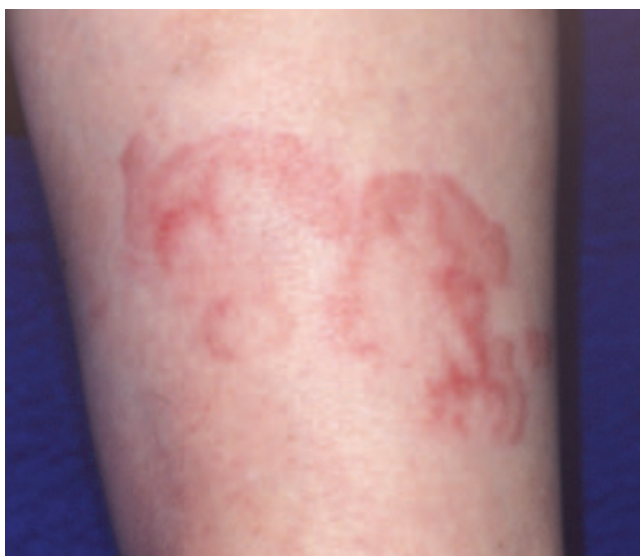

Fig. 1. Urticarial erythematous plaques located on the thigh, showing an annular arrangement in some areas.

examination did not show any evidence of other diseases including malignancies or connective tissue diseases. A biopsy specimen was taken from an urticarial plaque on the right thigh which had appeared 5 days before. It disclosed the infiltration of many eosinophils and some lymphocytes around the dermal small vessels and destructive alteration of the vessels (Fig. 2). There was margination of eosinophils in the vessel lumen and infiltration into vessel walls. There were few neutrophils and no leukocytoclasia. No deposit of immunoglobulins was found by direct immunofluorescence study. The patient was diagnosed as having RCEV and was initially given 15 mg (0.3 mg/kg) of prednisolone daily with a dramatic and immediate improvement in clinical symptoms. The dosage of prednisolone was gradually reduced without any recurrence until a new lesion appeared 8 weeks later when she was taking 7.5 mg of prednisolone daily. Then prednisolone was replaced by 0.75 mg of betamethasone, and the eruptions disappeared. Since then, this dosage has been needed to control the disease.

DISCUSSION

RCEV is a distinct entity characterized by necrotizing vasculitis of small vessels of the skin with almost exclusively eosinophilic infiltration and minimal or no leukocytoclasia (1, 2). It presents with widespread recurrent, pruritic, erythematous or purpuric papules or plaques, or angioedema, and usually is associated with peripheral blood eosinophilia (1, 2). Urticarial

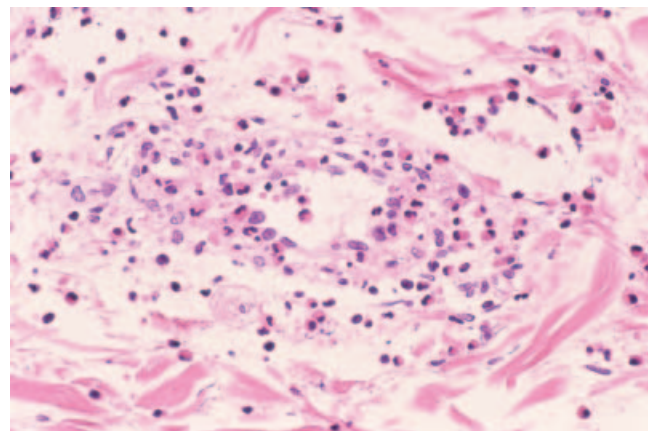


Fig. 23. Infiltration of many eosinophils and some lymphocytes around the dermal small vessels and destructive change of the vessels with margination of eosinophils in the vessel lumen and infiltration into vessel walls (haematoxylin and eosin, $\times 200$).

plaques, palpable purpura and vesicular lesions were also observed (1). The disease follows a benign chronic course without evidence of systemic involvement including allergic disorders, and responds promptly to systemic steroid treatment, but skin lesions recur and require maintenance doses for control of the disease (2). No deposition of immunoglobulins along vessel walls was found (1, 2).

Our case was diagnosed as RCEV because she had necrotizing vasculitis infiltrated predominantly with eosinophils and without leukocytoclasia, or any other systemic involvement. Peripheral blood eosinophilia was not detected in our case. RCEV usually shows peripheral blood eosinophilia (1, 2), but the eosinophil count does not always parallel the severity of the disease and some patients experience cutaneous eruptions without peripheral blood eosinophilia (1). Indeed, Chen et al. (2) did not include eosinophilia among the essential components of this disease.

Histologically, hypereosinophilic syndrome (HES), episodic angioedema with eosinophilia and Well's syndrome may show dermal eosinophilia with perivascular eosinophilic infiltration, but necrotizing vasculitis is absent (5–8). In addition, HES has visceral involvement (5). Churg-Strauss syndrome shows vasculitis infiltrated by eosinophils; however, the affected small dermal vessels in this syndrome reveal leukocytoclastic vasculitis and extravascular granuloma is present (9). Patients with Churg-Strauss syndrome usually have asthma (9). Thus, these diseases could be ruled out in our case. Urticaria presents interstitial dermal oedema and may have perivascular and interstitial mixed cell infiltrate with lymphocytes, eosinophils and neutrophils, but does not show exclusively eosinophilic infiltration (10). In urticaria, each lesion disappears within 24 h (10). Late-phase urticaria (11, 12), in which urticarial eruptions last longer than 24 h, shows perivascular infiltration predominantly of eosinophils, but not endothelial fibrinoid degeneration. Urticarial vasculitis shows recurrent episodes of urticarial lesions which persist for >1 day and resolve with purpura or pigmentation (9). In urticarial vasculitis, the first cell type that appears around the vessels is eosinophil. Eosinophils begin to infiltrate after 3 h, followed by an increase of neutrophils after 10 h and development of leukocytoclastic vasculitis after 24 h (13, 14). In our case, a biopsy was taken from the eruption which appeared 5 days earlier, and revealed necrotizing vasculitis without leukocytoclasia and infiltrated by

many eosinophils and few neutrophils. Thus urticaria, late-phase urticaria and urticarial vasculitis were ruled out. Drug eruption also shows eosinophil infiltration but our patient had not taken any drugs.

Our case presented an annular erythematous lesion similar to a previous case (1). This suggests that annular erythematous lesions are one of the clinical presentations of RCEV.

REFERENCES

1. Chen KR, Pittelkow MR, Su D, Gleich J, Newman W, Leiferman KM. Recurrent cutaneous necrotizing eosinophilic vasculitis. A novel eosinophil-mediated syndrome. *Arch Dermatol* 1994; 130: 1159–1166.
2. Chen KR, Su WP, Pittelkow MR, Leiferman KM. Eosinophilic vasculitis syndrome: recurrent cutaneous eosinophilic necrotizing vasculitis. *Semin Dermatol* 1995; 14: 106–110.
3. Launay D, Delaporte E, Gillot JM, Janin A, Hachulla E. An unusual cause of vascular purpura: recurrent cutaneous eosinophilic necrotizing vasculitis. *Acta Derm Venereol* 2000; 80: 394–395.
4. Sakuma-Oyama Y, Nishibu A, Oyama N, Saito M, Nakamura K, Kaneko F. A case of recurrent cutaneous eosinophilic vasculitis: successful adjuvant therapy with suplatast tosilate. *Br J Dermatol* 2003; 149: 901–903.
5. Weller PF, Buble GJ. The idiopathic hypereosinophilic syndrome. *Blood* 1994; 83: 2759–2779.
6. Moossavi M, Mehregan DR. Wells' syndrome: a clinical and histopathologic review of seven cases. *Int J Dermatol* 2003; 42: 62–67.
7. Gleich GJ, Schroeter AL, Marcoux JP, Sachs MI, O'Connell EJ, Kohler PF. Episodic angioedema associated with eosinophilia. *N Engl J Med* 1984; 310: 1621–1626.
8. Wolf C, Pehamberger H, Breyer S, Leiferman KM, Wolff K. Episodic angioedema with eosinophilia. *J Am Acad Dermatol* 1989; 20: 21–27.
9. Crowson AN, Mihm MC Jr, Magro CM. Cutaneous vasculitis: a review. *J Cutan Pathol* 2003; 30: 161–173.
10. Zuberbier T. Urticaria. *Allergy* 2003; 58: 1224–1234.
11. Kambe N, Kitao A, Nishigori C, Miyachi Y. Late-phase urticaria. Update. *Curr Allergy Asthma Rep* 2002; 2: 288–291.
12. Kitao A, Nobuhara S, Kore-Eda S, Takahashi K, Nishigori C, Miyachi Y. Persistent urticaria – urticarial reaction caused by late phase reaction? *Eur J Dermatol* 2001; 11: 440–442.
13. Kano Y, Orihara M, Shiohara T. Cellular and molecular dynamics in exercise-induced urticarial vasculitis lesions. *Arch Dermatol* 1998; 134: 62–67.
14. Kano Y, Orihara M, Shiohara T. Time-course analyses of exercise-induced lesions in a patient with urticarial vasculitis. *Australas J Dermatol* 1996; 37: S44–S45.