

Localized Retiform Purpura after Accidental Intra-arterial Injection of Polidocanol

Mireia Yébenes¹, Montserrat Gilaberte¹, Agustí Toll¹, Carlos Barranco² and Ramon M. Pujol^{1*}

Departments of ¹Dermatology and and ²Pathology, Hospital del Mar, IMAS, Passeig Marítim 25-29, ES-08003-Barcelona, Spain.

*E-mail: rpujol@imas.imim.es

Accepted December 6, 2004.

Sir,

Non-inflammatory retiform (net-like or livedoid) purpura (NIRP) is a clinical pattern produced by small vessel occlusion in dermis. Several disorders such as coagulation abnormalities, cold-related gelling, micro-organism vessel invasion or embolization leading to microvascular occlusion may share in common a clinical picture of localized or generalized NIRP (1). NIRP lesions are usually sharply demarcated and sometimes erythematous plaques, from a few millimetres to many centimetres in size, which subsequently become necrotic. The livedoid appearance can be diffuse or localized at the margins of large necrotic purpuric lesions. Early lesions tend to have minimal or no erythema, whereas in more advanced lesions, necrosis takes place. We report here a case of localized NIRP after intra-arterial injection of polidocanol during treatment for lower limb varicosities.

CASE REPORT

An otherwise healthy 36-year-old woman was referred to our department for evaluation of a purpuric plaque that developed on the inner aspect of the right thigh 48 h after the last injection of sclerotherapy with polidocanol 0.5% (Ethoxysclerol[®]) for superficial varicose veins on the lower extremities. Immediately after the injections, the patient complained of an intense pain in the inner aspect of the right leg. She also noted a cutaneous reaction with oedema and blanching at the injection site. During the following hours, an erythematous plaque

appeared, which enlarged rapidly and progressed to a purpuric plaque.

Physical examination disclosed a sharply demarcated, livedoid, purpuric violaceous plaque, 12 × 8 cm in diameter, with peripheral dendritic extensions on the inner aspect of the right thigh (Fig. 1a). At the centre of the plaque, coincident with the injection site, a necrotic area, 1 cm in diameter, was noted. The physical examination was otherwise unremarkable. An ECO-Doppler examination disclosed no venous system abnormalities. A complete coagulation laboratory survey was normal.

Histological examination of a skin biopsy demonstrated thrombosis involving a medium-sized vessel in the reticular dermis, without damage of the vascular wall. An elastic fibre stain demonstrated arterial features in the actual vessel (Fig. 1b).

The lesion improved over the following 4 weeks with local antiseptic treatment and oral analgesics. No crusting was noted. After 2 months, the lesion had resolved completely, leaving a hyperpigmented and atrophic macule.

DISCUSSION

Sclerotherapy is an established medical procedure for both small and large varicose veins of the superficial venous system and perforators. A sterile solution is injected into the lumen of a vein for the induction of endothelial and subendothelial irritation, causing irreversible full-thickness mural denaturation, fibrosis and the obliteration of the vessel (2).

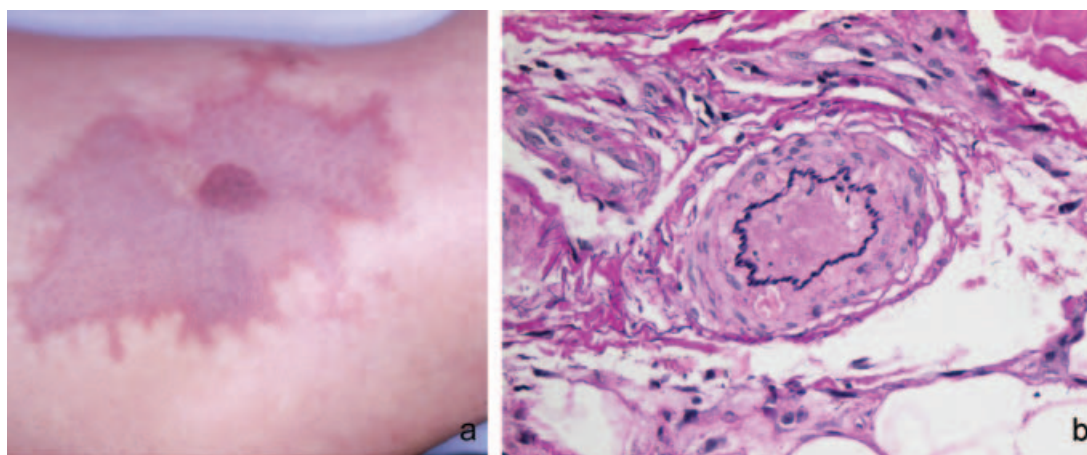


Fig. 1. (a) Sharply demarcated, purpuric plaque, 12 × 8 cm, on the inner aspect of the right leg. (b) Thrombosis involving a medium-sized vessel in the reticular dermis (elastic fibre stain × 200).

Complications of sclerotherapy are not too rare, and include post-treatment hyperpigmentation (10–30%), bruises at the injection sites, telangiectatic matting (15%), cutaneous necrosis, superficial thrombophlebitis, deep venous thrombosis, nerve injury, and vasovagal and allergic reactions (3).

Cutaneous necrosis is a rare side effect of sclerotherapy. It can be the result of extravasation of the sclerosing solution into the perivascular tissues, secondary reactive vasospasm of the vessel, or injection into a dermal arteriole, close to a telangiectatic or varicose vein. Intra-arterial injection is one of the most serious complications of sclerotherapy, which may range from no sequelae to necrosis of the skin, subcutaneous tissue and/or muscle (4). Inadvertent injection into dermal arterioles may be the most common cause of cutaneous ulceration (5).

Cutaneous necrosis may develop after injections of any sclerosing drug and can occur after optimal conditions of application, even when ultrasound guidance is used. High risk areas for intra-arterial injection include posterior medial malleolar region, perforators, saphenofemoral and saphenopopliteal junctions.

Embolia cutis medicamentosa, livedo-like dermatitis or Nicolau's syndrome is an unusual entity secondary to the accidental intra-arterial or periarterial injection of a drug, with subsequent arterial vasospasm and cutaneous necrosis. Several drugs, including bismuth salts, non-steroidal anti-inflammatory drugs, local anaesthetics, antihistamines, corticosteroids and vitamin B complexes have been incriminated (6).

Clinically, livedoid dermatitis is manifested by the development of an acute localized erythematous rash during intramuscular injection, leading to a solitary reticular violaceous-purpuric plaque, with peripheral dendritic extensions, intense local pain and evolution towards more or less extended cutaneous necrosis.

In our patient, cutaneous necrosis probably developed as the consequence of the occlusion of the feeding dermal arteriole after superficial polidocanol injections. Polidocanol is a widely used sclerosing agent that is frequently used for treatment of varicose veins or telangiectasias. It is characterized by its spasmogenic action on veins, good local tolerance and low incidence of side effects. As far as we know only two (7, 8) other cases of cutaneous livedoid dermatitis secondary to polidocanol injection have been reported previously.

Several topical treatments (antibiotics, hydrocolloid dressings) and/or vasoactive agents have been

postulated as effective therapeutic approaches (9). Heparin and fibrinolytic therapy have been reportedly beneficial in the treatment of intra-arterial injections of a variety of substances (10, 11).

In conclusion, development of localized non-inflammatory retiform purpuric lesions after sclerotherapy for superficial telangiectasias or varicose veins should alert the clinician to the possibility of an intra-arterial or periarterial injection. An increased awareness regarding this possible complication seems necessary in order to adopt an early therapeutic approach.

REFERENCES

1. Robson KJ, Piette WW. The presentation and differential diagnosis of cutaneous vascular occlusion syndromes. *Adv Dermatol* 1999; 15: 153–182.
2. Defouilloy I, Lok C. La sclérothérapie des varices des membres inférieurs. *Ann Dermatol Venereol* 2003; 130: 378–380.
3. Goldman MP, Sadick NS, Weiss RA. Cutaneous necrosis, telangiectatic matting, and hyperpigmentation following sclerotherapy. Etiology, prevention and treatment. *Dermatol Surg* 1995; 21: 19–29.
4. Biegeleisen K, Neilsen RD, O'Shaughnessy A. Inadvertent intra-arterial injection complicating ordinary and ultrasound-guided sclerotherapy. *J Dermatol Surg Oncol* 1993; 19: 953–958.
5. DeFaria JL, Moraes IN. Histopathology of telangiectasias associated with varicose veins. *Dermatologica* 1963; 127: 321–329.
6. Trinh-Khac JP, Roux A, Djandji, Aractingi S. Dermite livedoïde de Nicolau après sclérothérapie de varices. *Ann Dermatol Venereol* 2004; 131: 481–485.
7. Beissert S, Presser D, Rutter A, Retze D, Luger TA, Schwarz T. Embolia Cutis Medicamentosa (Nicolau syndrome) nach intraartikulärer Injection. *Hautarzt* 1999; 50: 214–216.
8. Geukens J, Rabe E, Bieber T. Embolia cutis medicamentosa of the foot after sclerotherapy. *Eur J Dermatol* 1999; 9: 132–133.
9. Ruffieux P, Salomon D, Saurat JH. Livedo-like dermatitis (Nicolau's syndrome): a review of three cases. *Dermatology* 1996; 193: 368–371.
10. Bounameaux H, Schneider PA, Huber-Sauteur E, Jolliet P. Severe ischemia of the hand following intra-arterial promazine injection: effects of vasodilation, anticoagulation, and local thrombolysis with tissue-type plasminogen activator. *Vasa* 1990; 19: 68–71.
11. Andreev A, Kavrakov T, Petkov D, Penkov P. Severe acute hand ischemia following an accidental intraarterial drug injection, successfully treated with thrombolysis and intraarterial iloprost infusion. *Angiology* 1995; 10: 963–967.