

## In this issue...

### End of the *Malassezia* story in atopic dermatitis?

In a detailed article Dr. Sandström Falk et al. observe that *Malassezia* yeasts are significantly less common on lesional skin of atopic eczema compared to both non-lesional skin, and to patients with seborrheic eczema or healthy controls. Further, they observe no relationship between presence of *Malassezia* and clinical disease activity of atopic eczema. And finally they demonstrate that the patients with negative cultures of *Malassezia* actually significantly more often have positive skin prick tests to extract of *Malassezia*. This finding should be coupled with the fact that topical treatment specifically aimed at removing *Malassezia* from the skin could not improve the clinical eczema activity compared with hydrocortisone crème alone (1). End of the *Malassezia* story in atopic dermatitis? I will let the readers decide, but I am not surprised. Atopic eczema is a very complicated disease and the role of allergies seems to be less and less important. These are harsh words in the ears of an allergologist. A small story: I once had the pleasure of meeting Dr. S. G. O. Johansson in his office at the Karolinska Institute and told him that I strongly felt “allergies” were secondary phenomena in atopic dermatitis. He looked at me, paused for a few seconds and said: “This is like swearing in Church”. I congratulate the authors for being brave and presenting their facts, which should make us consider on the use of anti-fungal therapy in atopic dermatitis. Also, we should consider to stop testing as there seems to be no therapeutical consequences of doing so.

#### REFERENCE

1. Böhme M, Lannerö E, Wickman M, Nordvall SL, Wahlgren C-F. Atopic dermatitis and concomitant disease patterns in children up to two years of age. *Acta Derm Venereol* 2002; 82: 98–103.

*Kristian Thestrup-Pedersen*  
Section Editor

### There is no black & white of innate photo protection!

Patients with vitiligo lack melanocytes in their lesional epidermis, hence the depigmentation and increased skin sensitivity to ultraviolet radiation (UVR). But is this the

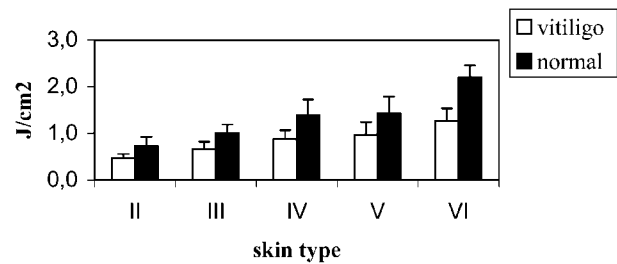


Fig. 1. Minimal erythema dose (mean  $\pm$  SD) vs skin type in vitiligo lesional and non-lesional skin. Taken from the original article on p. 24.

whole story? If so one would expect that vitiliginous skin of all affected persons would be equally hypersensitive to UVR, irrespective of which sun-reactive skin photo types (SPT I–VI) they belong to. To the contrary, on page 24 of this issue, Wiete Westerhof and his team in Amsterdam show that the minimal erythema dose (MED) for UVB 311 nm radiation in vitiligo lesions increased from 0.5 J/cm<sup>2</sup> in SPT II patients (often sunburned, seldom tanned) to 1.3 J/cm<sup>2</sup> in SPT VI patients (dark skinned). Somewhat surprisingly, they also found that the ratio of MED in non-lesional vs lesional skin was similar in all patients (about 1.5), which tells us that the vitiligo lesions are only on average 30% more UV-sensitive than the surrounding normal skin.

The studies were conducted on patient skin that had not been exposed to UVR for the last 3 months, so skin thickening cannot be responsible for the observed effect. Instead the authors propose that non-melanin factors, such as the antioxidant status of the skin, are important as co-protectors against UVR. Additionally the threshold to inflammation may be higher in skin of individuals with high SPT. Data in the literature shows that application of a toxic compound like sodium lauryl sulphate more easily produces irritation in fair skin than in dark skin. Analogously identical amounts of UVR-induced damage to keratinocytes in fair and dark skin, respectively, might possibly result in a stronger inflammatory response in the former case, thus contributing to the lower MED in vitiligo lesions of SPT II as compared to SPT VI persons. Clearly this aspect of cutaneous photobiology needs to be further investigated.

*Anders Vahlquist*  
Editor-in-Chief