

Complete Remission of Recalcitrant Viral Warts under Oral Isotretinoin in a Patient with Low-grade B-cell Lymphoma

Alexandra Monastirli¹, Panayiota Matsouka², Efi Pasmatzli¹, Maria Melachrinou³, Sophia Georgiou¹, Elena Solomou², Nicholas Zoumbos² and Dionysios Tsambaos¹

Departments of ¹Dermatology, ²Hematology and ³Pathology, School of Medicine, University of Patras, PO Box 1413, Rio-Patras 265 04, Greece. E-mail: almonast@med.upatras.gr

Accepted November 4, 2004.

Sir,

Viral warts are the most frequent clinical manifestations of the ubiquitous human papillomaviruses (HPV) infection. Particularly in immunocompromised patients they may become extensive in both size and area of involvement, representing a frustrating problem, and can progress to squamous cell carcinomas (1, 2). We report herein the complete remission of recalcitrant and extensive warts in a patient with low-grade B-cell small lymphocytic lymphoma under treatment with oral isotretinoin (13-cis retinoic acid).

CASE REPORT

A 31-year-old HIV-negative Caucasian man with a 4-year history of both-sided submaxillary and cervical lymph node enlargement and an 8-year history of warty skin lesions presented to the outpatient Hematology Department at our University Medical Center. Physical examination revealed submaxillary, cervical/superclavicular lymph nodes in blocks of size 2 × 2 cm and 3 × 4 cm, respectively, whereas enlarged lymph nodes were palpable in the axillary and inguinal region, as well. Additionally, multiple, large and confluent hyperkeratotic viral warts were found on the dorsal aspect of

both hands (Fig. 1A) and on the neck spreading over the beard area. Repeated earlier treatments with various modalities had resulted in a temporary remission of these skin lesions.

At admission, the counts of peripheral blood were: Ht 47, leukocytes 28000/dl; differential count: polymorphs 26%, lymphocytes 70%, monocytes 2%, eosinophils 6% and platelets 169,000/dl. Flow cytometry of peripheral blood revealed a B-clonal lymphocytosis (CD3+ 24%, CD20+ 58%, CD19+ 64%, CD20+/CD5+ 58%). Blood chemistry and serological tests were within normal limits. Whole body computed tomography confirmed the enlargement of peripheral lymph nodes. Histological examination of a skin biopsy revealed the typical features of common warts, i.e. hyperkeratosis and orthokeratosis with parakeratotic columns over the tops of the papillae, acanthosis, papillomatosis, keratohyalin condensation and perinuclear vacuolization, whereas *in situ* hybridization revealed the occurrence of HPV-2 DNA. The biopsy of an enlarged cervical lymph node revealed the morphological and immunohistochemical features of B-cell small lymphocytic lymphoma/chronic lymphocytic leukaemia (B-SLL/CLL) according to REAL and WHO classification with a CD20+, Bcl-2+, CD23+ and CD5+ phenotype. Bone marrow biopsy showed a nodular involvement from small B-cells with an identical phenotype and a low proliferation index (<5%).

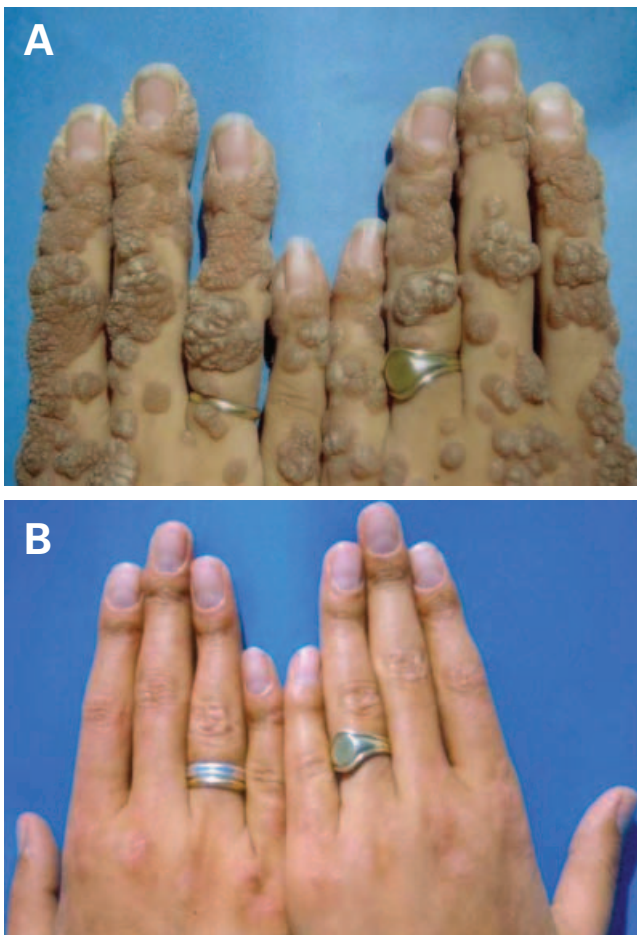


Fig. 1. Clinical aspect of extensive viral warts on both hands (A) prior to and (B) 10 weeks after the onset of isotretinoin therapy.

Cytogenetic investigations revealed a normal karyotype (46,XY).

Our therapeutic decision was 'to watch and wait'. However, during the subsequent 17-month follow-up without any treatment a gradual further enlargement of the affected lymph nodes and the occurrence of splenomegaly were observed. Thus, we decided to start treatment with rituximab (anti-CD-20 humanized monoclonal antibody) at a dose of 375 mg/m² by intravenous infusion weekly for 4 consecutive weeks, then monthly (six courses) and finally once every 3 months for six further courses as maintenance therapy. Therapy was well tolerated and side effects were limited to infusion-related symptoms such as fever, chills and flushing.

In contrast to the gradual regression of the lymph nodes of the patient seen under treatment with rituximab, his warty skin lesions clearly showed a marked progression; 8.5 months after the onset of rituximab monotherapy, the deterioration of his dermatological status prompted us to initiate oral administration of isotretinoin (1 mg/kg/day). Six weeks after the onset of isotretinoin treatment, an impressive therapeutic response of the patient to this retinoid was seen, characterized by a marked reduction in the number and size of the extensive viral warts; the latter completely disappeared after 10 weeks of oral treatment with this retinoid (Fig. 1B). The low CD4/CD8 ratio

(0.7) observed in the peripheral blood of the patient before the onset of isotretinoin administration was found to remain unchanged upon completion of retinoid therapy. Apart from a marked cheilitis, the patient developed no significant clinical or laboratory retinoid-related side-effects. He has completed a 24-month follow-up without treatment with oral isotretinoin and shows no evidence of relapse of his skin lesions. Additionally, 10 months after completion of his maintenance rituximab therapy, he remains free of any recurrence of his lymphoma. The counts in his peripheral blood are normalized and the bone marrow infiltration by CD20+ B-lymphocytes has regressed to 10%. Flow cytometry of bone marrow lymphocytic populations revealed only 4% anti-CD20+ B-lymphocytes, whereas no CD20+ B-lymphocytes could be detected in the peripheral blood.

DISCUSSION

Rituximab is a chimeric human-murine IgG₁ monoclonal antibody binding specifically to the B-cell surface antigen CD20 that is expressed in 95% of B-cell lymphomas and causes the eradication of the targeted CD20-positive lymphoma cells through the induction of complement-mediated and CD20-dependent cytotoxic effects and apoptosis (3). Recent clinical trials have demonstrated the efficacy of rituximab, administered as a first-line single agent, in the treatment of low-grade B-cell lymphoma with objective response ranging between 60% and 75% (4, 5). Considering the promotion of B-cell maturation caused by isotretinoin in patients with common variable immunodeficiency (6) and the synergistic action of retinoid and rituximab on apoptosis induction of malignant B cells (7), it seems reasonable to suggest that isotretinoin may have enhanced the therapeutic effects of the latter on the lymphoma of our patient.

In view of the reported encouraging therapeutic results of oral retinoids in patients with extensive viral warts (8, 9), we tried this at a dose of 1 mg/kg/day. The response of his skin lesions was impressive. To the best of our knowledge, it is the first time that oral retinoid therapy has led to the complete remission of extensive viral warts. Under oral administration of either etretinate or isotretinoin, a rapid favourable therapeutic response of the warts was observed but no complete remission was achieved, probably due to early dose reduction (8, 10) or discontinuation of therapy because of the development of liposarcoma (9). In contrast to the relapse of viral warts observed in patients with epidermodysplasia verruciformis subsequent to discontinuation of etretinate treatment (11), our patient has completed a 24-month follow-up without any evidence of recurrence of his cutaneous lesions.

Isotretinoin is capable of dramatically affecting epithelial cell differentiation and proliferation (12). As HPV replication is related to the state of keratinocyte differentiation, it is possible that this retinoid may have inhibited the replication and assembly of HPV (13).

Although a spontaneous regression of the warts cannot be ruled out (14), it seems very unlikely in our patient in view of the extremely long duration of the recalcitrant skin lesions. The question as to whether rituximab (15) may have enhanced the therapeutic action of isotretinoin on the extensive viral warts remains to be elucidated.

REFERENCES

- Guma J, Rubio J, Masip C, Alvaro T, Borrás JL. Aggressive bowel lymphoma in a patient with intestinal lymphangiectasia and widespread viral warts. *Ann Oncol* 1998; 9: 1355–1356.
- Egawa K, Ono T. Topical vitamin D3 derivatives for recalcitrant warts in three immunocompromised patients. *Br J Dermatol* 2004; 150: 374–376.
- Gopal AK, Press OW. Clinical applications of anti-CD20 antibodies. *J Lab Clin Med* 1999; 134: 445–450.
- Dillman RO. Treatment of low-grade B-cell lymphoma with the monoclonal antibody rituximab. *Semin Oncol* 2003; 30: 434–447.
- Hainsworth JD, Litchy S, Barton JH, Houston GA, Hermann RC, Bradof JE, et al. Single-agent rituximab as first-line and maintenance treatment for patients with chronic lymphocytic leukemia or small lymphocytic lymphoma. *J Clin Oncol* 2003; 21: 1746–1751.
- Saxon A, Keld B, Braun J, Dotson A, Sidell N. Long-term administration of 13-cis retinoic acid in common variable immunodeficiency. *Immunology* 1993; 80: 477–487.
- Shan D, Gopal AK, Press OW. Synergistic effects of the fenretinide (4-HPR) and anti-CD20 monoclonal antibodies on apoptosis induction of malignant human B cells. *Chem Cancer Res* 2001; 7: 2490–2495.
- Boyle J, Dick DC, Mackie RM. Treatment of extensive virus warts with etretinate (Tigason) in a patient with sarcoidosis. *Clin Exp Dermatol* 1983; 8: 33–36.
- Gross G, Pfister H, Hagedorn M, Stahn R. Effect of aromatic retinoid (Ro 10-9359) on human papilloma virus-2-induced common warts. *Dermatologica* 1983; 166: 48–53.
- Katz RA. Isotretinoin treatment of recalcitrant warts in an immuno-suppressed man. *Arch Dermatol* 1986; 122: 19–20.
- Jablonska S, Obalek S, Wolska H. Ro 10-9359 in epidermodysplasia verruciformis. Preliminary report. In: Orfanos CE, et al., editor, *Retinoids, advances in basic research and therapy*. New York: Springer Verlag, 1981: 401–405.
- Tsamboas D, Zimmermann B. Effects of synthetic retinoids on cellular systems. In: Roenigk HJ, Maibach HI, eds. *Psoriasis*, 2nd edn. New York: Marcel Dekker, 1991: 659–707.
- Lutzner MA, Blanchet-Bardon C, Puissant A. Oral aromatic retinoid (Ro 10-9359) treatment of two patients suffering with the severe form of epidermodysplasia verruciformis. In: Orfanos CE, et al., editor, *Retinoids: advances in basic research and therapy*. New York: Springer Verlag, 1981: 407–410.
- Dave R, Monk B, Mahaffey P. Spontaneous disappearance of refractory viral warts at distant sites following carbon dioxide laser treatment. *Br J Plastic Surg* 2002; 55: 696–698.
- Khouri IF, Lee M-S, Saliba RM, Andersson B, Anderlini P, Couriel D, et al. Non ablative allogeneic stem cell transplantation for chronic lymphocytic leukemia: impact of rituximab on immunomodulation and survival. *Exp Hematol* 2004; 32: 28–35.