

Lansoprazole-induced Subacute Cutaneous Lupus Erythematosus: Two Cases

Annick Bracke¹, Tamar Nijsten¹, Johan Vandermaesen², Lieve Meuleman¹ and Julien Lambert¹

¹Departments of Dermatology, University Hospital Antwerp, Wilrijkstraat 10, BE-2650 Edegem and ²St Franciskus Hospital, Heusden-Zolder, Belgium. E-mail: Julien.Lambert@uza.be
Accepted October 25, 2004.

Sir,

Subacute cutaneous lupus erythematosus (SCLE) is a well defined subtype of LE, characterized by annular and/or psoriasiform lesions, limited systemic involvement and presence of circulating SSA/anti-Ro antibodies (1). In contrast to drug-induced systemic LE, the association between drugs and SCLE is not well documented (2). Several cases of SCLE have been reported to occur with thiazides, ACE inhibitors, calcium channel blockers, statins, antimycotics, phenytoin and non-steroidal anti-inflammatory drugs (2–5). Lansoprazole is a potent proton pump inhibitor which is widely used in the treatment of gastroduodenal ulcers (6, 7). Although the incidence of lansoprazole-induced cutaneous drug reactions is low (<2%), maculopapular rashes, urticaria and pruritus have been reported (6, 7). Incidental reports suggest the association between use of proton pump inhibitors and other cutaneous drug reactions (8, 9). To our knowledge, we here report the first cases of lansoprazole-induced SCLE.

CASE REPORTS

Case 1. A 69-year-old Caucasian woman presented a 2-week history of multiple itchy skin lesions in a light-exposed distribution. Oral prednisolone (32 mg/day) for 1 month and hydroxyzine for 2 months had no effect. For more than 5 years she used theophylline, salmeterol, fenoterol and beclomethasone dipropionate for asthma and guanfacinum to treat hypertension. She had commenced on lansoprazole for a gastric ulcer 3 months before her skin lesions appeared.

Physical examination showed multiple, scaly, erythematous, annular plaques (Fig. 1). The eruption was diffusely distributed on her trunk, extremities, face and neck, but was most prominent on light-exposed areas.

Fig. 2 shows the histopathological examination of a skin biopsy specimen from lesional skin. Immunofluorescence (IF) was weakly positive for C3 and C1q and negative for IgA, IgG, IgM and fibrinogen.

Total blood count and biochemistry were within normal limits, except for an elevated erythrocyte sedimentation rate (29 mm/h). Antinuclear antibodies (ANA) were detected at a titre of 1/80 with a speckled pattern. Differentiation revealed SSA/anti-Ro antibodies. Anti-histone antibodies were absent.

Topical steroid and hydroxychloroquine 400 mg daily for 10 weeks did not improve her condition. After stopping lansoprazole, the eruption cleared completely within 3 weeks. For more than 3 years, no recurrence of the lesions was noted. The SSA/anti-Ro antibodies disappeared 12 months after the discontinuation of lansoprazole.

Case 2. A 63-year-old woman presented with a skin eruption, which had developed 2 months earlier. For 6 years she used

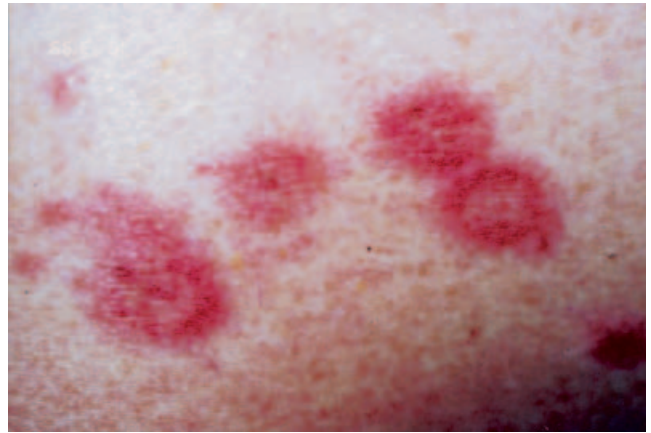

Fig. 1. Multiple, slightly scaling, erythematous, annular plaques in a photosensitive distribution on the trunk, the extremities, face and neck of case 1.

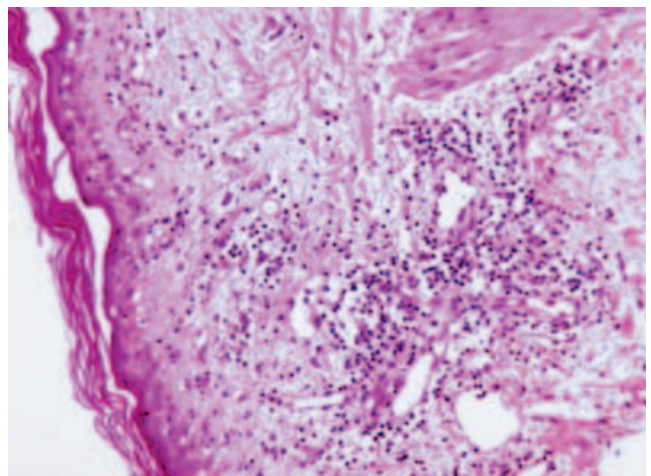


Fig. 2. Histopathology of a skin biopsy specimen (case 1). The epidermis shows multiple necrotic keratinocytes, a slight exocytosis and a vacuolar degeneration of the basal layer. A dense superficial perivascular lymphocytic infiltrate and several eosinophils are noted in the dermis.

oestrogens for postmenopausal symptoms and for 5 months lansoprazole for the treatment of a gastric ulcer.

Skin examination showed numerous, erythematous, round lesions with a raised scaly border and central clearing. The lesions were located on the trunk and extremities.

Histological examination of a skin biopsy specimen demonstrated an atrophic epidermis with vacuolar degeneration of the basal layer and some necrotic keratinocytes. A superficial perivascular lymphohistiocytic infiltrate, including several eosinophils, was noted.

Total blood count and blood biochemistry were within normal limits. Immunological analysis detected ANA with a speckled pattern (titre of 1/640), SSA/anti-Ro antibodies and rheumatoid factor.

Discontinuation of lansoprazole resulted in a complete clearance of the skin lesions within a month. During a follow-up period of 5 years, no recurrence of the skin lesions was reported.

DISCUSSION

The incidence of drug-induced SCLE may be higher than expected (2, 3). This report suggests that proton pump inhibitors may induce SCLE. Although no re-introduction tests were performed, we argue that these cases present lansoprazole-induced SCLE, because of (a) the temporal interval between the use of drug and onset of disease (> 1 month); (b) the complete clearance of the characteristic skin lesions shortly after discontinuation of lansoprazole; and (c) the disappearance in at least one patient of the SSA/anti-Ro antibody testing after discontinuation of lansoprazole (3).

There are no diagnostic criteria for drug-induced SCLE. Clinically, drug induced and idiopathic SCLE can not be differentiated. Also, histopathological findings are similar in both groups of SCLE, except perhaps for an increased tissue eosinophilia in the drug-induced group (5). Crowson & Magro suggested that drug-induced SCLE is associated with vascular staining on IF (5). In contrast to drug-induced SCLE, there are criteria for drug-induced systemic LE: (a) continuous treatment with a suspected drug for at least 1 month; (b) common presenting symptoms; (c) anti-histone antibodies and (d) symptom improvement after discontinuation of the suspected drug (10). If anti-histone antibodies were substituted by SSA/anti-Ro and/or SSB/anti-La antibodies, these criteria may be applicable for drug-induced SCLE as well (1, 10). However, caution is needed because the specificity of SSA/anti-Ro and/or SSB/anti-La antibodies for SCLE is lower than the specificity of anti-histone antibodies for drug-induced systemic LE. In contrast to low-titre ANA, SSA/anti-Ro antibodies are rarely detected in healthy elderly women and are mostly associated with SCLE, LE or Sjögren's syndrome (5, 11).

The use of other drugs that could possibly be associated with SCLE was excluded in these patients. To our knowledge, no cases of SCLE induced by β -2 stimulating drugs have been reported. Also, we continued this therapy and the patient inhaled these drugs for more than 5 years. The levels of the inhaled β -2 stimulating drugs are not significantly increased by lansoprazole drug-drug interactions (12).

Oestrogens are capable of enhancing cell surface expression of SS-A/Ro-antigens (13). Therefore, it is possible that the second patient was at a higher risk

for developing SCLE. However, hormone replacement therapy was continued without relapse.

The mechanisms for autoantibody induction by LE-inducing drugs are not clear yet (10, 14). It has been postulated that drugs and/or their metabolites shift the SSA/Ro-antigens from the nucleus to the cell surface, as has been observed after UV exposure, viral illness, oestrogen use and alterations in the cytosolic calcium milieu (5). Genetics may also be of importance, because both idiopathic and drug-induced SCLE are correlated with HLA-DR3 and -DR2 phenotype (1).

REFERENCES

- Chlebus E, Wolska H, Blaszczyk M, Jablonska S. Subacute cutaneous lupus erythematosus versus systemic lupus erythematosus: diagnostic criteria and therapeutic implications. *J Am Acad Dermatol* 1998; 38: 405-412.
- Callen JP. Drug-induced cutaneous lupus erythematosus, a distinct syndrome that is frequently unrecognized. *J Am Acad Dermatol* 2001; 45: 315-316.
- Srivastava M, Rencic A, Diglio G, Santana H, Bonitz P, Watson R, et al. Drug-induced, Ro/SSA-positive cutaneous lupus erythematosus. *Arch Dermatol* 2003; 139: 45-49.
- Ross S, Ormerod AD, Roberts C, Dwyer C, Herriot R. Subacute cutaneous lupus erythematosus associated with phenytoin. *Clin Exp Dermatol* 2002; 27: 474-476.
- Crowson AN, Magro CM. The cutaneous pathology of lupus erythematosus: a review. *J Cutan Pathol* 2001; 28: 1-23.
- Colin-Jones DG. Safety of lansoprazole. *Aliment Pharmacol Ther* 1993; 7 (Suppl 1): 56-60.
- Martin RM, Dunn NR, Freemantle S, Shakir S. The rates of common adverse events reported during treatment with proton pump inhibitors used in general practice in England: cohort studies. *Br J Clin Pharmacol* 2000; 50: 366-372.
- Odeh M, Lurie M, Oliven A. Cutaneous leucocytoclastic vasculitis associated with omeprazole. *Postgrad Med J* 2002; 78: 114-115.
- Buckley C. Pityriasis rosea-like eruption in a patient receiving omeprazole. *Br J Dermatol* 1996; 135: 660-661.
- Rubin RL. Etiology and mechanisms of drug-induced lupus. *Curr Opin Rheumatol* 1999; 11: 357-363.
- de Vlam K, De Keyser F, Verbruggen G, Vandenbossche M, Vanneuville B, D'Haese D, et al. Detection and identification of antinuclear autoantibodies in the serum of normal blood donors. *Clin Exp Rheumatol* 1993; 11: 393-397.
- Pan WJ, Goldwater DR, Zhang Y, Pilmer BL, Hunt RH. Lack of pharmacokinetic interaction between lansoprazole or pantoprazole and theophylline. *Aliment Pharmacol Ther* 2000; 14: 345-352.
- Sakabe K, Yoshida T, Furuya H, Kayama F, Chan EK. Estrogenic xenobiotics increase expression of SS-A/Ro autoantigens in cultured human epidermal cells. *Acta Derm Venereol* 1998; 78: 420-423.
- Adams LE, Hess EV. Drug-related lupus. Incidence, mechanisms and clinical implications. *Drug Saf* 1991; 6: 431-449.